

Abstract 2 Table 1 ARVC/D phenocopies identified by CMR

Patients	ARVC/D Phenocopies (n = 12, 9.6%)	
	Ischaemic Heart Disease	Non-ischaemic Heart Disease
Patient A	✓	
Patient B		Congenital absence of pericardium
Patient C		Idiopathic dilated cardiomyopathy
Patient D	✓	
Patient E		Left ventricular non-compaction
Patient F		Arrhythmogenic left ventricular cardiomyopathy
Patient G		Anomalous venous return
Patient H	✓	
Patient I	✓	
Patient L		Atrial septal defect
Patient M		Asymmetric pectus excavatum
Patient N	✓	

3 **ROLE OF CARDIAC MAGNETIC RESONANCE IN NON-TRAUMATIC OUT OF HOSPITAL CARDIAC ARREST SURVIVORS: A MULTI-CENTRE STUDY**

^{1,2}A Baritussio, ²M Perazzolo Marra, ¹N Ahmed, ¹A Ghosh Dastidar, ¹J Rodrigues, ²A Zorzi, ²A Susana, ²D Corrado, ¹C Bucciarelli-Ducci. ¹Bristol Heart Institute, Bristol NIHR Cardiovascular Biomedical Research Unit (BRU), Bristol, UK; ²Department of Cardiac, Thoracic and Vascular Sciences, University of Padua, Padua, Italy

10.1136/heartjnl-2015-307845.3

Background Non-traumatic out of hospital cardiac arrest (OHCA) is the leading cause of death in Europe and USA. Acute coronary syndromes represent the most common aetiology and in 2/3 of patients a culprit lesion can be identified on angiogram. Among patients with unobstructed coronaries, the differential diagnosis remains unclear. Cardiovascular Magnetic Resonance (CMR), with its superior tissue characterisation, can establish differential diagnosis over and above echocardiography.

Methods This retrospective observational study was performed in two tertiary centres on consecutive patients surviving OHCA referred for CMR (October 2009–January 2015). Coronary angiography and echocardiography were performed as part of the diagnostic work-up. A comprehensive CMR protocol (cine, late gadolinium enhancement, T2 weighted STIR imaging or adenosine perfusion) was performed within 6 weeks from index event.

Results We identified 140 patients (109 male, age 56.1 ± 15.7 years) surviving OHCA. 134 patients underwent coronary angiography, with evidence of coronary artery disease (CAD) in

71 (53%). Sixty-three (47%) showed unobstructed coronaries. Among patients with CAD, sixty (85%) had ischaemic cardiomyopathy on CMR. Among patients with unobstructed coronaries, CMR identified a normal scan in 17 (27%), ischaemic cardiomyopathy in 9 (14%), non-ischaemic cardiomyopathy in 27 (43%) (Figure 1), and non-specific findings in 10 (16%). Different underlying cardiomyopathies have been identified by CMR among patients with non-ischaemic cardiomyopathy, as shown in Table 1. Overall, the diagnostic pick-up rate of CMR was 91%.

Conclusion Cardiac MRI identified the underlying diagnosis in the large majority of patients, particularly in those with unobstructed coronaries (pick-up rate 84%), leading to a change in management in all. CMR has therefore a promising role in the clinical work-up of patients surviving OHCA.

Abstract 3 Table 1 CMR findings among patients with non-ischaemic cardiomyopathy

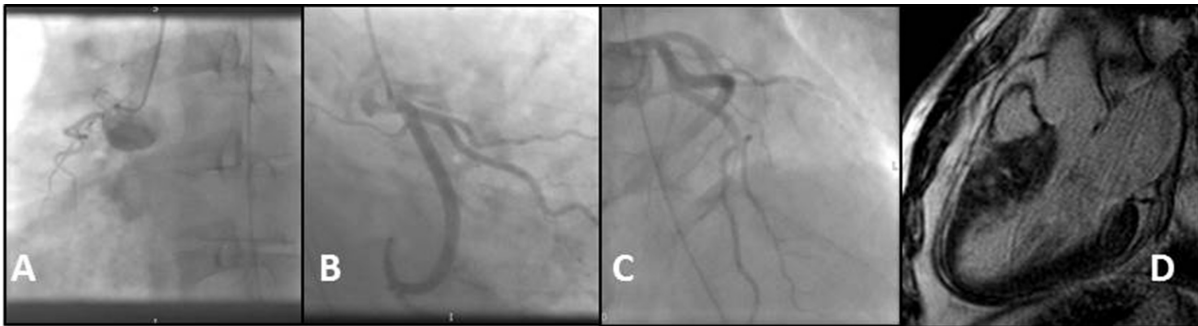
CMR diagnosis	n = 27
Dilated cardiomyopathy	6
Hypertrophic cardiomyopathy	3
Myocarditis	7
Tako-Tsubo cardiomyopathy	2
Mitral valve prolapse	4
Hypertensive heart disease	1
Cardiac amyloid	1
Left ventricular non compaction	1
Biventricular arrhythmogenic cardiomyopathy	1
Heart failure with preserved ejection fraction	1

4 **EXTRACELLULAR VOLUME IN THE INFARCT ZONE IS ASSOCIATED WITH CLINICAL AND MRI MEASURES OF INFARCT SEVERITY IN SURVIVORS OF ACUTE STEMI**

¹J Carberry*, ^{1,2}D Carrick, ³C Haig, ¹SM Rauhalammi, ¹N Ahmed, ^{1,2}I Mordi, ²M McEntegart, ¹M Petrie, ¹H Eteiba, ¹S Hood, ¹S Watkins, ¹M Lindsay, ¹A Davie, ²A Mahrous, ¹A Radjenovic, ³I Ford, ¹KG Oldroyd, ^{1,2}C Berry. ¹BHF Glasgow Cardiovascular Research Center, Institute of Cardiovascular and Medical Sciences, University of Glasgow, Glasgow, UK; ²West of Scotland Heart and Lung Center, Golden Jubilee National Hospital, Dumbartonshire, UK; ³Robertson Center for Biostatistics, University of Glasgow, Glasgow, UK

10.1136/heartjnl-2015-307845.4

Background The clinical significance of extracellular volume (ECV) expansion in infarcted myocardium post-STEMI is unknown. Myocardial ECV can be estimated by cardiac magnetic



Abstract 3 Figure 1 Unobstructed coronaries (A, B, C) in a patient with hypertrophic cardiomyopathy with patchy septal myocardial late enhancement (D).

resonance imaging (CMR) using T1 MOLLI maps before and after contrast. We repeatedly measured infarct ECV in STEMI survivors, and assessed the relationships between ECV, peak troponin T and baseline infarct size.

Methods Acute STEMI survivors were enrolled in a single-centre cohort study (BHF MR-MI study – NCT02072850). Contrast-enhanced CMR was performed at 1.5 Tesla (Siemens MAGNETOM Avanto) 2 days and 6 months post-MI. T1 mapping with MOLLI was performed before and 15 min after contrast (0.15 mmol/kg gadoterate meglumine). ECV analysis was performed by outlining regions of interest (ROIs) in infarcted myocardium and left ventricular (LV) blood pool. ROIs were representative of the infarct including microvascular obstruction. ECV was calculated as the relaxation rate ($R1=1/T1$) for myocardium and LV blood pool before vs. after contrast, corrected for haematocrit. Infarct size was measured using late gadolinium images and expressed as a percentage of LV mass. Infarct ECV at baseline and follow up was compared with peak troponin T measured at presentation and infarct size at baseline. Peak troponin T was log-transformed to improve normality and linearity.

Results 201 STEMI patients (mean age 58 ± 11 years; 156 (77%) male) were enrolled. Infarct ECV was similar at baseline and follow-up ($51.3 \pm 9.5\%$ vs. $50.3 \pm 12.0\%$, $p = 0.097$). Peak troponin T was widely variable ($4256.7 \text{ ug/L} \pm 4020.8 \text{ ug/L}$). Peak troponin T was positively associated with infarct ECV at baseline ($p < 0.001$) and follow-up ($p < 0.001$). Infarct size at baseline was $18 \pm 13\%$ of LV mass and was positively associated with infarct ECV at baseline ($p < 0.001$) and follow-up ($p < 0.001$) (Table 1).

Abstract 4 Table 1 Association of infarct ECV at baseline and follow-up with peak troponin T and infarct size in linear regression analysis (n = 201)

Characteristics	Baseline Infarct ECV			Follow-up Infarct ECV*		
	Coefficient (95% CI)	R ²	p	Coefficient (95% CI)	R ²	p
Log peak troponin T	4.754 (3.473, 6.034)	0.293	<0.001	5.093 (3.688, 6.498)	0.612	<0.001
Infarct size	0.420 (0.307, 0.533)	0.284	<0.001	0.421 (0.298, 0.543)	0.600	<0.001

*Accounting for baseline infarct ECV

Conclusion High peak troponin T and a large infarct size are predictors of higher infarct ECV at baseline and follow-up. Infarct ECV is associated with clinical and MRI measures of MI severity in survivors of STEMI.

5

RELATIONSHIPS BETWEEN INFARCT ZONE EXTRACELLULAR VOLUME AND CLINICAL MEASURES OF ISCHAEMIA AND REPERFUSION IN ACUTE STEMI SURVIVORS

¹J Carberry*, ^{1,2}D Carrick, ³C Haig, ¹SM Rauhalaammi, ¹N Ahmed, ^{1,2}I Mordi, ²M McEntegart, ¹M Petrie, ¹H Eteiba, ¹S Hood, ¹S Watkins, ¹M Lindsay, ¹A Davie, ²A Mahrous, ¹A Radjenovic, ³I Ford, ¹KG Oldroyd, ^{1,2}C Berry. ¹BHF Glasgow Cardiovascular Research Center, Institute of Cardiovascular and Medical Sciences, University of Glasgow, Glasgow, UK; ²West of Scotland Heart and Lung Center, Golden Jubilee National Hospital, Dumbartonshire, UK; ³Robertson Center for Biostatistics, University of Glasgow, Glasgow, UK

10.1136/heartjnl-2015-307845.5

Background The clinical significance of infarct extracellular volume (ECV) post-STEMI is unknown. ECV can be estimated by cardiac magnetic resonance imaging (CMR) using T1 MOLLI maps. We measured infarct ECV in STEMI survivors, and assessed the relationships between ECV and markers of MI severity.

Methods STEMI survivors were enrolled in a single-centre cohort study (BHF MR-MI study – NCT02072850). Culprit artery flow was described by thrombus in myocardial infarction (TIMI) classification. CMR was performed at 1.5 Tesla (Siemens MAGNETOM Avanto) 2-days and 6-months post-MI, including T1-mapping with MOLLI before and 15-minutes after contrast (0.15 mmol/kg gadoterate meglumine). ECV was analysed by outlining regions-of-interest (ROIs) in infarcted myocardium, including microvascular obstruction, and left ventricular (LV) blood pool. ECV was calculated as the relaxation rate ($R1=1/T1$) for myocardium and LV blood pool before vs. after contrast, corrected for haematocrit. ECV was compared with TIMI-flow pre- and post-percutaneous coronary intervention (PCI) and ST-segment resolution. A reduction in ST-segment voltage of $\geq 70\%$ was considered complete ST-resolution and $<70\%$ was considered incomplete ST-resolution.

Results 201 STEMI patients (age 58 ± 11 years; 156 (77%) male) were enrolled. Infarct ECV was similar at baseline and follow-up ($51.3 \pm 9.5\%$ vs. $50.3 \pm 12.0\%$, $p = 0.1$). Pre-PCI, 131 (65%) patients had TIMI-flow 0 and 70 (35%) had TIMI-flow 1–3. Post-PCI, 3 (1.5%) patients had TIMI-flow 0 and 198 (98.5%) had TIMI-flow 2–3. TIMI-flow 0 pre-PCI was associated with higher infarct ECV at baseline ($p < 0.001$) and follow-up ($p = 0.004$). TIMI-flow post-PCI was not associated with infarct ECV. ST-resolution was complete in 104 (52%) patients and incomplete in 96 (48%) patients. Incomplete ST-resolution was associated with higher infarct ECV at baseline ($p = 0.001$) and follow-up ($p = 0.026$) (Table 1).

Conclusion Preserved culprit artery flow and complete ST-resolution are associated with lower infarct ECV at baseline

Abstract 5 Table 1 Association of infarct ECV at baseline and follow-up with TIMI coronary flow grade pre- and post-PCI in linear regression analysis (n = 201)

Characteristics	Baseline Infarct ECV			Follow-up Infarct ECV*		
	Coefficient (95% CI)	R ²	p	Coefficient (95% CI)	R ²	p
TIMI coronary flow grade pre-PCI 1/2/3 vs 0 (ref)	−6.743 (−9.972, −3.514)	0.111	<0.001	−4.834 (−8.092, −1.575)	0.458	0.004
TIMI coronary flow grade post-PCI 2/3 vs 0 (ref)	−5.386 (−16.308, 5.536)	0.007	0.331	1.656 (−8.037, 11.348)	0.450	0.736
ST-segment resolution: complete vs incomplete (ref)	−5.191 (−8.250, −2.133)	0.077	0.001	−3.390 (−6.358, −0.422)	0.488	0.026

*Accounting for baseline infarct ECV