

## INTERVENTIONAL CARDIOLOGY AND SURGERY

# Clinical and angiographic acute and follow up results of intracoronary $\beta$ brachytherapy in saphenous vein bypass grafts: a subgroup analysis of the multicentre European registry of intraluminal coronary $\beta$ brachytherapy (RENO)

T M Schiele, E Regar, S Silber, E Eekhout, D Baumgart, W Wijns, A Colombo, W Rutsch, D Meerkin, A Gershlick, R Bonan, P Urban, for the RENO Investigators

Heart 2003;89:640–644

**Objective:** To assess clinically and angiographically the feasibility, safety, and effectiveness of vascular brachytherapy (VBT) in saphenous vein bypass grafts (SVG).

**Patients and methods:** 67 of 1098 (6.1%) consecutive patients of the European registry of intraluminal coronary  $\beta$  brachytherapy underwent treatment for 68 SVG lesions by VBT using a Sr/ $^{90}$  source train (BetaCath). Clinical follow up data were obtained for all of them after a mean (SD) of 6.3 (2.4) months and angiographic follow up was performed in 61 patients (91.0%) after 6.9 (2.0) months.

**Results:** 58 (86.6%) patients were men, their mean (SD) age was 66 (10) years, 28 (41.8%) had unstable angina, and 21 (31.3%) had diabetes. Fifty three (77.9%) lesions were in-stent restenosis, 13 (19.1%) de novo lesions, and 2 (3.0%) non-stented restenotic lesions. Mean (SD) reference diameter before the intervention was 4.19 (0.52) mm, mean (SD) lesion length was 23.56 (20.38) mm, and mean (SD) minimum lumen diameter measured 0.73 (0.62) mm. Mean (SD) acute gain was 3.02 (0.88) mm. The prescribed radiation dose was 20.1 (3.2) Gy. Pullback manoeuvres were performed in 17 (25.0%) of cases. Most patients received combined aspirin and thienopyridin treatment for 6 or 12 months after the procedure. Technical success was obtained in 62 (91.2%) treated lesions and in-hospital major adverse cardiac events occurred in 4.5%. At follow up, mean (SD) reference diameter was 4.20 (0.53) mm, minimum lumen diameter 2.94 (1.50) mm, and late loss 0.86 (1.25) mm. The overall major adverse cardiac events rate was 26.7%.

**Conclusion:** VBT of SVG is feasible and safe. At follow up the reintervention rate and cardiac morbidity and mortality seem to be favourable, considering that interventions in SVG usually are associated with the highest risks.

Correspondence to:  
Dr T M Schiele, Cardiology  
Department, Medizinische  
Klinik – Innenstadt,  
University Hospital,  
Ziemssenstrasse 1, 80336  
Munich, Germany;  
Thomas.Schiele@  
medinn.med.uni-muenchen.de

Accepted  
27 January 2003

The treatment of patients with obstructive disease of coronary artery bypass grafts (CABG) is challenging. Within a decade after surgery, half of all saphenous vein bypass grafts (SVG) have severe atherosclerotic disease.<sup>1–4</sup> Management of graft disease is problematic, since repeated surgery entails substantial risk.<sup>5–6</sup> The results of angioplasty have been disappointing.<sup>7–10</sup> Angioplasty of vein grafts is associated with increased rates of procedural complications and restenosis.<sup>11–12</sup> Stent implantation has been proved to be superior to balloon angioplasty alone.<sup>13–14</sup> Yet the recurrence rate after stenting still reaches 50%.<sup>15</sup> Treatment of in-stent restenosis is limited by repeat recurrence rates of 40–60% regardless of the angioplasty modality used.<sup>16–17</sup>

Vascular brachytherapy (VBT), using either  $\gamma$  or  $\beta$  radiation sources, has been associated with a very significant impact on the restenosis process. Five randomised trials have shown that both  $\gamma$  and  $\beta$  VBT are associated with a significant decrease in angiographic restenosis and need for target vessel revascularisation in in-stent restenotic lesions.<sup>18–22</sup> For de novo lesions, results have been less conclusive. Excellent results were obtained in one uncontrolled dose finding trial<sup>23</sup> when a high dose of  $\beta$  brachytherapy was given following balloon angioplasty without stent implantation, but a larger randomised controlled evaluation<sup>24</sup> suggested that the angiographic and clinical benefit of VBT was only small following balloon angioplasty alone and was non-existent when a stent was implanted at the time of VBT.

For the treatment of SVG lesions only very limited data exist. In the majority of randomised trials SVG lesions were excluded. In both the  $\gamma$ -WRIST (Washington radiation for in-stent restenosis trial) and SCRIPPS-I (Scripps coronary radiation to inhibit proliferation poststenting) trials the prevalence of interventions in SVG was 23%. No subgroup analyses have been performed. The only randomised trial on VBT in SVG used  $\gamma$  radiation for the treatment of in-stent restenosis and showed reduction of restenosis rate and need for repeat revascularisation of 50%.<sup>17</sup>

To investigate the potential benefit of  $\beta$  radiation in SVG, we conducted a retrospective subgroup analysis from clinical data that had been collected in the European registry of intraluminal coronary  $\beta$  brachytherapy (RENO). Since follow up angiography was not mandatory in this registry, quantitative angiographic analysis was performed retrospectively from available data.

**Abbreviations:** CABG, coronary artery bypass grafting;  $\gamma$ -WRIST, Washington radiation for in-stent restenosis trial; MACE, major adverse cardiac event; RENO, European registry of intraluminal coronary  $\beta$  brachytherapy; SCRIPPS-I, Scripps coronary radiation to inhibit proliferation poststenting; SVG, saphenous vein bypass grafts; VBT, vascular brachytherapy

## PATIENTS AND METHODS

### Population and data collection

Sixty seven of 1098 (6.1%) consecutive patients in the RENO trial underwent angioplasty and VBT of SVG lesions. Data were prospectively collected. All serious adverse events were requested to be reported by fax within 48 hours of their occurrence. Centres obtained institutional review board or ethics committee approval, as well as signed informed consent from the patients. Baseline clinical characteristics, indication for VBT, type of percutaneous intervention and VBT performed, in-hospital events, and six month follow up data were recorded. Index and follow up coronary angiograms, if available, were collected, and quantitative coronary angiography analysis was performed using a validated system (CAAS II, Pie Medical, Maastricht, Netherlands).

### Definitions

Technical success was considered to have been achieved when at least 90% of the planned dose of radiation had been delivered to the target coronary segment and the final residual stenosis was no greater than 50%. Acute myocardial infarction was defined as an increase in plasma creatine kinase concentration above twice the upper limit of normal, new Q waves on the ECG, or both. The infarction was considered to be related to the VBT procedure if it occurred in the territory of a treated coronary artery or if its location could not be determined. Deaths were classified as cardiac or non-cardiac, and cardiac death was further defined as sudden (within 24 hours of acute symptoms onset) or non-sudden. Deaths of undetermined cause were deemed to have been cardiac.

A major adverse cardiac event (MACE) was considered to have occurred if one or several of the following were documented: death, myocardial infarction, or target vessel revascularisation. Angiographic restenosis was considered present when a 50% or greater diameter stenosis in the target vessel was present.

### VBT procedure

A femoral access was used in all cases. The angioplasty procedure was performed according to the operator's discretion. A satisfactory initial acute result was a prerequisite for subsequent VBT, but stents could be implanted either before or after irradiation. VBT was carried out using a monorail-type 5 French delivery catheter (Novoste, Norcross, Georgia, USA) to deliver hydraulically a source train of Sr<sup>90</sup> seeds 30, 40 or 60 mm in length. The recommended dose, prescribed at 2 mm from the longitudinal axis of the source train, varied between 16.1–23.0 Gy for patients without, and between 18.4–25.3 Gy for patients with, a previously implanted stent according to the reference diameter. The nominal diameter of the largest angioplasty balloon used before VBT was taken as the reference diameter. The 40 mm and 60 mm source trains became available only during patient recruitment, and several centres occasionally resorted to a "pullback" manoeuvre (positioning of the delivery catheter twice over adjacent segments of the injured segment of the target vessel). Following the procedure, patients were treated with aspirin together with either clopidogrel 75 mg daily or ticlopidine 250 mg twice daily. On the basis of the available information at the time of protocol design, a minimum of 90 days of combined antiplatelet treatment was recommended, but each investigator was free to prolong this if it was thought necessary.

### Quantitative coronary angiography

Quantitative coronary analysis was performed off line using the CAAS II system. Measurements were carried out before the intervention, after the very last step of the index procedure, and at follow up. The minimal lumen diameter was determined by edge detection and the reference diameter was automatically calculated by the interpolated method. The per-

**Table 1** Baseline clinical and angiographic characteristics

Number of patients	67
Number of lesions	68
Mean (SD) age (years)	66 (10)
Male sex	58 (86.6%)
Diabetes	21 (31.3%)
Hypertension	45 (67.2%)
Hyperlipidaemia	53 (79.1%)
Smoking	7 (10.4%)
Unstable angina	28 (41.8%)
Prior acute myocardial infarction	21 (31.3%)
Type of lesion*	
In-stent restenosis	53 (77.9%)
De novo stenosis	13 (19.1%)
Non-stented restenosis	2 (3.0%)
Target lesion location*	
SVG on the obtuse marginal branch	37 (54.4%)
SVG on the left anterior descending coronary artery	14 (20.6%)
SVG on the right coronary artery	11 (16.2%)
SVG on the diagonal branch	6 (8.8%)
Lesion position in SVG*	
Body	41 (60.3%)
Ostium	21 (30.9%)
Distal anastomosis	6 (8.8%)

\*Results per lesion. SVG, saphenous vein graft.

centage diameter stenosis was calculated from the minimal lumen diameter and the reference diameter.

### Statistical methods

Calculations were performed using a dedicated software package (SPSS 10.0.7, SPSS Inc, Chicago, Illinois, USA). Categorical data are presented as absolute and relative frequencies. For continuous variables, arithmetic means (SD) are given as summary measures. Continuous variables were compared using unpaired Student's *t* test. A probability value of *p* < 0.05 was considered significant.

## RESULTS

### Baseline demographic and angiographic characteristics

Table 1 shows the baseline characteristics. Most patients were male and exhibited a typical prevalence of cardiovascular risk factors. Of note, the percentage of patients with unstable angina pectoris was comparably high. The most frequent indication for VBT was in-stent restenosis. Roughly half of the procedures were performed in the SVG supplying the obtuse marginal branch of the left circumflex coronary artery. Most of the lesions were confined to the graft's body but ostial interventions were also very common.

### Angioplasty and VBT

Table 2 lists the procedure related parameters. Debulking techniques before balloon angioplasty and VBT were not used at all. The cutting balloon was used in only a minority of cases. Most of the procedures did not include the implantation of a new stent. Because of insufficient back up of the guiding catheter preventing passage of the radiation delivery catheter the overall primary success rate was only 91.2%.

### Quantitative coronary angiography

Table 3 gives the quantitative coronary angiography data. Follow up angiography was performed after a mean (SD) of 6.9 (2.0) months. Of note, the lesion length was above average. Because of the large reference lumen diameter, acute lumen gain approximated 3 mm. A significantly larger mean acute gain in luminal diameter was achieved when de novo lesions were treated. Because of an additional trend for lower late loss, the minimum lumen diameter at follow up was significantly higher in de novo lesions than in in-stent restenosis.

### Clinical follow up

In-hospital and six month clinical follow up data were obtained for all patients after a mean (SD) of 6.3 (2.4) months. During the hospital stay none of the patients suffered an acute myocardial infarction or cardiac death. One of the patients required catheter based reintervention because of a thrombotic reocclusion of a severely degenerated SVG, which had been treated with stent implantation for a de novo lesion. Clopidogrel had not been discontinued. Two patients died of non-cardiac causes (pneumonia of intracerebral bleeding). The overall in-hospital MACE rate was 4.5%.

At six months' follow up one of the patients had a non-Q wave acute myocardial infarction. Another patient had a Q wave acute myocardial infarction requiring reintervention and leading to cardiac death. Cardiac death occurred in another two patients. One was sudden in nature and was caused by ventricular fibrillation during a dental procedure. The other one was caused by protracted intrathoracic bleeding after semi-elective CABG. Five patients died of non-cardiac causes (two pneumonia, one adult respiratory distress syndrome, one septic shock, and one intestinal ischaemia). The angiographic restenosis rate was 18.6% and the target vessel revascularisation rate was 16.4% (13.4% percutaneous transluminal coronary angioplasty, 3.0% CABG). The overall MACE rate was 26.9%.

### DISCUSSION

Recurrent myocardial ischaemia after CABG is a common clinical problem. Angiographic studies have found that within 10 years after the operation, half of all vein grafts are totally occluded or have severe atherosclerotic disease.<sup>1-4</sup> Repeated bypass surgery is more technically challenging than a first operation, is associated with higher morbidity and mortality, and provides less symptomatic relief.<sup>5-6</sup> Angioplasty is therefore often attempted. However, the results of balloon angioplasty in SVG are less favourable than those in native vessels regarding complication and restenosis rates.<sup>7-8 11 12</sup> Stent implantation has been shown to be superior to balloon angioplasty in observational as well as in randomised trials.<sup>13 14</sup> Despite these encouraging findings the absolute restenosis rate after PTCA of SVG is still high and subsequent clinical sequelae are meaningful.<sup>15</sup> Interventional treatment of in-stent restenotic lesions is associated with a repeat recurrence rate of 50% regardless of the technique performed.<sup>16 17</sup> Thus, it seemed reasonable to attempt to reduce the incidence of restenosis, either prophylactically by combin-

ing the primary intervention of a de novo lesion with VBT or as an adjunctive treatment modality.

While VBT in native coronary arteries is now very solidly documented in five randomised trials,<sup>18-22</sup> only one randomised trial for the treatment of SVG disease exists.<sup>17</sup> Gamma radiation was applied to in-stent restenotic lesions exclusively. A very prominent reduction of restenosis rate (iridium-192 15%, placebo 43%,  $p = 0.004$ ) and of the composite end point of death, Q wave myocardial infarction, and target vessel revascularisation (iridium-192 32%, placebo 63%, odds ratio 0.27, 95% confidence interval 0.13 to 0.57,  $p < 0.001$ ) has been shown. Considering the complexity of the treated lesions, it was concluded that VBT is of special value for patient subsets at high risk for recurrent events. The present data from the RENO registry reflect a subgroup of patients having undergone  $\beta$  irradiation in SVG during routine clinical practice. The high rates of six month clinical and angiographic follow up that were achieved (100% and 91%, respectively) give particular strength to the observations that can be made.

Performing VBT in SVG lesions is feasible and safe. Nevertheless, the primary success rate was comparably low. This was because of insufficient back up of the guiding catheter to allow passage of the relatively stiff 5 French radiation delivery catheter to the target lesion. More flexible delivery catheters with a lower profile may be preferable for VBT in SVG.

In-hospital complications were infrequent (4.5%), and comparable with other series of coronary interventions in SVG.<sup>11 12</sup> This seems to be favourable, since interventions in SVG lesions usually are associated with the highest risk and the prevalence of patients with unstable angina and ostial lesion location, as well as lesion length, was above average.

The six month MACE rate of 26.7% observed in the present registry compares with those reported in the radiotherapy arm of the available trials,<sup>17-22</sup> where the MACE rate varied between 18-29% for patients treated for in-stent restenosis and between 14-19% for de novo lesions. Of note, 7.5% of the overall MACE rate was caused by non-cardiac deaths. These deaths were not procedure related and reflect the high level of morbidity of the study population. Yet, in light of the limited sample size, the number should be regarded with caution. The need for target vessel revascularisation was 16.4% in this registry, while it was 11-34% in previously conducted studies. This seems to be especially favourable, for several reasons. Firstly, the absolute rate of reinterventions is at the lower end of the results reported in previous trials. Secondly, the

**Table 3** Results of quantitative coronary angiography

	Overall (n=67)	In-stent restenosis (n=46)	De novo/restenosis (n=21)	p Value
Lesion length (mm)	23.56 (20.38)	26.13 (22.93)	17.94 (11.77)	0.058
Pre-intervention				
Reference lumen diameter (mm)	4.19 (0.52)	4.22 (0.52)	4.15 (0.54)	0.626
Minimum lumen diameter (mm)	0.73 (0.62)	0.75 (0.61)	0.69 (0.67)	0.738
Diameter stenosis (%)	82 (15)	82 (15)	84 (15)	0.617
Postintervention				
Reference lumen diameter (mm)	4.21 (0.53)	4.23 (0.53)	4.15 (0.54)	0.560
Minimum lumen diameter (mm)	3.77 (0.69)	3.64 (0.68)	4.05 (0.65)	0.023
Diameter stenosis (%)	11 (11)	14 (11)	3 (7)	<0.001
At follow up				
Reference lumen diameter (mm)	4.20 (0.53)	4.23 (0.55)	4.13 (0.51)	0.510
Minimum lumen diameter (mm)	2.94 (1.50)	2.69 (1.42)	3.53 (1.56)	0.049
Diameter stenosis (%)	31 (34)	37 (32)	18 (34)	0.047
Binary restenosis (%)	18.6	21.4	11.8	0.388
Change in minimum lumen diameter				
Acute gain (mm)	3.02 (0.88)	2.87 (0.90)	3.35 (0.77)	0.038
Late loss (mm)	0.86 (1.25)	1.02 (1.27)	0.48 (1.14)	0.128
Net gain (mm)	2.15 (1.54)	1.95 (1.55)	2.64 (1.45)	0.094

Data are mean (SD).



incidence of reintervention in a high risk patient subset reported in this trial is essentially the same as in a population at average risk. It should also be stressed that several exclusion criteria often used in randomised trials did not apply in this registry. Although the protocol initially discouraged the irradiation of lesions longer than 30 mm, this was nevertheless done for 21 lesions (30.9%) and a pullback manoeuvre was used for 17 (25.0%).

Several points demand special attention. Usually, the implantation of a new stent in conjunction with VBT is associated with an increased risk for late thrombosis and eventual late thrombotic occlusion, as well as an increased likelihood of target vessel revascularisation caused by geographic miss and consecutive edge effect.<sup>20 24–26</sup> In the population studied, no such observation could be made. De novo lesions, although of smaller length, exhibited a larger acute gain, a smaller late loss, and neither total occlusion nor an edge effect. Thus, stent implantation for de novo lesions in SVG may not necessarily be attributable to a higher rate of repeat reinterventions or MACE. Yet, to draw any valid conclusions, larger sample sizes are imperative.

### Limitations

Although the results of the present series are very encouraging, they suffer from the limitations of all registries. They cannot be seen as direct evidence of the efficacy of VBT, especially in a heterogeneous population. The sample size was small, limiting conclusions concerning clinical end points.

Angiographic follow up was not mandatory, resulting in an incomplete data set. Nevertheless, the actual angiographic follow up rate was high and not only driven by clinical need but more often based on a compassionate manner. Quantitative coronary angiography was performed retrospectively. Thus, angiography was performed in a non-standardised manner resulting in potential errors in determining true vessel dimensions. Since SVG, in contrast to native coronary arteries, are of greater diameter and do not pose the problem of overlay with other vessels, sources of error are likely to be acceptable.

It is important to emphasise limitations resulting from the open nature of this trial, since patients and operators were not blinded to the treatment. Thus, the possibility of bias cannot be excluded despite the prospective design of the registry.

### Conclusions

Adjunct VBT with  $\beta$  radiation for de novo and in-stent restenotic lesions in SVG is feasible and can be safely performed. At six months' follow up, the restenosis rate compares very favourably with previously reported data acquired in populations with a much lower likelihood of recurrence, and MACE rates are similar to those obtained in the VBT arms of published randomised controlled trials. Thus,  $\beta$  VBT might be of special value for high risk patient subsets. It would be desirable to confirm the results in a randomised controlled trial.

### ACKNOWLEDGEMENTS

**Steering Committee:** D Baumgart, R Bonan, A Gershlick, P Urban (Chair), A Zeiher.

**Database management and statistical analysis:** Wegscheider Biometrie und Statistik GmbH, Berlin, Germany

**Participating centres:** (city, institution, country, names of cardiologist and radiotherapist and number of patients included (in parentheses)).

Rotterdam, Thoraxcenter, the Netherlands: Serruys, Levendag/Coen (10); Munich, Müller, Germany: Silber, von Rottkay (5); Lausanne, CHUV, Switzerland: Eeckhout, Coucke (5); Essen, Universitätsklinikum, Germany: Baumgart, Sauerwein (4); Aalst, OLV, Belgium: Wijns, Verbeke (3); Milan, Columbus, Italy: Colombo, Orecchia (3); Berlin,

Charité Mitte, Germany: Rutsch, Buchali/Matnjani (3); Jerusalem, Shaare Zedek, Israel: Meerkin, Hayne (3); Hamburg, UKE, Germany: Brockhoff, Krüll (3); Antwerp, UZA, Belgium: Vrints, de Bal (2); Mont-Godinne, UCL, Belgium: Gurné, Vandeput (2); Bochum, St Joseph, Germany: Mügge, Kissler (2); Hamburg, St Georg, Germany: Küchler, Ehnert (2); Bad Oeynhausen, Herzzentrum, Germany: Wiemer, Lindner (2); Nijmegen Academisch Ziekenhuis, the Netherlands: Aengevaeren, Pop (2); Glenfield, General Hospital, United Kingdom: Gershlick, Benghiat (2); Kaiserslautern, Westfal-Klinikum, Germany: Glunz, Herbig (1); Munich, Medizinische Klinik-Innenstadt, Germany: Klauss, Pöllinger (1); Aachen, Universitätsklinikum, Germany: vom Dahl, Schubert (1); Arhus, Skejby, Denmark: Thuesen, Overgaard (1); Vienna, AKH, Austria: Glogar, Pötter/Pokrajac (1); Hamburg, Mathey-Schofer, Germany: Schofer, Thelen (1); Bochum, Augusta Krankenhaus, Germany: Altmaier, Dürscheidt (1); Dortmund, St Johannes, Germany: Heuer, Donsbach (1); Ioannina, University, Greece: Michalis, Tsekeris (1); Brussels, St Luc, Belgium: Debbas, Scalliet (1); Eindhoven, Catharina, the Netherlands: Bonnier, Schmeets (1).

**Sponsor:** Novoste Europe SA/NV, Brussels, Belgium.

### Authors' affiliations

**T M Schiele**, Medizinische Klinik—Innenstadt, University Hospital, Munich, Germany  
**E Regar**, Thoraxcenter, Rotterdam, Netherlands  
**S Silber**, Müller-Klinik, Munich, Germany  
**E Eeckhout**, CHUV, Lausanne, Switzerland  
**D Baumgart**, Universitätsklinikum, Essen, Germany  
**W Wijns**, OLV, Aalst, Belgium  
**A Colombo**, EMO Columbus, Milan, Italy  
**W Rutsch**, Charité, Berlin, Germany  
**D Meerkin**, Shaare Zedek, Jerusalem, Israel  
**A Gershlick**, General Hospital, Glenfield, UK  
**R Bonan**, Montreal Heart Institute, Montreal, Canada  
**P Urban**, La Tour Hospital, Geneva, Switzerland

### REFERENCES

- 1 Hamby RI, Aintablian A, Handler M, *et al*. Aortocoronary saphenous vein bypass grafts: long-term patency, morphology and blood flow in patients with patent grafts early after surgery. *Circulation* 1979;**60**:901–9.
- 2 Bourassa MG, Enjalbert M, Campeau L, *et al*. Progression of atherosclerosis in coronary arteries and bypass grafts: ten years later. *Am J Cardiol* 1984;**53**:102C–7C.
- 3 Bourassa MG, Fisher LD, Campeau L, *et al*. Long-term fate of bypass grafts: the coronary artery surgery study (CASS) and Montreal Heart Institute experiences. *Circulation* 1985;**72**(suppl V):V–71.
- 4 Lytle BW, Loop FD, Cosgrove DM, *et al*. Long-term (5 to 12 years) serial studies of internal mammary artery and saphenous vein coronary bypass grafts. *J Thorac Cardiovasc Surg* 1985;**89**:248–58.
- 5 Schaff HV, Orszulak TZ, Gersh BJ, *et al*. The morbidity and mortality of reoperation for coronary artery disease and analysis of late results with use of actuarial estimate of event-free interval. *J Thorac Cardiovasc Surg* 1983;**85**:508–15.
- 6 Cameron A, Kemp HG Jr, Green GE. Reoperation for coronary artery disease: 18 years of clinical follow-up. *Circulation* 1988;**78**(suppl 1):1158.
- 7 Laird-Meeter K, van Domburg R, van den Brand MJ, *et al*. Incidence, risk and outcome of reintervention after aortocoronary bypass surgery. *Br Heart J* 1987;**57**:427–35.
- 8 de Feyter PJ, van Suylen RJ, de Jaegere PPT, *et al*. Balloon angioplasty for the treatment of lesions in saphenous vein bypass grafts. *J Am Coll Cardiol* 1993;**21**:1539–49.
- 9 Holmes DR Jr, Topol EJ, Califf RM, *et al*. A multicenter, randomised trial of coronary angioplasty versus directional atherectomy for patients with saphenous vein bypass graft lesions. CAVEAT-II Investigators. *Circulation* 1995;**91**:1966–74.
- 10 Strauss BH, Natarajan MK, Batchelor WB, *et al*. Early and late quantitative angiographic results of vein graft lesions treated by excimer laser with adjunctive balloon angioplasty. *Circulation* 1995;**92**:348–56.
- 11 Douglas JS Jr, Gruentzig AR, King SB III, *et al*. Percutaneous transluminal coronary angioplasty in patients with prior coronary bypass surgery. *J Am Coll Cardiol* 1983;**2**:745–54.
- 12 Platko WP, Hollman J, Whitlow PL, *et al*. Percutaneous transluminal angioplasty of saphenous vein graft stenosis: long-term follow-up. *J Am Coll Cardiol* 1989;**14**:1645–50.
- 13 Brener SJ, Ellis SG, Apperson-Hansen C, *et al*. Comparison of stenting and balloon angioplasty for narrowings in aortocoronary saphenous vein conduits in place for more than five years. *Am J Cardiol* 1997;**79**:13–8.
- 14 Savage MP, Douglas JS Jr, Fischman DL, *et al*. Stent placement compared with balloon angioplasty for obstructed coronary bypass grafts. Saphenous vein de novo trial investigators. *N Engl J Med* 1997;**337**:740–7.

- 15 **De Scheerder IK**, Strauss BH, de Feyter PJ, *et al*. Stenting of venous bypass grafts: a new treatment modality for patients who are poor candidates for reintervention. *Am Heart J* 1992;**123**:1046–54.
- 16 **Dangas G**, Mehran R, Lansky AJ, *et al*. Acute and long-term results of treatment of diffuse in-stent restenosis in aortocoronary saphenous vein grafts. *Am J Cardiol* 2000;**86**:777–9.
- 17 **Waksman R**, Ajani AE, White RL, *et al*. Intravascular gamma radiation for in-stent restenosis in saphenous-vein bypass grafts. *N Engl J Med* 2002;**346**:1194–9.
- 18 **Teirstein PS**, Massullo V, Jani S, *et al*. Catheter-based radiotherapy to inhibit restenosis after coronary stenting. *N Engl J Med* 1997;**336**:1697–703.
- 19 **Waksman R**, White RL, Chan RC, *et al*, for the Washington radiation for in-stent restenosis trial WRIST investigators. Intracoronary gamma-irradiation therapy after angioplasty inhibits recurrence in pts with in-stent restenosis. *Circulation* 2000;**101**:2165–71.
- 20 **Leon MB**, Teirstein PS, Moses JW, *et al*. Localized intracoronary gamma-radiation therapy to inhibit the recurrence of restenosis after stenting. *N Engl J Med* 2001;**344**:250–6.
- 21 **Raizner AE**, Oesterle SN, Waksman R, *et al*. Inhibition of restenosis with beta-emitting radiotherapy: report of the proliferation reduction with vascular energy trial (PREVENT). *Circulation* 2000;**102**:951–8.
- 22 **Waksman R**, Raizner AE, Yeung AC, *et al*, on behalf of the INHIBIT investigators. Localized intracoronary beta radiation therapy to inhibit recurrence of in-stent restenosis. *Lancet* 2002;**359**:551–7.
- 23 **Verin V**, Popowski Y, de Bruyne B, *et al*, for the Dose-Finding Study Group. Endoluminal beta-radiation therapy for the prevention of coronary restenosis after balloon angioplasty. *N Engl J Med* 2001;**344**:243–9.
- 24 **Kuntz RE**. The beta-cath trial. 50th annual scientific session, American College of Cardiology, Orlando, 2001.
- 25 **Sianos G**, Kay IP, Costa MA, *et al*. Geographical miss during catheter-based intracoronary beta-radiation: incidence and implications in the BRIE study. Beta-radiation in Europe. *J Am Coll Cardiol* 2001;**38**:415–20.
- 26 **Waksman R**, Bhargava B, Mintz GS, *et al*. Late total occlusion after intracoronary brachytherapy for patients with in-stent restenosis. *J Am Coll Cardiol* 2000;**36**:65–8.

## IMAGES IN CARDIOLOGY.....

### Left ventricular microaneurysms as a cause of apparently idiopathic ventricular fibrillation

A 36 year old woman had been involved in a traffic accident because of syncope. A paramedic witnessed the accident by chance. He diagnosed cardiac arrest and started cardiopulmonary resuscitation. ECG recorded by an automatic external defibrillator revealed ventricular fibrillation. Regular sinus rhythm was successfully restored by a single 200 Joule direct current shock (below, ECG at admission). The patient recovered well within one day without any neurological sequelae. She reported a five year history of recurrent episodes of palpitations without previous syncope. ECG evaluation performed by the patients' general practitioner a few years ago revealed multiple ventricular premature beats. No further cardiac evaluation had been performed in the past.

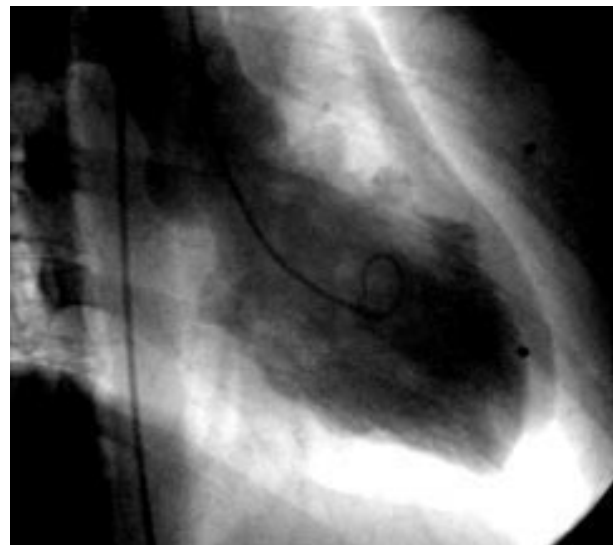
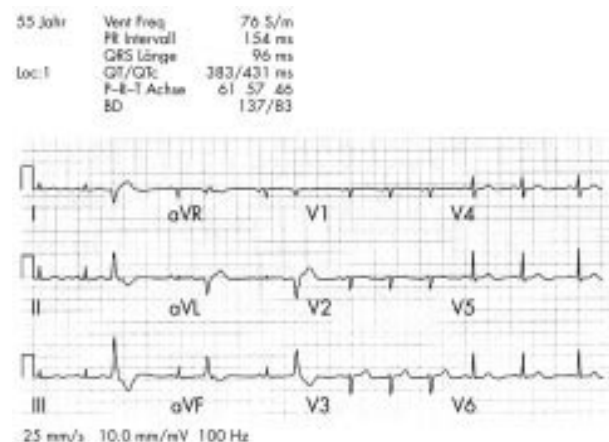
Coronary angiography revealed normal coronary arteries. Right anterior oblique angiographic projection of the left ventricle (right) revealed four left ventricular microaneurysms. The global left ventricular ejection fraction was 72%. Two dimensional echocardiography, performed by an

experienced operator, failed to show abnormalities of cardiac morphology. Implantation of a defibrillator was performed six days following the successful resuscitation.

Severe ventricular arrhythmias may occur in patients with apparently normal hearts and may be associated with inflammatory left ventricular aneurysms of small dimension. Inflammatory left ventricular microaneurysms are often of viral origin (caused by previous myocarditis) and this finding is a consistent cause of the apparently "idiopathic" ventricular fibrillation in this case.

**J Auer**  
**R Berent**  
**B Eber**

johann.auer@khwels.at



**Heart**

# Clinical and angiographic acute and follow up results of intracoronary $\beta$ brachytherapy in saphenous vein bypass grafts: a subgroup analysis of the multicentre European registry of intraluminal coronary $\beta$ brachytherapy (RENO)

T M Schiele, E Regar, S Silber, E Eeckhout, D Baumgart, W Wijns, A Colombo, W Rutsch, D Meerkin, A Gershlick, R Bonan and P Urban

*Heart* 2003 89: 640-644  
doi: 10.1136/heart.89.6.640

---

Updated information and services can be found at:  
<http://heart.bmj.com/content/89/6/640>

*These include:*

**Supplementary Material**

Supplementary material can be found at:  
<http://heart.bmj.com/content/suppl/2003/05/22/89.6.640.DC1>

**References**

This article cites 22 articles, 6 of which you can access for free at:  
<http://heart.bmj.com/content/89/6/640#ref-list-1>

**Email alerting service**

Receive free email alerts when new articles cite this article. Sign up in the box at the top right corner of the online article.

---

**Errata** An erratum has been published regarding this article. Please see [next page](#) or:  
</content/89/7/792.full.pdf>

**Topic Collections**

Articles on similar topics can be found in the following collections

[Clinical diagnostic tests](#) (4778)  
[Epidemiology](#) (3789)  
[Acute coronary syndromes](#) (2742)  
[Diabetes](#) (841)  
[Drugs: cardiovascular system](#) (8839)

---

**Notes**

---

To request permissions go to:  
<http://group.bmj.com/group/rights-licensing/permissions>

To order reprints go to:  
<http://journals.bmj.com/cgi/reprintform>

To subscribe to BMJ go to:  
<http://group.bmj.com/subscribe/>

## SCIENTIFIC LETTER

## Cardiac abnormalities in patients with Leber's hereditary optic neuropathy

P Sorajja, M G Sweeney, R Chalmers, B Sachdev, P Syrris, M Hanna, N D Wood, W J McKenna, P M Elliott

Heart 2003;89:791-792

Leber's hereditary optic neuropathy (LHON) is characterised by acute or subacute central visual loss<sup>1</sup> that typically occurs in early adult life. Three mitochondrial DNA (mtDNA) point mutations, 3460, 11778, and 14484, account for more than 90% of all LHON cases.<sup>2</sup> Cardiac involvement in LHON has been suspected ever since Leber's original 1871 report in which some patients with the disease complained of palpitations. The aim of this study was to determine the prevalence and nature of cardiac abnormalities in patients with LHON by systematically evaluating cardiac structure and function using echocardiography and adenosine testing.

## METHODS

The study population comprised 24 consecutive patients with LHON diagnosed at Queen Square Hospital, London. The diagnosis of LHON was based on characteristic clinical features of the disease and/or the presence of a primary LHON mutation.<sup>3</sup> Cardiovascular examination and investigation were performed at St George's Hospital, London. The investigation was approved by the local research ethics committee. All patients provided written informed consent before participation in the study.

Each patient underwent an initial clinical assessment and 12 lead ECG. ECG evidence of left ventricular hypertrophy was defined in accordance with Romhilt-Estes criteria. Ventricular pre-excitation was defined as a PR interval < 120 ms, QRS duration > 120 ms, and slurred onset of the QRS complex ( $\delta$  wave). Ten patients gave informed written consent to undergo provocation testing with intravenous adenosine. During continuous ECG monitoring of leads II, aVF, V1, V4, V5, and V6, adenosine was administered via the right antecubital vein in 6 mg increments at 2-3 minute intervals. Administration was repeated until atrioventricular block or pre-excitation occurred. Left ventricular hypertrophy was defined as a left ventricular wall thickness of 15 mm or greater on two dimensional echocardiography. The peak instantaneous left ventricular outflow tract gradient was calculated using continuous wave Doppler and modified Bernoulli equation.

## RESULTS

Eleven patients from the same family carried the 3460 mtDNA mutation (table 1). Eight patients, including two siblings, carried the 11778 mtDNA mutation. The remaining five patients,

**Table 1** Clinical characteristics and study results for patients harbouring the 3460, 114480, and 11778 mtDNA mutations

Patient	Age/ sex	MtDNA mutation	Cardiac symptoms	Echocardiography				ECG			
				LA (mm)	EDD (mm)	ESD (mm)	MLVWT (mm)	PAT	TWI	LVH	ST abnl
1	62/F	3460	-	36	46	22	16	ASH	+	+	+
2	53/M	3460	-	42	35	22	28	CON	+	+	+
3	53/M	3460	Syncope, angina, dyspnoea	39	30	19	26	CON	+	+	+
4	58/F	3460	Syncope, angina, dyspnoea, palpitations	38	36	23	15	CON	+	+	+
5	38/M	3460	Dyspnoea, palpitations	25	53	32	17	DIS	+	+	+
6	36/F	3460	-	31	42	24	10	-	+	-	+
7	33/F	3460	-	30	46	30	9	-	-	-	-
8	24/M	3460	-	38	48	29	11	-	-	-	-
9	31/M	3460	-	38	47	39	10	-	-	-	-
10	34/F	3460	-	31	44	29	10	-	-	-	+
11	32/M	3460	-	39	50	32	11	-	-	-	+
12	42/M	11778	Dyspnoea, palpitations	34	48	27	12	-	-	+	+
13	44/M	11778	Post-micturition syncope	27	47	29	11	-	+	+	+
14	54/M	11778	Post-micturition syncope	38	48	30	11	-	-	+	-
15	27/M	11778	-	32	47	29	10	-	-	-	-
16	48/F	11778	Palpitations	21	44	25	10	-	-	-	-
17	57/M	11778	-	36	46	26	10	-	-	-	-
18	42/M	11778	-	34	51	29	10	-	+	-	+
19	32/F	11778	-	30	45	29	9	-	+	-	-
20	51/M	14484	Palpitations	40	59	36	10	-	-	+	+
21	63/M	14484	-	33	46	21	10	-	-	-	-
22	56/M	14484	-	42	45	30	9	-	-	-	-
23	40/M	14484	Nil	37	45	25	12	-	-	-	-
24	67/M	14484	Nil	30	45	26	7	-	-	-	-

ASH, asymmetrical septal hypertrophy; CON, concentric hypertrophy; LVH, left ventricular hypertrophy; DI, distal hypertrophy; EDD, end diastolic diameter; ESD, end systolic diameter; MLVWT, maximal left ventricular wall thickness; LA, left atrium; PAT, pattern of left ventricular hypertrophy; ST abnl, ST segment abnormality; TWI, T wave inversion.



including two siblings, were affected with the 14484 mtDNA mutation.

Three 3460 patients, four 11778 patients, and one 14484 patient had cardiac symptoms. Eight 3460 patients, five 11778 patients, and one 14484 patient had ECG abnormalities. Of the 11 patients with the 3460 mutation, five had myocardial hypertrophy (mean (SD) maximal wall thickness 20 (6) mm, range 16–28 mm). Myocardial hypertrophy was absent in patients with the 11778 and 14484 mutation. Unexplained left ventricular dilatation (end diastolic dimension 59 mm) was seen in one patient with the 14484 mutation. A history of sudden death was recorded in one member (in his 50s) of the family with the 3460 mutation. One patient, with a diagnosis of hypertrophic cardiomyopathy before this study, received a DDD pacemaker for sinus node dysfunction. No patient had evidence of ventricular pre-excitation at rest, or following adenosine provocation. There was no evidence of a skeletal myopathy in any of the patients studied.

## DISCUSSION

To the best of our knowledge, this study is the first report describing hypertrophic cardiomyopathy in patients with LHON. The pattern of cardiac hypertrophy was heterogeneous: three patients had concentric hypertrophy, one had asymmetric septal hypertrophy, and one had distal hypertrophy. Cardiac symptoms and isolated ECG abnormalities were also common, but in contrast to previous studies,<sup>4</sup> we were unable to demonstrate any evidence for ventricular pre-excitation. This may have been because of the small number of patients examined; however, other recent studies have also failed to demonstrate pre-excitation in patients with LHON.<sup>3</sup>

The fact that hypertrophic cardiomyopathy was observed in a single family of LHON patients with the 3460 mtDNA mutation could be explained by the co-inheritance of familial hypertrophic cardiomyopathy. Extensive screening for sarcomeric protein gene mutations that cause familial hypertrophic cardiomyopathy would be necessary to exclude this possibility, but several observations suggest that the cardiomyopathy was secondary to the 3460 mtDNA mutation; specifically the association between cardiomyopathy and other mitochondrial disorders, the presence of minor cardiac abnormalities in previous studies of patients with LHON, and the presence of 100% co-segregation of the 3460 mutation and cardiac disease.

The 3460, 11778, and 14484 mutations all alter the encoding of complex I, one of the five major protein complexes that make up the mitochondrial oxidative phosphorylation system. Complex I consists of over 40 protein subunits, seven of which (ND1-6, and ND4L) are encoded by mtDNA. The mtDNA encoded subunits are mainly intramembranous and are involved in interactions with ubiquinone and hydrogen ion transfer. The phenotypic heterogeneity with respect to cardiac involvement observed in this study may be explained in part by the different protein subunits that are affected by the 3460, 11778, and 14484 LHON mutations. The 3460 mutation occurs within the gene that encodes the ND1 protein subunit, causing the substitution of hydrophobic alanine for hydrophilic threonine in the NH<sub>2</sub> terminus of the polypeptide, which is rich in other hydrophobic residues. This mutation leads to a reduction in complex I dependent electron transfer activity and a 30–35% decrease in ATP synthesis. In contrast, the 11778 mutation which results in the substitution of histidine for arginine in the ND4 subunit does not appear to compromise electron transfer within the complex itself, but may disrupt interactions between the complex and NADH linked substrates. The 14484 mutation leads to the substitution of

valine for methionine in a poorly conserved region of the gene which codes for the ND6 subunit. Although the pathogenic basis of the 14484 mutation has not been studied extensively, reductions in complex I activity and ATP synthesis have been reported. In the future a greater understanding of the genotype–phenotype relation in this condition may be obtained from assessment of the degree of mtDNA heteroplasmy in the myocardium.

The findings in this study suggest that patients with LHON should routinely undergo cardiac evaluation with echocardiography and ECG. The relation between individual mutations and cardiac disease, and the natural history of cardiac disease in LHON, warrant further study.

## Authors' affiliations

\*P Sorajja, B Sachdev, W J McKenna, P M Elliott, Department of Cardiological Sciences, St George's Hospital Medical School, London, UK

M G Sweeney, R Chalmers, M Hanna, N D Wood, Institute of Neurology, The National Hospital for Neurology and Neurosurgery, London, UK

P Syrris, Department of Medical Genetics, St George's Hospital Medical School

\*Also Mayo Clinic, Rochester, Minnesota, USA

Correspondence to: Dr P M Elliott, Department of Cardiological Sciences, St George's Hospital Medical School, Cranmer Terrace, London SW17 0RE, UK; pelliott@sghms.ac.uk

Accepted 9 January 2003

## REFERENCES

- 1 Newman NJ. Leber's hereditary optic neuropathy. *Ophthalmol Clin North Am* 1991;4:431.
- 2 Wallace DC, Lott, Brown MD, *et al*. Report of the committee on human mitochondrial DNA. In: Cuticchia AJ, Pearson PL, eds. *Human gene mapping: a compendium*. Baltimore: Johns Hopkins University Press; 1995:910–54.
- 3 Nikoskelainen E, Wanne O, Dahl M. Pre-excitation syndrome and Leber's hereditary optic neuroretinopathy. *Lancet* 1985;i:696.
- 4 Eva-Riordan P, Harding AE. Leber's hereditary optic neuropathy: the clinical relevance of different mitochondrial DNA mutations. *J Med Genet* 1995;32:81–7.
- 5 Bower SPC, Hawley I, Mackey DA. Cardiac arrhythmia and Leber's hereditary optic neuropathy. *Lancet* 1992;339:1427–8.

## Erratum

Schiele TM, *et al*. Clinical and angiographic acute and follow up results of intracoronary  $\beta$  brachytherapy in saphenous vein bypass grafts: a subgroup analysis of the multicentre European registry of intraluminal coronary  $\beta$  brachytherapy (RENO). *Heart* 2003;89:640–4. Table 2 below was accidentally omitted. The error is regretted.

**Table 2** Procedure related parameters per lesion

Debulking	0 (0%)
Use of cutting balloon	10 (14.7%)
Nominal diameter of largest balloon used (mm)	4.03 (3.77)
New stent implanted	22 (32.4%)
Mean (SD) dose at 2 mm (Gy)	20.1 (3.2)
30 mm source train	20 (29.4%)
40 mm source train	47 (69.1%)
60 mm source train	1 (1.5%)
Pullback manoeuvre	17 (25.0%)
Fractionated treatment	4 (5.9%)
Primary success	62 (91.2%)