

CASE REPORT

Novel use of an “insertable” loop recorder

J R Gimbel

Heart 2003;89:e18 (<http://www.heartjnl.com/cgi/content/full/89/6/e18>)

A patient with palpitations and suspected arrhythmia underwent Holter and external loop recorder monitoring. No arrhythmias were detected by these traditional monitoring methods. An insertable loop recorder (ILR) was placed on the patient's chest and used as an extended loop recorder. An arrhythmia was ultimately recorded by the externally placed ILR leading to appropriate treatment.

The evaluation of a patient presenting with palpitations can be challenging, requiring the clinician to integrate the findings from the patient's history and physical examination, 12 lead ECG, and often ambulatory ECG monitoring techniques.¹ If arrhythmias are thought to be causative in patients with palpitations, recording an ECG while the patient is experiencing symptoms is most helpful. Despite improvements in technology, some patients find external monitors cumbersome and inconvenient² and refuse initial or repeated ambulatory ECG monitoring. The Reveal Plus (Medtronic, Inc, Minneapolis, Minnesota, USA) is a commercially available subcutaneously placed, leadless loop recorder with a battery life of approximately 18 months and can be used in the evaluation of “patients with unexplained recurrent palpitations”.³

While direct patient activation of the insertable loop recorder (ILR) through a small hand held pager-like device (Activator) is the primary means to capture a symptomatic arrhythmic event, the Reveal Plus can automatically detect significant bradycardic and tachycardic events to supplement patient activation. Despite the relatively benign nature of the surgery required to implant an ILR, some patients nevertheless refuse such implants because of, for example, the small but present risk of infection.⁴ Access to ILR use can be limited by insurance companies as well.

Having previously undergone traditional ambulatory ECG monitoring, a patient with a suspected arrhythmia who would not allow subcutaneous ILR placement underwent external loop recorder monitoring with an ILR. The externally placed ILR helped document an arrhythmia correlating with the patient's palpitations.

CASE REPORT

A Reveal Plus (model 9526) was resterilised after removal from a patient who had undergone five months of ILR monitoring. In an attempt to ascertain whether external ILR monitoring was feasible, the device was first applied externally to a patient undergoing an electrophysiology study for documented supraventricular tachycardia. Pacing from the right ventricular apex was used as a template for a wide complex tachycardia and the patient's own supraventricular tachycardia was induced and recorded by the externally applied ILR (fig 1). Because of the excellent recording quality, it was felt that an ambulatory patient would likely be adequately monitored by an externally applied ILR.

An otherwise healthy 45 year old man with no structural heart disease complained of intermittent palpitations lasting 10–30 seconds. He reported occasional dizziness but no syncope. An empirical trial of low dose β blockers failed to suppress his symptoms. Standard commercially available

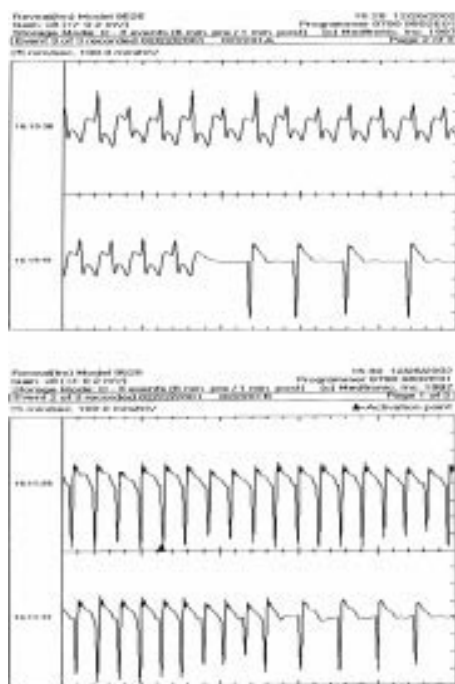


Figure 1 Recordings obtained from an externally applied insertable loop recorder during electrophysiology study. Ventricular pacing at 400 ms followed by the patient's own rhythm (above panel) and the patient's spontaneously occurring supraventricular tachycardia are shown.

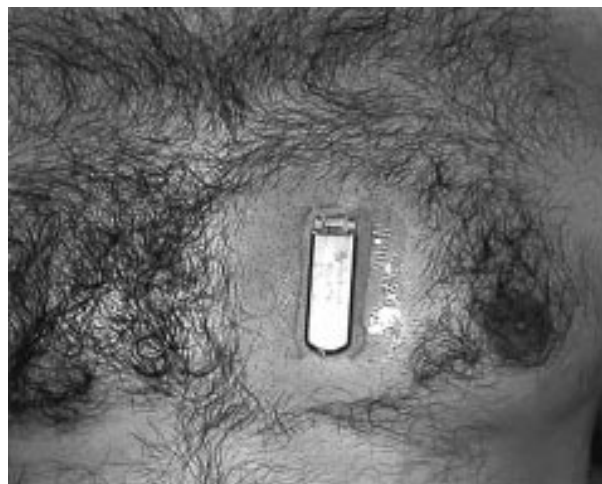


Figure 2 Placement of external insertable loop recorder on the patient's chest.

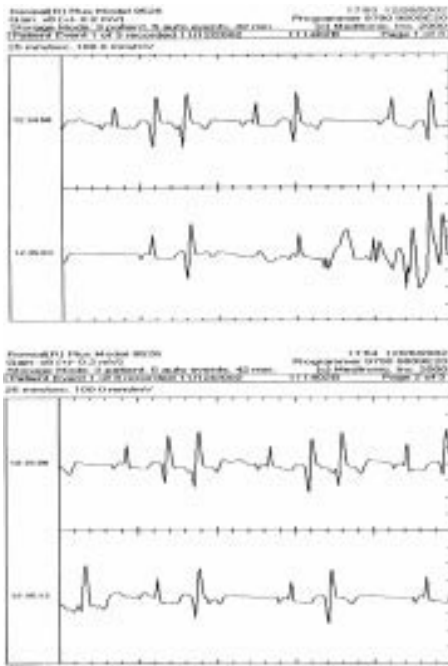

Figure 3 Recording from an externally applied insertable loop recorder in an ambulatory patient complaining of palpitations.

ambulatory ECG products were used in this patient for Holter monitoring and continuous loop event recorder monitoring, during which time the patient failed to record a symptomatic arrhythmic event. The patient found the ambulatory ECG monitors cumbersome and refused further monitoring with these devices. He was offered an ILR but refused on the basis of the required procedural invasiveness. He agreed to undergo application of an externally applied ILR.

The left parasternal region was shaved and then prepped using alcohol. A small amount of electrolyte gel (Cor-Gel; Spacelabs Burdick, Deerfield, Wisconsin, USA) was used to coat the surface of the ILR. After external mapping in the left parasternal region,⁵ a suitable ECG was found and the unit was held in place by placing a small section of sterile transparent dressing (Hermitage Hospital Products, Niantic, Connecticut, USA) over the device (fig 2). The patient was given a kit containing the electrolyte gel and a spare dressing and instructed to reposition the device if necessary.

Approximately one week after placement of the device the patient notified us that he had experienced palpitations and had used the Activator to capture a symptomatic event. The device was interrogated and its output is shown as recorded by the externally placed ILR (fig 3). The patient ultimately underwent an electrophysiological study and was found to have a right ventricular outflow tract origin for his extrasystoles. These were successfully ablated and the patient is now free of symptoms.

DISCUSSION

The evaluation of palpitations can be frustrating to both the patient and the clinician, as the often sporadic unpredictable nature of arrhythmias makes the capture of an ECG representative of the arrhythmia difficult. Patients also sometimes find current ambulatory ECG monitoring techniques awkward. We used an ILR that is approved for subcutaneous insertion in a novel manner. The external ILR was useful in documenting this patient's arrhythmia, ultimately helping to treat the patient effectively. Consideration may be given to the commercial development of an externally placed reusable loop recorder that has features similar to that of the available subcutaneously placed device.

Authors' affiliations

J R Gimbel, Parkwest Hospital, Knoxville, Tennessee, USA

Correspondence to: Dr J Rod Gimbel, Cardiology Associates of East Tennessee, 9330 Park West Blvd, Suite 202, Knoxville, TN 37923, USA; gimbeljr@ix.netcom.com

Accepted 18 February 2003

REFERENCES

- 1 **Zimetbaum P**, Josephson M. Evaluation of patients with palpitations. *N Engl J Med* 1998;**338**:1369–73.
- 2 **Zimetbaum PJ**, Josephson ME. The evolving role of ambulatory arrhythmia monitoring in general clinical practice. *Ann Intern Med* 1999;**130**:848–56.
- 3 **Crawford M**, Bernstein S, Deedwania P, *et al*. ACC/AHA guidelines for ambulatory electrocardiography: executive summary and recommendations. A report of the ACC/AHA task force on practice guidelines (committee to revise the guidelines for ambulatory electrocardiography). *Circulation* 1999;**100**:886–93.
- 4 **Krahn AD**, Klein GJ, Yee R, *et al*. Use of an extended monitoring strategy in patients with problematic syncope. *Circulation* 1999;**99**:406–10.
- 5 **Hartog J**, Hugl B, Menozzi C, *et al*. Evaluation of asymptomatic arrhythmia detected during the initial phase of the Reveal® Plus clinical study. European Society of Cardiology, August 2000. Access date 27 December 2002. URL: www.medtronic.com/reveal/evaluation.pdf.



Novel use of an "insertable" loop recorder

J R Gimbel

Heart 2003 89: e18

doi: 10.1136/heart.89.6.e18

Updated information and services can be found at:

<http://heart.bmj.com/content/89/6/e18>

These include:

References

This article cites 4 articles, 2 of which you can access for free at:

<http://heart.bmj.com/content/89/6/e18#BIBL>

Email alerting service

Receive free email alerts when new articles cite this article. Sign up in the box at the top right corner of the online article.

Notes

To request permissions go to:

<http://group.bmj.com/group/rights-licensing/permissions>

To order reprints go to:

<http://journals.bmj.com/cgi/reprintform>

To subscribe to BMJ go to:

<http://group.bmj.com/subscribe/>