

had isolated microvascular angina, 25 (17%) had isolated vasospastic angina, 31 (20%) had both (MVA & VSA) only 17 (11%) had non-cardiac chest pain. Myocardial bridging of coronary artery was found in 22 (15%). Multivariate predictors of MVA included typical angina, inducible ischaemia but traditional cardiovascular risk factors were not associated. Smoking and age were independent predictors of VSA.

Conclusion The majority of patients with symptoms and/or signs of ischemia and no obstructive disease have a diagnosis of microvascular and/or vasospastic angina. Traditional cardiovascular risk scores have limited discrimination for disorders of coronary vasomotion.

Conflict of Interest Nil

51 ANIMATION-SUPPORTED CONSENT IN PATIENTS UNDERGOING CORONARY ANGIOGRAPHY AND ANGIOPLASTY

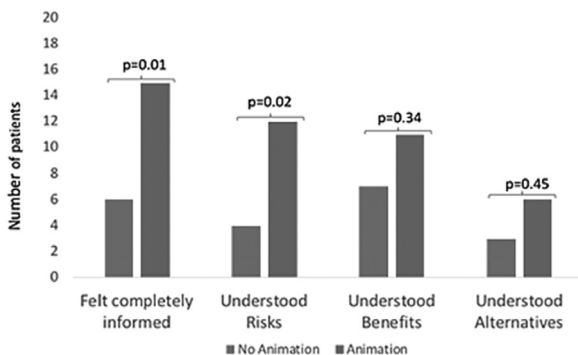
¹Prerna Singh*, ²David Wald, ³Vanessa Cobb. ¹Barts Health NHS Trust; ²Barts Health NHS Trust; ³Barts Health NHS Trust

10.1136/heartjnl-2019-BCS.49

Introduction Patient understanding of angiography and angioplasty is often incomplete at the time of consent. Language barriers and time constraints are significant obstacles. New approaches are needed to support communication and decision making. To this end, we developed a multi-language animation describing the benefits, risks and alternatives of the procedures (please click to view www.explainmyprocedure.com). We introduced the animation into practice in a pilot quality improvement project and assessed patients' understanding of the procedure before and after its introduction.

Methods Forty consecutive patients were interviewed, twenty who had watched the animation prior to their procedure and twenty who had not, to determine whether they felt completely informed, understood the benefits, the risks and the alternative treatments. Responses to these four questions were analysed categorically and ratios calculated for the animation group compared with the non-animation group (with 95% confidence intervals). STATA V10 was used for all analyses.

Results Table 1 shows that patients in the animation group (mean age 64 years) and in the no animation group (mean age 68 years) were well matched. Figure 1 shows that understanding of the procedure was greater in the animation group across all four questions. In the animation group there was a statistically significant 3-fold greater understanding of the risks



Abstract 51 Figure 1 Patient understanding of the procedure in the animation and no animation groups

Abstract 51 Table 1 Clinical characteristics of the forty patients according to whether they were or were not shown the animation before their procedure

	Not shown Animation (n=20)	Shown Animation (n=20)
Male	17	13
Female	3	7
Angiogram	15	13
PCI	5	7
Elective	20	19
Previous Angiogram	7	8
English Speaker	11	14

p value not significant for any differences in variables between two groups

of the procedure (ratio 3.0 (95% CI 1.2 to 7.7), $p=0.023$) and a 2.5-fold increase in the proportion of patients who felt completely informed before giving consent (2.5 (1.2 to 5.1), $p=0.01$). There were directional, but non-significant, increases in understanding of the benefits and alternatives of the procedure; ratios 1.6 (0.8 to 3.2), $p=0.34$ and 2.0 (0.6 to 6.9), $p=0.45$, respectively.

Conclusion Viewing animations of angiography and angioplasty before consent was associated with a greater understanding of the procedures and the associated risks. Multi-language narration has the potential to further improve communication surrounding consent. The approach is not limited to cardiology and has the potential to be applied to all specialties in medicine.

Conflict of Interest No conflict of interest

52 OPTIMISATION OF A CELL-BASED MODEL FOR THE CHARACTERISATION OF NOVEL DRUG-FREE STENT COATINGS

¹Daniel Longhorn*, ²Susan Currie, ³Christopher McCormick. ¹University of Strathclyde; ²University of Strathclyde; ³University of Strathclyde

10.1136/heartjnl-2019-BCS.50

Current pharmacological approaches aimed at improving stent designs are limited by their inability to reduce endothelial damage following stent placement and improve healing. Here, we consider in vitro approaches that could be used to assess the effects of novel anti-oxidant stent coatings on damaged endothelial cells following stent placement. Oxidative stress is a physiological response to inflammation and can result in activation of intracellular signalling molecule, leading to pathological effects. One such molecule is calcium/calmodulin dependent protein kinase II δ (CaMKII δ). Hyper-activation of CaMKII is known to be directly linked to disease progression in the heart and it has been implicated in endothelial dysfunction. It is therefore of interest to examine how novel drug-free stent coatings might reduce or reverse oxidative damage following stent placement and whether CaMKII may be a potential target. Our initial experiments have used human umbilical vein endothelial cells (HUVECs), challenged with inflammatory and oxidative stress as a model for future investigations with novel stent coatings.

Novel stent-coatings were generated on 200 μ m stainless steel wires (316L medical grade), and their antioxidant activity assessed at 8h and 24h using a DPPH (2,2-diphenyl-1-picrylhydrazyl) colorimetric assay and expressed as a percentage of scavenged to total radicals. Antioxidant activity was observed

Correction: 51 Animation-supported consent in patients undergoing coronary angiography and angioplasty

Singh P, Wald D, Cobb V. 51 Animation-supported consent in patients undergoing coronary angiography and angioplasty. *Heart* 2019;105:A44.

In this abstract the author order should have been Wald D, Singh P, Cobb V.

© Author(s) (or their employer(s)) 2020. No commercial re-use. See rights and permissions. Published by BMJ.

Heart 2020;106:e2. doi:10.1136/heartjnl-2019-BCS.49corr1

