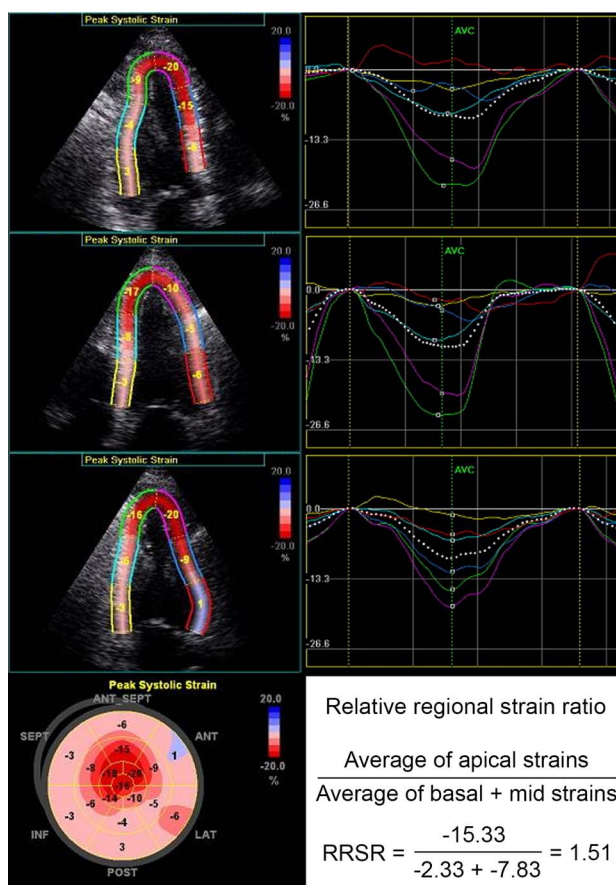


## Erratum 'Prognostic implication of relative regional strain ratio in cardiac amyloidosis'

Senapati A, Sperry BW, Grodin JL, *et al.* Prognostic implication of relative regional strain ratio in cardiac amyloidosis. *Heart* 2016;102:748–754

The [figure 1](#) and its legend in the current version of this paper includes incorrect data. Below is the correct figure and updated legend.



**Figure 1** Longitudinal strain (LS) imaging in cardiac amyloidosis. This is a representative example of peak systolic LS imaging in a patient with biopsy-proven cardiac amyloidosis. There is apical sparing of LS as calculated by more negative values visualised on the target plot. The relative regional strain ratio (RRSR), calculated as the average of apical strains divided by the average of basal plus the average of mid strains, in this example is 1.51.

*Heart* 2016;102:1419. doi:10.1136/heartjnl-2015-308657corr1

