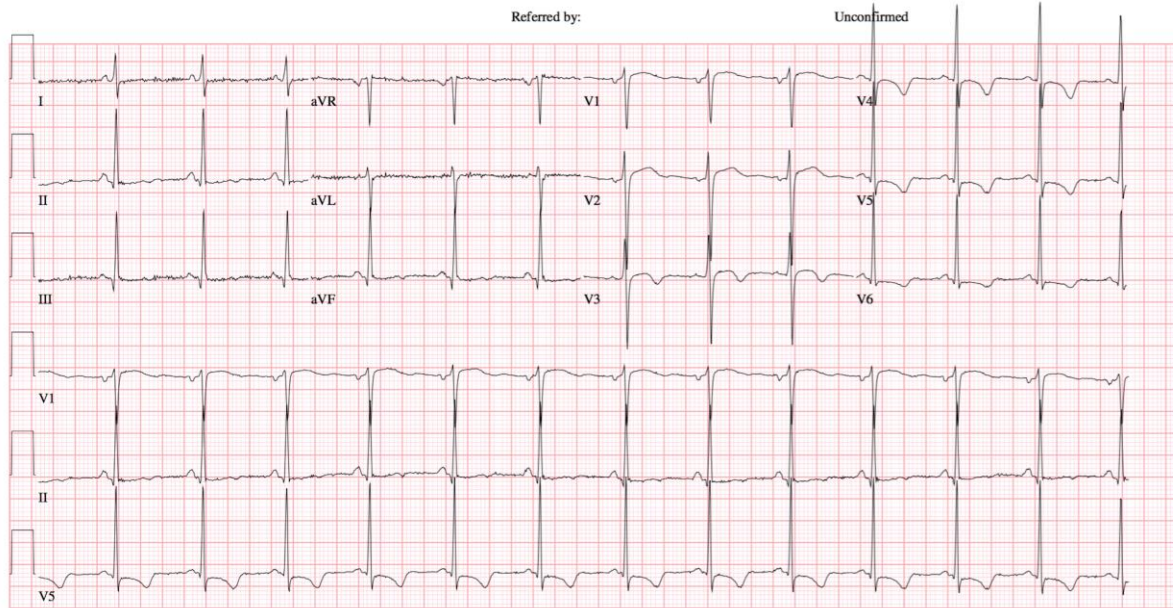


**SUPPLEMENTARY FIGURE 1: 12-lead electrocardiogram.**



**SUPPLEMENTARY MOVIE 1**

Echocardiography video loop in modified four chamber view.

**SUPPLEMENTARY MOVIE 2**

Cine magnetic resonance sequence in four chamber view.