

006

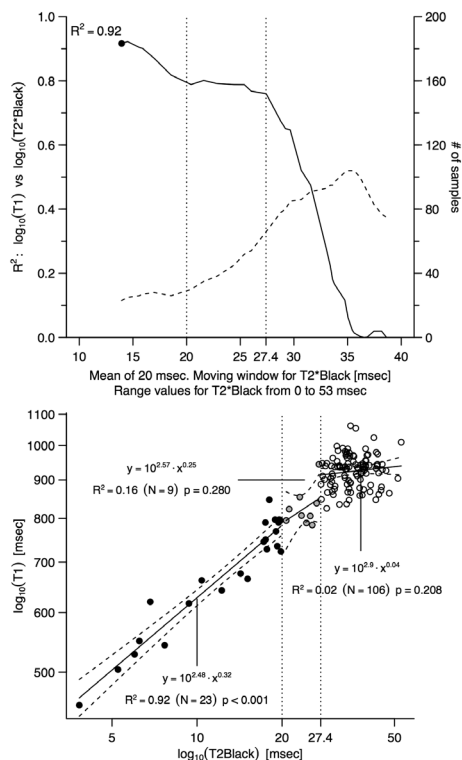
ROLE OF T1 MAPPING AS A COMPLEMENTARY TOOL TO T2* FOR NON-INVASIVE CARDIAC IRON OVERLOAD ASSESSMENT

¹Department of Cardiovascular, Neural and Metabolic Sciences, San Luca Hospital, Istituto Auxologico Italiano, Milan, Italy; ²Barts Heart Centre, St Bartholomew's Hospital, London, UK; ³Rare Diseases Centre, Department of Medicine and Medical Specialities, "Ca' Granda" Foundation IRCCS, Milan, Italy; ⁴CMR Unit, Cardiology 4, Department of Cardiology and Cardiovascular Surgery, Niguarda Hospital, Milan, Italy; ⁵Institute of Cardiovascular Science, University College London, London, UK; ⁶Department of Health Sciences, University of Milano-Bicocca, Milan, Italy; ⁷The National Institute of Health Research, University College London Hospitals Biomedical Research Centre, London, UK; ⁸Department of Clinical Science and Community Health, University of Milan, Milan, Italy

10.1136/heartjnl-2017-311399.6

Background Iron overload-related heart failure is the principal cause of death in transfused Thalassemia Major¹⁻² and other iron overload patients. Linking cardiac siderosis measured by T2* to therapy improves outcome in Thalassemia Major. Aim of our study is to compare T1 mapping (Modified Look Locker Inversion recovery, MOLLI) to dark (DB) and bright (BB) blood T2*³⁻⁴ in cardiac iron overload and to support the hypothesis that T1 mapping has higher sensibility to T2* for small amount of iron, which would make it a complementary tool to T2* in borderline iron overload patients.⁵⁻⁶

Methods In a prospectively large single centre study of 138 Thalassemia Major patients and 32 healthy controls, we compared MOLLI to DB and BB T2* acquired on an Avanto 1.5T scanner (Siemens Healthcare, Erlangen, Germany). Linear regression analysis was used to assess the association between DBT2* and either BBT2* and MOLLI, and the determination coefficient was computed in a log-log scale with moving windows to detect the point where this association decreases.



Abstract 006 Figure 1

Results The relationship between T2* (here DB) and MOLLI is described by a log-log linear regression, which can be split in three different slopes: 1) T2* low, <20ms: $r^2=0.92$; 2) T2*=20–28 ms: $r^2=0.80$; 3) T2*>28 ms, no relationship. All subjects with T2*<20 ms had low T1; of those with T2*>20 ms, 38% had low T1.

Conclusions These data support the former proposal that T1 detects missed iron 1 in 3 subjects with normal T2* and that T1 mapping is a complementary tool for non-invasive assessment of cardiac iron. The clinical significance of a low T1, normal T2* should be further investigated. A trend toward LV end diastolic volume increase was observed in the patients with low T1 and normal T2* at 24 months, but the sample was too small to be analysed ($n=9$).

REFERENCES

- Modell B, Khan M, Darlison M, Westwood MA, Ingram D, Pennell DJ. Improved survival of thalassaemia major in the UK and relation to T2* cardiovascular magnetic resonance. *J Cardiovasc Magn Reson* 2008;**10**:42.
- Carpenter JP, Pennell DJ. On T2* Magnetic Resonance and Cardiac Iron. *Circulation* 2011;**14**:1519–28.
- Wood JC, Otto-Duessel M, Aguilar M, et al. Cardiac Iron Determines Cardiac T2*, T2, and T1 in the Gerbil Model of Iron Cardiomyopathy. *Circulation* 2005;**112** (4):535–543.
- Carpenter JP, He T, Kirk P, et al. Calibration of myocardial T2 and T1 against iron concentration. *J Cardiovasc Magn Reson* 2014;**16**:62.
- Alam MH, Auger D, Smith GC, et al. T1 at 1.5T and 3T compared with conventional T2* at 1.5T for cardiac siderosis. *J Cardiovasc Magn Reson*. 2015;**17**:102.
- Messroghli DR, Radjenovic A, Kozerke S, Higgins DM, Sivanathan MU, Ridgway JP. Modified Look-Locker inversion recovery (MOLLI) for high-resolution T1 mapping of the heart. *Magn Reson Med* 2004;**52**(1):141–6.
- Alam MH, Auger D, Smith GC, et al. T1 at 1.5T and 3T compared with conventional T2* at 1.5T for cardiac siderosis. *J Cardiovasc Magn Reson* 2015;**17** (24):102.

007

COMPREHENSIVE ECHOCARDIOGRAPHIC AND CARDIOVASCULAR MAGNETIC RESONANCE EVALUATION DIFFERENTIATES BETWEEN PATIENTS WITH HEART FAILURE WITH PRESERVED EJECTION FRACTION, HYPERTENSIVE PATIENTS AND HEALTHY CONTROLS AND IDENTIFIES THOSE WITH REDUCED EXERCISE CAPACITY ON CARDIOPULMONARY EXERCISE TESTING

Ily Mordji, Satnam Singh, Amelia Rudd, Janaki Srivanasan, Michael Frenneaux, Nikolaos Tzemos, Dana K Dawson. *University of Dundee, UK*

10.1136/heartjnl-2017-311399.7

Objectives The aim of this study was to investigate the utility of a comprehensive imaging protocol including echocardiography and cardiovascular magnetic resonance (CMR) in the diagnosis and differentiation of hypertensive heart disease and heart failure with preserved ejection fraction (HFpEF).

Background Hypertension is present in up to 90% of patients with HFpEF and is a major aetiological component. Despite current recommendations and diagnostic criteria for HFpEF, no non-invasive imaging technique has as yet shown the ability to identify any structural differences between patients with hypertensive heart disease and HFpEF.

Methods We conducted a prospective cross-sectional study of 112 well-characterised patients (62 with HFpEF, 22 with hypertension and 28 healthy controls). All patients underwent cardiopulmonary exercise and biomarker testing and an imaging protocol including echocardiography with speckle tracking analysis and CMR including T1 mapping pre- and post-contrast.