

Online Supplement

Title: *First in-human modified atrial septostomy combining radiofrequency ablation and balloon dilation*

Authors: *Chaowu Yan, Linyuan Wan, Hua Li, Cheng Wang, Tingting Guo, Hanxu Niu, Shiguo Li, Pingcuo Yundan, Lei Wang, Wei Fang.*

Correspondence to: *Chaowu Yan* **Email:** *chaowuyan@163.com*

Legends for the Videos

Video 1: Delineation of Fossae Ovalis With Intracardiac Echocardiography. Under the guidance of intracardiac echocardiography, the fossae ovalis was delineated and reconstructed.

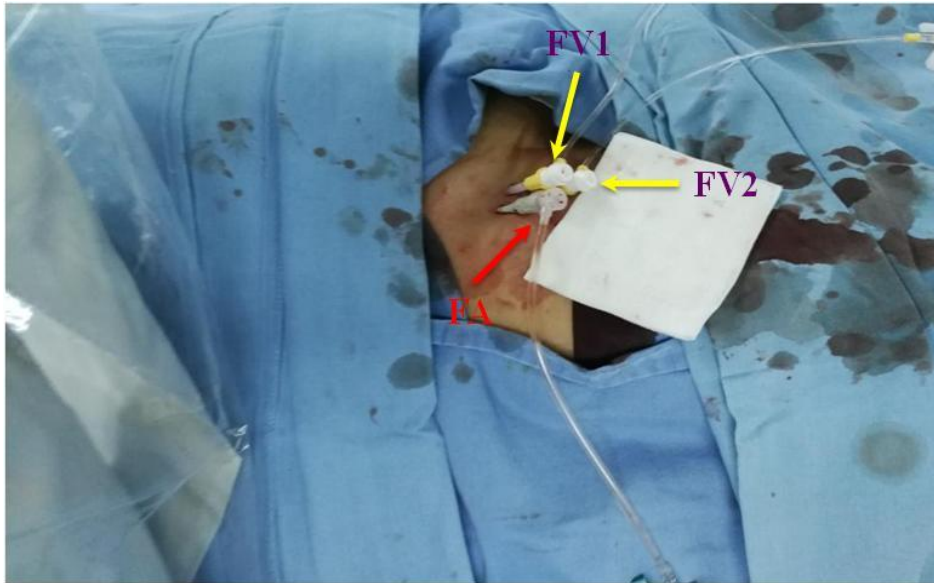
Video 2: Radiofrequency Catheter Ablation on Fossae Ovalis. The SmartTouch SF catheter touched the region of the fossae ovalis, and radiofrequency ablation was performed point-by-point to cover the fossae ovalis.

Video 3: Radiofrequency Catheter Ablation Around Fenestration-rims. From a series of holes at the very distal tip of SmartTouch SF catheter, microbubbles of irritating saline were identified simultaneously in the left atrium and right atrium. The contact force was continuously recorded, which ensured the correct position of the electrode tip.

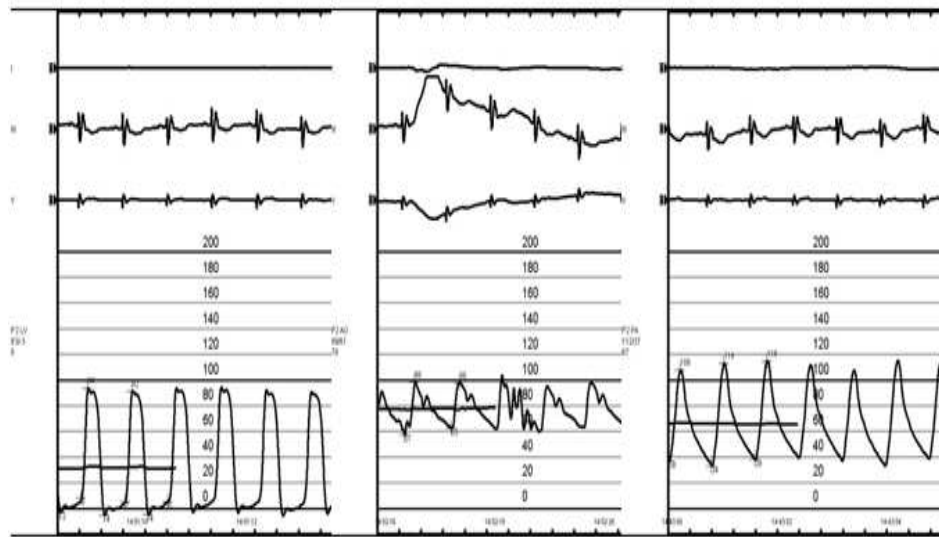
Video 4: Postoperative Evaluation With Intracardiac Echocardiography. After the procedure, the fenestration was evaluated with intracardiac echocardiography. There was continuous right-to-left shunting through the interatrial fenestration.

Video 5: Repeated Right Heart Catheterization and Atrial Angiography. At 1 year after the procedure, a 6F multipurpose diagnostic catheter was advanced into the left atrium transvenously via the interatrial fenestration. Atrial angiography was performed during the withdrawal of the catheter, and the patency of the interatrial communication was confirmed in the left anterior oblique view. *Note: The patient underwent surgical repair of a ventricular septal defect ten years ago.*

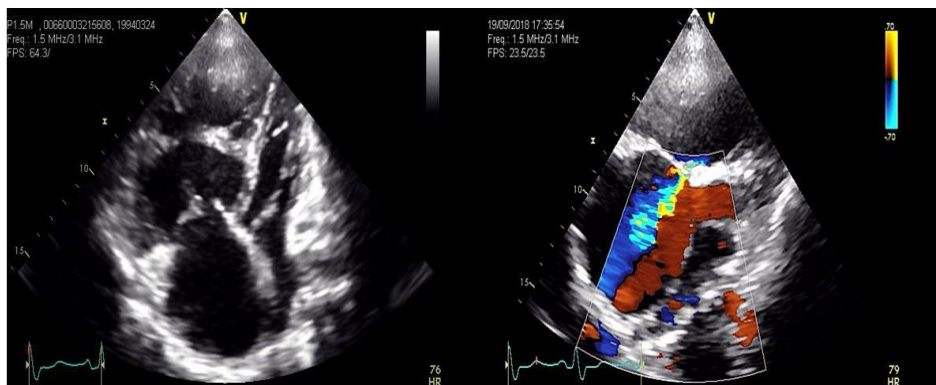Supplemental Figure 1



Legend: After percutaneous punctures of right femoral vein and artery, two intravenous introducers (8F and 11F) and one arterial introducer (5F) were inserted, respectively. *Note: FV, femoral vein; FA, femoral artery.*

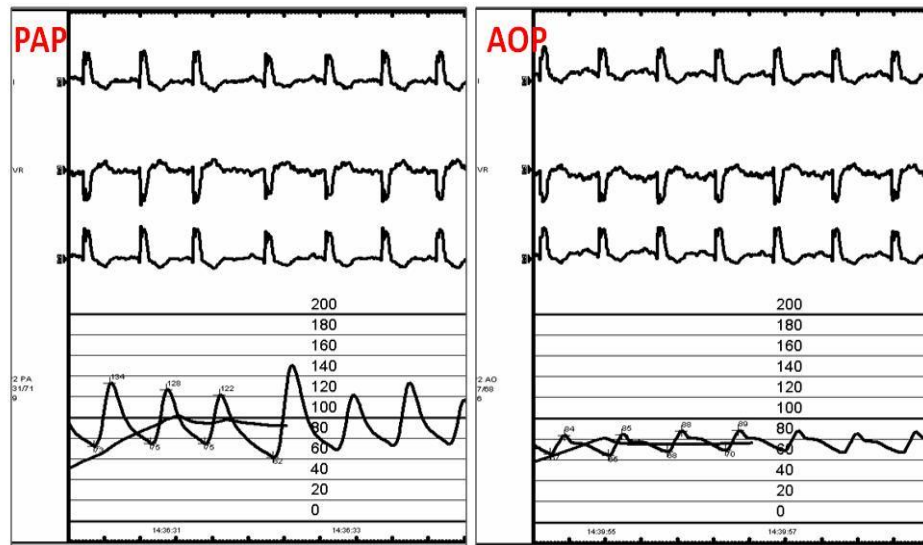Supplemental Figure 2

Legend: Left and right heart catheterization was conducted, and left ventricular pressure, aortic pressure and pulmonary artery pressure were recorded. *Note: LV, left ventricle; AO, aorta; PA, pulmonary artery.*

Supplemental Figure 3

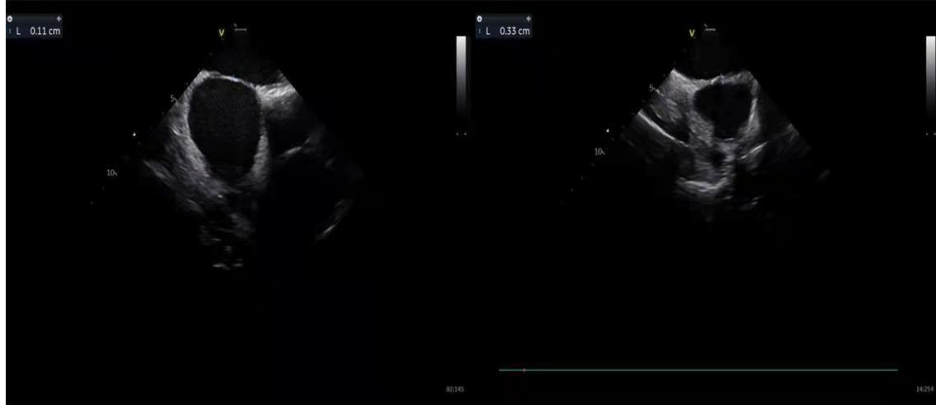
Legend: Preoperative transthoracic Doppler echocardiography showed a markedly dilated right atrium and right ventricle and compressed left atrium and left ventricle.

Supplemental Figure 4

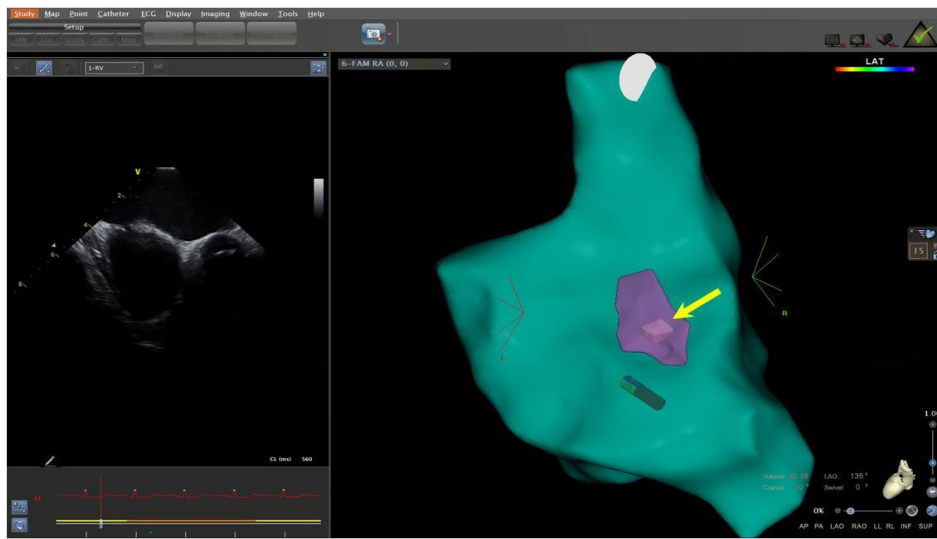


Legend: In most patients, pulmonary artery pressure was supra-systemic. *Note:* PAP, pulmonary artery pressure; AOP, aortic pressure.

Supplemental Figure 5

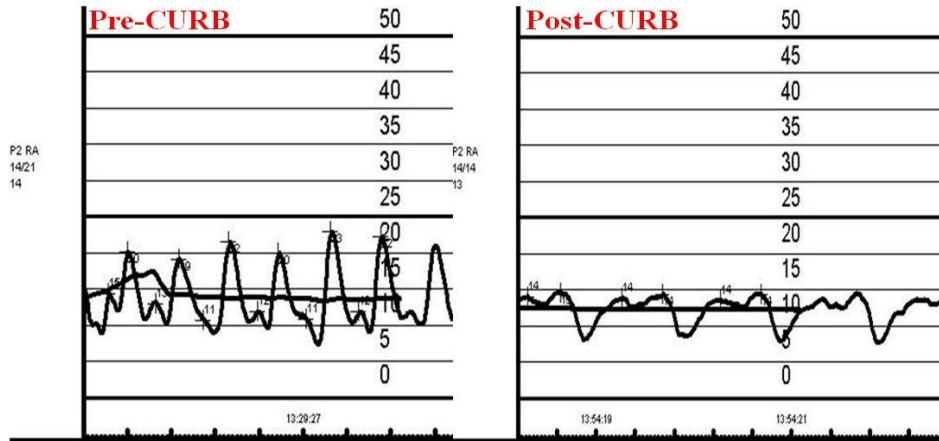


Legend: The thickness of fossae ovalis varied greatly in patients with severe PAH. *Note:* left panel, the thickness was 1.1mm; right panel, the thickness was 3.3mm.

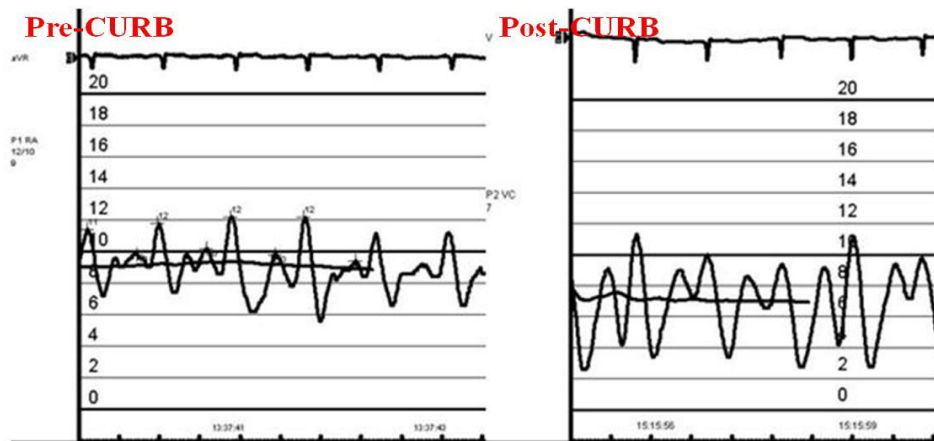
Supplemental Figure 6

Legend: The created-fenestration (white area indicated by yellow arrow) was located in the central area of fossae ovalis (purple area).

Supplemental Figure 7
Case-1

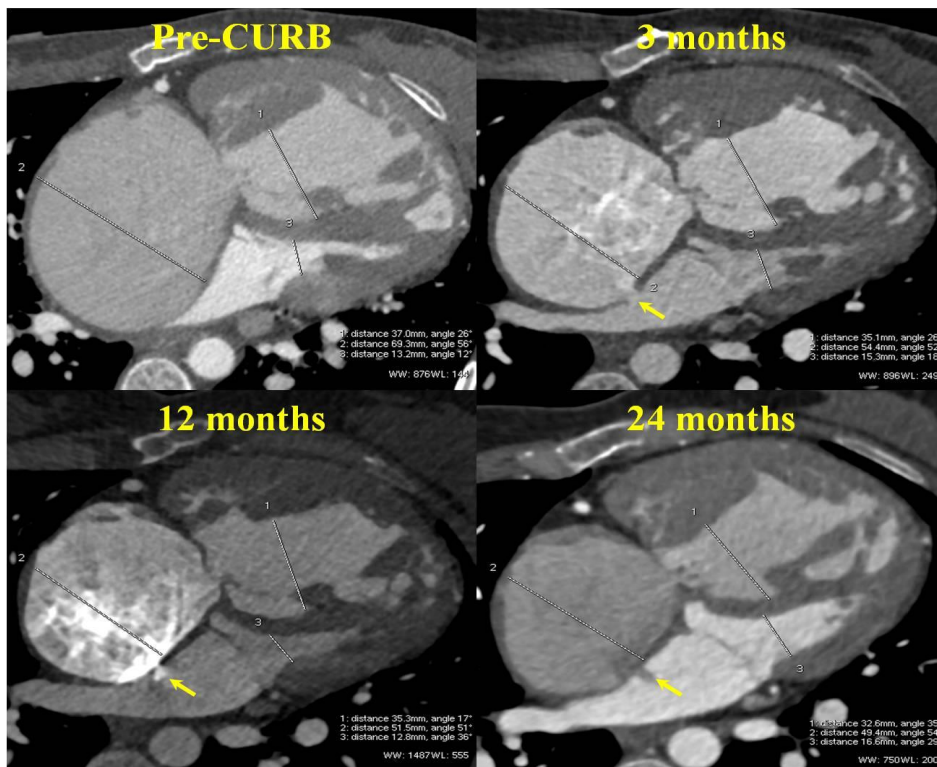


Case-2



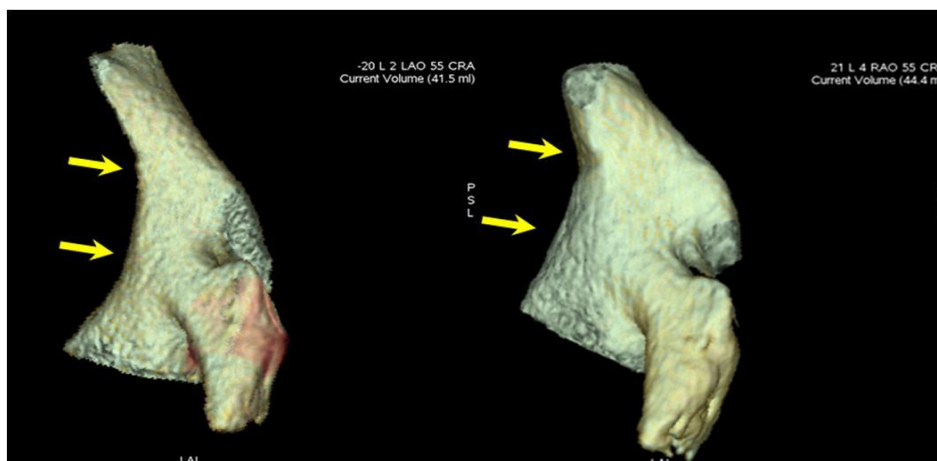Legend: After CURB, right atrial pressure decreased in most patients. *Note:* RA, right atrium; VC, vena cava.

Supplemental Figure 8



Legend: Serial follow-up with multi-slice computed tomography showed that the created-fenestration was patent (arrows). Right to left shunting can be detected.

Supplemental Figure 9



Legend: After CURB, multi-slice computed tomography showed that the compressed left atrium was alleviated with the increase of left atrial volume from 41.5 ml to 44.4 ml. Note: Left panel, pre-CURB; Right panel, post-CURB; Arrows, atrial septum.