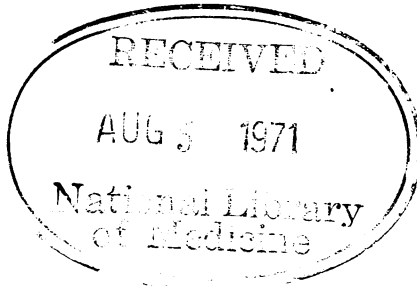


# British Heart Journal

READING ROOM

Editor K  
Assistant



Br Heart J: first published as on 1 July 1971. Downloaded from <http://heart.bmj.com/> on January 18, 2021 by guest. Protected by copyright.

Editorial: Cardiac rehabilitation <i>Groden, Semple, and Shaw</i>	425	Acid-base imbalance and arrhythmias after myocardial infarction <i>Pilcher and Nagle</i>	526
'Fixed' splitting of second heart sound in VSD <i>Harris, Wise, Jr., and Oakley</i>	428	Cardiorespiratory changes in progressive muscular dystrophy <i>Wahi, Bhargava, and Mohindra</i>	533
Early rate of resolution of major pulmonary embolism <i>McDonald, Hirsh, and Hale</i>	432	Systolic clicks with ventricular septal defects <i>Pickering and Keith</i>	538
Effect of exercise on distribution of pulmonary blood flow in patients with mitral stenosis <i>Bjure, Liander, and Widimský</i>	438	Plasma digoxin concentrations and digoxin toxicity in hospital patients <i>Evered and Chapman</i>	540
Haemodynamic effects of phentolamine in chronic obstructive pulmonary disease <i>Gould, Zahir, DeMartino, and Gomprecht</i>	445	Aberrant muscle bundle of the right ventricle <i>Barnes, Kwong, and Cheung</i>	546
Fistulae between the coronary arteries and the right cavities of the heart <i>Azcuna, Cabrera, Aruza, and Iriarte</i>	451	Congenital aortic stenosis - an unusual form <i>Somerville and Ross</i>	552
Postoperative complete heart block in children <i>Fryda, Kaplan, and Helmsworth</i>	456	Angiographic assessment of left ventricular function in patients with ischaemic heart disease without clinical heart failure <i>Chatterjee, Sacoer, Sutton, and Miller</i>	559
Assessment of cardiac apex impulse using fiberoptics <i>Cole and Conn</i>	463	Assessment of left ventricular function by single plane cineangiographic volume analysis <i>Chatterjee, Sacoer, Sutton, and Miller</i>	565
Circulation, lung, and finger clubbing in hepatic cirrhosis <i>Stanley and Woodgate</i>	469	Atrioventricular dissociation with accochage <i>Fletcher, Morton, Murtagh, and Bekheit</i>	572
Assessment of propranolol in angina pectoris <i>Prichard and Gillam</i>	473	Apex cardiogram and systolic time intervals in acute myocardial infarction <i>Jain and Lindahl</i>	578
Acute effects of oral alprenolol on exercise tolerance in patients with angina pectoris. A dose-response study <i>Sealey, Liljedal, Nyberg, and Åblad</i>	481	Acute myocardial infarction without obstructive coronary artery disease demonstrated by selective cinearteriography <i>Bruschke, Bruyneel, Bloch, and van Herpen</i>	585
Catheterization of left ventricle in acutely ill patients <i>Diamond, Marcus, McHugh, Swan, and Forrester</i>	489	Conservative treatment of AV block in acute myocardial infarction <i>Hatle and Rokseth</i>	595
Relations between pressure in pulmonary artery, left atrium, and left ventricle with special reference to events at end diastole <i>Forsberg</i>	494	Double-blind three-dose trial of oral alprenolol in angina pectoris <i>Sowton and Smithen</i>	601
Appraisal of multifocal atrial tachycardia <i>Chung</i>	500	Proceedings of the British Cardiac Society	607
Parasytolic ventricular tachycardia <i>Roelandt and Schamroth</i>	505	Case Reports	
Heart rate and intermittent Wolff-Parkinson-White syndrome <i>Moulopoulos, Plassaras, and Sideris</i>	513	Syncope on swallowing <i>Sapru, Griffiths, Guz, and Eisele</i>	617
Quinidine in maintenance of sinus rhythm after electroconversion of chronic atrial fibrillation <i>Hillestad, Bjerkelund, Dale, Maltau, and Storstein</i>	518	Hydatid cyst of interventricular septum causing left anterior hemiblock <i>de los Arcos, Madurga, Leon, Martinez, and Urquia</i>	623
Treatment and prevention of cardiac arrhythmias with propranolol and quinidine <i>Stern</i>	522	Intraventricular trifascicular block <i>El-Sherif</i>	626
		Quinidine overdose <i>Kerr, Kenoyer, and Bilitch</i>	629
		Correspondence	632
		British Medical Association	