

Catheterization of left ventricle in acutely ill patients¹

George Diamond², Harold Marcus, Thomas McHugh, H. J. C. Swan, and James Forrester³

From the Department of Cardiology, Cedars-Sinai Medical Center and the Department of Medicine, University of California at Los Angeles, U.S.A.

A technique of left ventricular catheterization at the bedside without the aid of fluoroscopy is described. The left ventricle was entered successfully in 89 per cent of the instances, and catheters were left in place for a total of 626 hours in 26 acutely ill patients for serial monitoring. Preliminary use of this technique suggests its efficacy and relative safety in diagnosis and therapy, where experienced personnel and facilities for intensive monitoring are available.

Though central venous pressure is being used routinely as a clinical guide to fluid management, recent reports cite major discrepancies which may occur between right and left heart pressures in such states as acute myocardial infarction and acute pulmonary embolization, in which pathophysiological changes may be localized to a single ventricle (Forrester *et al.*, 1970a; Cohn, Khatri, and Hamosh, 1970). In such conditions, catheterization of the left ventricle allows one to obtain information that more directly relates to left ventricular performance. Specifically, left ventricular diastolic pressure serves as a most useful haemodynamic index of left heart failure in acutely ill patients. Furthermore, changes in this pressure may be used to guide fluid therapy accurately and to indicate the response to other therapeutic interventions. Left ventricular pressure measurement can be used to quantify more precisely left ventricular contractility by permitting the calculation of the maximum velocity of contractile element shortening (V_{max}) (Hugenholtz *et al.*, 1970; Forrester *et al.*, 1970b; Enright, Hannah, and Reis, 1968). The use of this index of contractility in conjunction with heart rate, left ventricular end-diastolic, and arterial pressure defines the principal factors that determine

myocardial oxygen consumption (Braunwald, 1969). In spite of these advantages, however, the apparent inherent risk and technical complexity of catheterization of the left ventricle in acutely ill patients has limited its widespread application. Though Kirby, McNicol, and Tattersfield (1968) have described their experience with left ventricular catheterization in two patients with acute myocardial infarction, the only reported series of human left ventricular catheterization at the bedside is that of Cohn, Tristani, and Khatri (1969). Their method may be performed without fluoroscopy, using a 7F polyethylene catheter introduced percutaneously through a femoral artery. Though no complications were reported, this technique has several inherent disadvantages since the site of entry, the relatively large size of the catheter, and the material from which it is constructed may all predispose to thromboembolic complications. Though no instances of such a complication were reported, the nature of the catheter is such that occasional entry into the left coronary artery orifice might be anticipated. Furthermore, the size of the catheter precludes long-term monitoring of left ventricular pressures. Lastly, the technique is only applicable to femoral artery insertion, and seriously restricts both patient movement and passive exercise of the legs. This report describes our experience with a percutaneous technique of bedside catheterization of the left ventricle which largely eliminates the above problems, thereby making left ventricular catheterization both inherently safer and more clinically useful.

Received 11 September 1970.

¹ Supported in part by grants from Myocardial Infarction Research Unit, National Institutes of Health (Training Grant), United Hostesses Charities, and United States Public Health Service.

² Fellow under National Institutes of Health.

³ Harold J. Mirisch Fellow of United Hostesses Charities.

Method

After informed consent is obtained from the patient or a responsible next of kin, either the antecubital or femoral area is washed with tincture of benzalkonium hydrochloride and the patient is draped with a large sterile sheet. After local infiltration with 1 per cent lignocaine, the artery is punctured at its most superficial portion with an 18T Courmand needle. A 120 cm flexible safety guide wire (I.D. 0.036 in.) is advanced through the needle approximately 30 cm. The needle is then removed and the guide is wiped clean with sterile heparinized saline. A 100 cm 5F radioopaque Teflon, end-hole catheter (I.D. 0.040 in, O.D. 0.066 in) terminating in a 1.5 cm reversed loop (Fig. 1) is threaded over the guide after

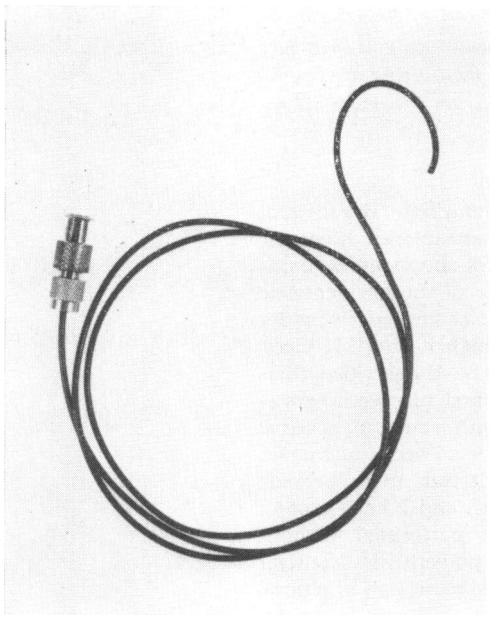


FIG. 1 5F Teflon catheter used for bedside determination of left ventricular pressure. For details of design, see text.

flushing with heparinized saline. The catheter is advanced to the site of skin entry and the guide is then withdrawn 1 cm at a time into the catheter, until the distal end of the guide emerges from the distal end of the catheter. An assistant holds this portion of the guide while the catheter is advanced with a twisting motion approximately 10 cm into the artery. The guide wire is then withdrawn 18–19 cm so that its flexible tip is judged to just protrude from the tip of the catheter. The catheter and guide are now advanced together while monitoring the electrocardiogram. No resistance to passage of the catheter should be felt until it impinges upon the aortic valve. The small reverse loop at the tip of the catheter prevents inadvertent entry into either the left coronary artery or carotid vessels. The catheter usually enters the left ven-

tricle easily with the production of 1 to 3 premature ventricular contractions which indicate that the left ventricle has been entered. The catheter is advanced several centimetres further into the chamber to a position of electrical stability and the guide wire is withdrawn. Heparinized saline is used to flush the catheter free of blood. Pressure is measured with a Statham P23 Db strain gauge transducer and recorded on a multichannel Cleveite Brush pen recorder, filtered at 10 Hz, if necessary. A chest x-ray is then obtained to determine the exact position of the catheter.

Results

Fig. 2 and 3 show a typical pulse contour obtained with the left ventricular catheter connected to a Statham P23 Db transducer via a 41 cm length of Teflon high pressure tubing (I.D. 0.042 in). The frequency response of such a system is flat ± 5 per cent up to 10 Hz.

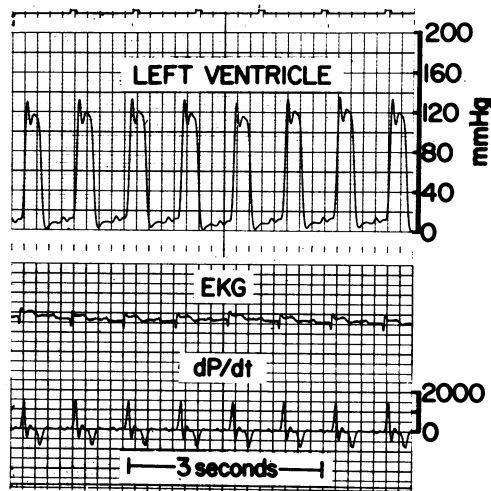
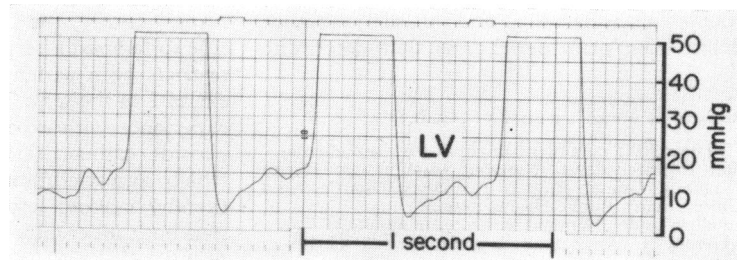


FIG. 2 Left ventricular pressure obtained with a 5F Teflon catheter and recorded simultaneously with lead II of the electrocardiogram and the first derivative of pressure.

FIG. 3 High gain and high speed recording of left ventricular pressure in the same patient as in Fig. 2 for determination of end-diastolic pressure.



The left ventricle was entered successfully in 28 of 32 total attempts (89%) in 23 of 26 patients. The catheter was passed via the brachial artery in 15 instances and via the femoral artery in 17. Twenty-two of the patients had acute myocardial infarction, 18 were in shock, and 3 had isolated left ventricular failure. Of the total group, 16 died of their acute illness while in hospital. Continuous left ventricular pressure monitoring was accomplished for a total of 626 hours, from 1 hour to 6 days (mean, 27 hours), depending on each patient's clinical need.

Complications

A Arrhythmias One to three premature ventricular contractions occurred in all patients upon initial insertion of the catheter into the left ventricle. After placement of the catheter in a stable position, there were no further premature ventricular contractions in 15 patients. In all but one of the other 8 patients, premature ventricular contractions occurred only sporadically and abated upon withdrawal of the left ventricular catheter approximately 1 to 2 cm. The last patient developed a single bout of ventricular tachycardia that was immediately cardioverted to normal sinus rhythm. She had no ventricular irritability either before or after this arrhythmia though the left ventricular catheter remained in place.

B Thrombosis - embolism No episode of clinically evident embolization was observed. Peripheral pulses distal to the site of catheter insertion remained unchanged. In one patient studied for 70 hours, who died with the catheter *in situ*, adherent thrombus was found at necropsy. This patient had severe shock secondary to haemorrhagic pancreatitis and was the only patient not on anticoagulants during his illness.

C Other One patient continued to ooze blood from the entry site in his femoral artery while on therapeutic doses of warfarin. This bleeding prompted premature removal of the catheter, after which bleeding was easily controlled. In another patient, after successful catheter insertion via the left brachial artery, and upon removal of the guide wire, the flexible tip of the guide wire was found to be missing. X-ray examination showed it to be lodged in the left subclavian artery. Serial x-rays indicated no change in the position of this fragment over a two-week period. The patient, who had sustained a severe acute myocardial infarction with pulmonary oedema, refused any attempts at removal of

the guide wire fragment, and he was subsequently discharged on oral anticoagulants. He has remained asymptomatic.

Specific cases illustrating particular applications

Case 1 A 62-year-old man with acute haemorrhagic pancreatitis was admitted to the intensive care unit in shock with a systolic blood pressure of 75 mmHg. Central venous pressure was 5 cm H₂O. After volume replacement, the central venous pressure rose to 15 cm H₂O, but his arterial blood pressure remained unchanged. A catheter was then inserted into the left ventricle and a pressure of 70/0-2 mmHg was obtained. On the basis of the measured left ventricular diastolic pressure values, the raised central venous pressure was not considered a contraindication to further fluid administration, and 500 ml albumin was administered over a period of 15 minutes. Systolic blood pressure rose to 130 and left ventricular end-diastolic pressure to 12 mmHg, with concomitant increase in urinary output.

Comment This patient suffered from chronic obstructive pulmonary disease. A raised central venous pressure was present because of high pulmonary vascular resistance and chronic right ventricular failure in spite of intravascular volume depletion.

Case 2 A 72-year-old man was admitted to the coronary care unit with an acute myocardial infarction and an arterial blood pressure of 80 mmHg. The central venous pressure was 2 cm H₂O. Only a few basilar rales were audible. Because of a low central venous pressure in the presence of arterial hypotension, a fluid load of 300 ml dextrose in water was administered over 15 minutes during continuous pressure monitoring. Central venous pressure rose to 4 cm H₂O, a protodiastolic gallop developed, and moderate dyspnoea ensued, without any change in arterial pressure. A catheter was inserted into the left ventricle and a pressure of 80/32-36 mmHg was obtained. Phlebotomy and diuresis resulted in a drop in left ventricular end-diastolic pressure to 11-13 mmHg and a rise in systolic pressure to 110 mmHg.

Comment Acute left ventricular failure secondary to myocardial infarction may occur rapidly in the presence of a normally functioning right ventricle. Central venous pressure monitoring in such a case may not reflect the level of left ventricular filling pressure.

Discussion

Left ventricular catheterization is assuming a role of increasing importance in clinical management of the acutely ill. Cohn *et al.* (1969) have recently demonstrated the feasibility of blind left ventricular catheterization in the critically ill. The size of the catheter

and the relative thrombogenicity of polyethylene, however, essentially preclude its use for long-term monitoring. The present report also indicates that catheterization of the left ventricle may be carried out without fluoroscopy with relative safety. Furthermore, this technique has the advantage that the catheter employed is small enough to be inserted from the brachial artery. This allows the patient greater leeway in activity and facilitates nursing care, while decreasing the risk and severity of thrombosis. For these reasons and because of the diminished thrombogenicity of Teflon, the catheter may be safely left in place for long periods.

The only major complication of this technique has been a fragmentation of a spring safety guide wire. This complication is extremely rare: a review of 12,367 cases for complications of cardiac catheterization (American Heart Association, 1968) documents only 5 such instances (0.04%). The temporal sequence of the single episode of ventricular tachycardia to ventricular catheterization suggests a causal relation. This relation to the ventricular catheterization was not established with certainty since other evidence of ventricular irritability due to the presence of the catheter was not demonstrated either before or after the arrhythmia. The single instance of ventricular tachycardia in this patient group corresponds to the incidence of spontaneous ventricular tachycardia occurring in patients with acute myocardial infarction (Bashour, Jones, and Edmonson, 1967; Stock, Goble, and Sloman, 1967; Mitra, 1969).

Though a major risk of left ventricular catheterization is that of peripheral embolization through external introduction of catheter clot or air bubbles, this complication was not observed either by Cohn or during the present study. To limit the development of thromboembolic complications, all patients with left ventricular catheters are anticoagulated with heparin unless absolutely contraindicated, and all physician, nursing, and technical personnel are specifically instructed in the technique and its inherent dangers.

Failure to enter the left ventricle occurred in 3 patients. In all, the guide wire would not traverse the femoral vessels into the descending aorta, and the brachial approach was not attempted. In a fourth patient, several unsuccessful attempts were made from the left brachial artery. After this, the left ventricle was entered via the transfemoral approach.

Since one of the important measurements obtained by left ventricular catheterization is the level of diastolic pressure within the ven-

tricle, it should be noted that such data are also available indirectly by measurement of the pulmonary artery diastolic or pulmonary capillary wedge pressures. An atraumatic flow-directed balloon catheter passed at the bedside without fluoroscopy has recently been developed at this institution for this purpose (Swan *et al.*, 1970). However, data relative to left ventricular function which may be derived from such pressures are limited. At present, therefore, we restrict left ventricular catheterization to the following circumstances: (a) for determination of left ventricular filling pressure in the critical management of fluid balance, when pulmonary capillary wedge pressure is technically unsatisfactory, or when chronic pulmonary disease renders pulmonary artery end-diastolic pressure invalid as an index of left ventricular diastolic pressure (Forrester *et al.*, 1970a), and (b) when specific diagnosis such as pulmonary embolus or pericardial tamponade is dependent on accurate knowledge of left ventricular diastolic pressure.

References

- American Heart Association (1968). Monograph Number Twenty. Cooperative study on Cardiac Catheterization. Ed. by E. Braunwald and H. J. C. Swan. [*Circulation*, 37, Suppl. No. 3.]
- Bashour, F. A., Jones, E., and Edmonson, R. (1967). Cardiac arrhythmias in acute myocardial infarction. II. Incidence of the common arrhythmias with special reference to ventricular tachycardia. *Diseases of the Chest*, 51, 520.
- Braunwald, E. (1969). The determinants of myocardial oxygen consumption. Thirteenth Bowditch Lecture. *Physiologist*, 12, 65.
- Cohn, J. N., Khatri, I. M., and Hamosh, P. (1970). Bedside catheterization of the left ventricle. *American Journal of Cardiology*, 25, 66.
- Cohn, J. N., Tristani, F. E., and Khatri, I. M. (1969). Studies in clinical shock and hypotension. VI. Relationship between left and right ventricular function. *Journal of Clinical Investigation*, 48, 2008.
- Enright, L. P., Hannah, H., III, and Reis, R. L. (1968). The effects of acute regional myocardial ischemia on left ventricular function. *Circulation*, 37 & 38, Suppl. VI, 72.
- Forrester, J., Diamond, G., Ganz, V., Danzig, R., and Swan, H. J. C. (1970a). Right and left heart pressures in the acutely ill patient. *Clinical Research*, 18, 306.
- Forrester, J., Diamond, G., McHugh, T., Wegner, S., Parmley, W. W., and Swan, H. J. C. (1970b). Acute myocardial infarction: Parameters of left ventricular function as prognostic indicators. *Circulation*, 42, 153.
- Hugenholtz, P. G., Ellison, R. C., Urschel, C. W., Mirsky, I., and Sonnenblick, E. H. (1970). Myocardial force-velocity relationships in clinical heart disease. *Circulation*, 41, 191.
- Kirby, B. J., McNicol, M. W., and Tattersfield, A. E. (1968). Left ventricular pressures in two patients with myocardial infarction. *Lancet*, 1, 944.

Mitra, B. (1969). Arrhythmias in myocardial infarction. *Geriatrics*, **24**, 155.

Stock, E., Goble, A., and Sloman, G. (1967). Assessment of arrhythmias in myocardial infarction. *British Medical Journal*, **2**, 719.

Swan, H. J. C., Ganz, W., Forrester, J., Marcus, H., Diamond, G., and Chonette, D. (1970). Catheterization of the heart in man with use of a flow-directed balloon-tipped catheter. *New England Journal of Medicine*, **283**, 447.