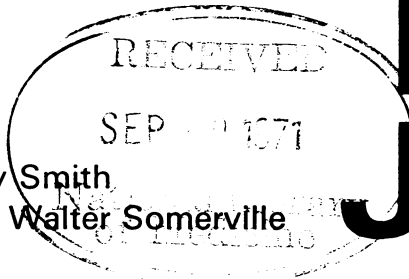


READING ROOM



# British Heart Journal

Editor K. Shirley Smith  
Assistant Editor Walter Somerville

Editorial: His bundle electrograms <i>Charles S. Smithen and Edgar Sowton</i>	633	Electroconversion of atrial fibrillation after mitral valvotomy <i>Adrian R. M. Upton and Michael Honey</i>	732
Sinus arrest in acute myocardial infarction <i>R. Rokseth and L. Hatle</i>	639	Atrial fibrillation in bacterial endocarditis <i>A. J. Eisinger</i>	739
Correlation of mortality rate and serum enzymes in myocardial infarction. Test of efficiency of coronary care <i>B. L. Chapman</i>	643	Sinus bradycardia <i>Dennis Eraut and David B. Shaw</i>	742
Bradycardia, increased cardiac output, and reversal of pulmonary hypertension in altitude natives living at sea level <i>F. Sime, D. Peñaloza, and L. Ruiz</i>	647	Traumatic tricuspid regurgitation. Long-term survival <i>M. S. Croxson, K. P. O'Brien, and J. B. Lowe</i>	750
Transseptal catheterization via right subclavian vein <i>E. J. Epstein and N. Coulshed</i>	658	Cardiac rehabilitation in Britain (1970) <i>B. M. Groden, T. Semple, and G. B. Shaw</i>	756
Unusual complications of bacterial endocarditis <i>P. N. Symbas, B. J. Baldwin, R. C. Schlant, and J. W. Hurst</i>	664	Electrocardiographic effects of isoprenaline in normal subjects and patients with coronary atherosclerosis <i>H. Wexler, J. Kuaity, and E. Simonson</i>	759
Analysis of symptomatic course and prognosis and treatment of hypertrophic obstructive cardiomyopathy <i>D. A. Swan, Barbara Bell, Celia M. Oakley, and J. Goodwin</i>	671	Systolic time interval fluctuations produced by acute myocardial infarction <i>J. T. Dowling, G. Sloman, and Cecily Urquhart</i>	765
Ultrasonic evaluation of anatomical abnormalities of heart in congenital and acquired heart diseases <i>M. Tanaka, T. Neyazaki, S. Kosaka, H. Sugi, S. Oka, T. Ebina, Y. Terasawa, K. Unno, and K. Nitta</i>	686	Mitral stenosis with left-to-right shunt at atrial level. A diagnostic challenge <i>R. Tandon, S. C. Manchanda, and S. B. Roy</i>	773
Persistent ductus arteriosus in Malaysian patients <i>M. Krishnan and M. R. J. Snelling</i>	699	Cardiomyopathy associated with congenital heart disease <i>A. Shem-Tov, V. Deutsch, J. H. Yahini, and H. N. Neufeld</i>	782
'Pixie' cardiography. Accelerometer applications to phonocardiography and displacement cardiography in childhood <i>F. E. Bew, D. Pickering, P. Sleight, and F. D. Stott</i>	702	Obituary: S. B. Boyd Campbell, M.C.	794
The praecordial honk <i>P. Rizzon, Giuseppina Biasco, and G. Maselli-Campagna</i>	707	Obituary: George Mason	795
Plasma free fatty acid and catecholamine levels in patients with acute myocardial infarction <i>W. Januszewicz, M. Sznajderman, M. Ciświcka-Sznajderman, B. Wocial, and Z. Rymaszewski</i>	716	Case Reports	
Measurements of sinus impulse conduction from electrogram of bundle of His <i>S. Bekheit, J. G. Murtagh, P. Morton, and E. Fletcher</i>	719	Myocardial infarction complicating a hydatidiform mole in a young woman <i>D. P. Atukorale and N. J. Wallooppillai</i>	796
Transposition of great arteries. A study of 65 infants followed for 1 to 4 years after balloon septostomy <i>C. G. Parsons, R. Astley, F. G. O. Burrows, and S. P. Singh</i>	725	Dysphagia due to left atrial enlargement after mitral Starr valve replacement <i>M. H. Chesshyre and M. V. Braimbridge</i>	799
		Profunda femoral arteriovenous fistula after percutaneous arterial and venous catheterization <i>U. Thadani and A. E. Pratt</i>	803
		Interrenal type of abdominal aortic coarctation with unusual complications <i>M. Janiček and O. Hollmotz</i>	806