

Right atrial myxoma and pulmonary embolism *Rational basis for investigation and treatment*

D J M KEENAN,* P MORTON, H O O'KANE

From The Cardiac Surgical Unit, the Royal Victoria Hospital and The Cardiology Department, the Belfast City Hospital, Belfast, Northern Ireland

SUMMARY We report a case in which pulmonary embolectomy was crucial in the successful outcome of an operation to remove a right sided atrial myxoma. The association between such myxomata and embolisation is emphasised and guidelines for the rational investigation and treatment of such lesions are given.

The occurrence of peripheral emboli is relatively common and well documented with left atrial myxoma,¹⁻³ and it is not surprising, therefore, that right atrial myxoma should give rise to pulmonary emboli.⁴ Indeed, the association of pulmonary emboli with right atrial myxoma has been recognised at necropsy for many years; Chiari⁵ reported the first case in 1931. The clinical recognition of this association, however, is less well documented^{4 6 7} and a search of the published reports discloses only two pulmonary embolectomy^{8 9} performed during an operation to remove a right sided myxoma, and in neither case was the outcome successful. We report here the successful removal of a right atrial myxoma in a case where pulmonary embolectomy was crucial.

Case report

A 52 year old housewife was admitted with sudden swelling of the right arm accompanied by a dull ache. She complained of increasing tiredness for the six months before admission, with progressive exertional dyspnoea for the last three weeks. Her ankles had been swollen for one week. She did not admit to pain at any site nor to haemoptysis. There was nothing relevant in the past history.

On admission the entire right arm was swollen from the shoulder girdle to the fingers with sparing of the lower neck. Superficial veins were not unduly prominent. The right arm felt firm but there was slight pitting on pressure. The radial pulse was present. There were no neurological abnormalities. The signs of

a mild degree of right sided cardiac failure were noted, with a jugular venous pressure of 4 cm of water and dependent oedema of both legs, but no ascites, sacral oedema, or hepatosplenomegaly. The pulse rate was 90 beats a minute. Blood pressure, measured in the left arm, was 140/90 mmHg. There were no cardiac murmurs at this stage, but just before operation a grade 2 midsystolic murmur was heard in the pulmonary area.

Chest radiography showed moderate cardiomegaly (cardiothoracic ratio of 155/280) without any specific chamber enlargement, while the electrocardiogram showed sinus rhythm with a Q wave in lead III and T wave inversion in the anterior chest leads.

A technetium-99mMAA venogram through a distal right arm vein showed an abnormality of flow in the right axillary vein, suggesting thrombosis, and a contrast venogram via the right median cubital vein confirmed thrombosis of the brachial and axillary veins, which extended as far as the superior vena cava. A pulmonary perfusion scan, using technetium-99mMAA, showed diminished flow to the entire left lung in keeping with massive pulmonary embolism, while flow to the right lung appeared normal. Echocardiography showed the presence of a large filling defect of the right atrium, prolapsing into the ventricle during diastole. Cardiac catheterisation was carried out via the left median basilic vein and the right femoral artery. The systolic pulmonary arterial pressure and the mean right atrial pressure were 15 and 14 mmHg, respectively. Contrast injection showed a large irregular filling defect occupying two thirds of the right atrium and prolapsing through the tricuspid valve. In addition, there was stagnation of blood flow in this area. A biopsy was taken using a "Biopptome" introduced via

*Present address: The Wessex Cardiothoracic Centre, The Western Hospital, Oakley Road, Southampton.

the right femoral vein. This confirmed the diagnosis of atrial myxoma.

Before operation, the patient was treated with an intravenous infusion of heparin, 40 000 IU a day, together with diuretics. On this, the swelling of the right arm subsided but the cardiac symptoms and signs persisted.

At operation, the right atrium was much enlarged and tense. The right ventricle was likewise enlarged and poorly contractile. The pulmonary artery was dilated and tense, while the left side of the heart appeared normal. Intracardiac pressure readings showed a moderate rise in the right ventricular systolic pressure (41 mmHg), a gross increase in the mean right atrial pressure (25 mmHg), but only a slightly raised left atrial pressure (9 mmHg). Ascending aortic and bicaval cannulations were carried out, great care being taken in the placement of the latter so as not to dislodge the tumour. The left ventricle was not vented. Hypothermic (18°C) cardiopulmonary bypass with cardioplegic arrest was used.

The right atrium was opened longitudinally and a large pedunculated myxoma, arising from the atrial septum, was found obstructing the tricuspid orifice. No thrombus was present on its surface. The myxoma (5 × 3.5 × 3.5 cm) and its base were excised. The left atrium was explored but no left sided extension was found. Both atria were closed and an attempt was made to discontinue cardiopulmonary bypass. This had to be reinstated because of right ventricular distension and conspicuous increase in right atrial pressure. A further attempt to discontinue bypass failed, despite the use of inotropic support. The pulmonary trunk was then opened longitudinally, and massive organised emboli (Fig.) sucked from both lungs, the right lung being

compressed directly to facilitate clearance. After this, cardiopulmonary bypass was discontinued using only minimal inotropic support. The mean right atrial pressure was now 12 mmHg.

The postoperative course was uneventful. Histological examination of the tumour confirmed the diagnosis of myxoma and disclosed that the pulmonary emboli consisted solely of organised thrombus with no admixture of tumour.

At review, eight months later, the patient was asymptomatic. The cardiothoracic ratio was normal, as was the electrocardiogram. Warfarin was the only drug being given.

Discussion

Atrial myxomata account for 50% of primary cardiac tumours¹⁰ and were first treated using cardiopulmonary bypass in 1954.¹¹ Right atrial myxomata account for 25% of all cardiac myxomata and generally present as right sided cardiac failure, with or without signs of tricuspid valve disease, pulmonary embolism, or constitutional illness.^{3 4 7}

The association between atrial myxomata and embolism is well recognised. This phenomenon is generally attributable to the exposed nature and constant agitation of the tumour which results in detachment of either fragments of the tumour or of the overlying thrombus. In the present case, however, on the basis of the cineangiographic appearances, the source of the thromboembolism was, most probably, the great veins. Embolism in the peripheral arterial system occasionally is the first indication of a left sided tumour.¹⁻³ It has been suggested^{6 12 13} that embolism from a right sided myxoma is less common, but it

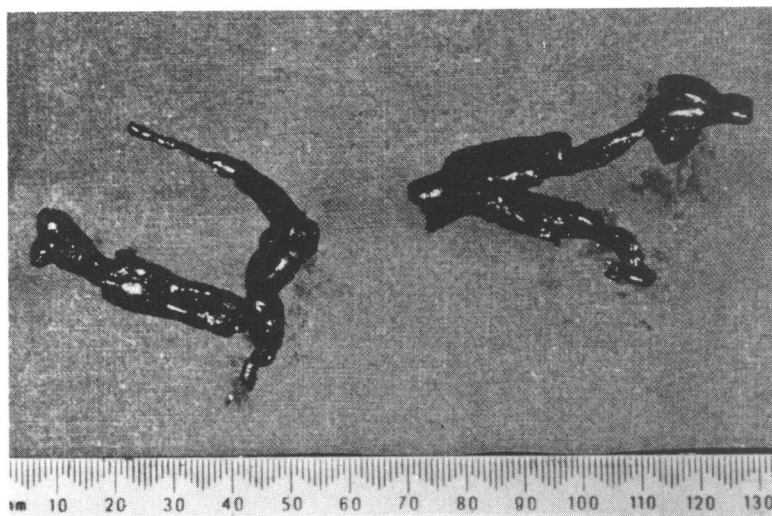


Fig. Pulmonary emboli removed at operation.

appears that the incidence is the same for both sides of the heart, considering the relative occurrence of the two tumours.¹⁰ Pulmonary embolism, however, is more likely to be asymptomatic, misdiagnosed, or diagnosed late than peripherally-sited emboli.^{4 12 14} Furthermore, while systemic arterial emboli in a young person, without bacterial endocarditis and in sinus rhythm, should make one suspect a left atrial myxoma, a similar relation between pulmonary emboli and right atrial myxoma, in those without predisposition to thromboembolism, should be remembered.

The present case appears to be the first to be reported where pulmonary embolectomy was instrumental in the successful outcome of an operation to remove a right sided atrial myxoma. The mode of presentation was also highly unusual, namely the sudden onset of swelling of the right arm caused by brachial and axillary vein thrombosis, which probably was the result of stasis, very poor blood flow having been noted in the right atrium and the superior vena cava at the time of cardiac catheterisation.

In view of the above observations, and as diagnostic techniques move away from angiography and towards echocardiography alone, it is recommended that in all cases of right atrial myxoma diagnosed by echocardiography, a radioisotope lung scan be performed. If emboli are present, an opinion can be formed before operation, on the basis of their sites and their extent, concerning the need for embolectomy. This may require modification in the light of intraoperative pressure recordings. When pulmonary arterial hypertension has supervened, embolectomy is mandatory.^{7 8 14}

In the present case, though it is apparent from the pulmonary perfusion scan that extensive pulmonary embolism to the left lung predated cardiac catheterisation by several days at least, further significant embolisation had occurred between carrying out the catheterisation study and operation, as evidenced by the subsequent rise in pulmonary arterial pressure. It is possible that there was further thromboembolism or that thrombus was dislodged at the time of operation, but the possibility remains that the act of catheterisation or biopsy was instrumental in dislodging thrombus. In view of the current degree of accuracy in diagnosing cardiac myxomata by echocardiography alone^{3 15 16} it may be argued that cardiac catheterisation and biopsy have little to add, and may be hazardous in certain cases.

References

- 1 Bulkley BH, Hutchins GM. Atrial myxomas: a fifty year review. *Am Heart J* 1979; **97**: 639-43.
- 2 St John Sutton MG, Mercier L-A, Giuliani ER, Lie JT. Atrial myxomas. A review of clinical experience in 40 patients. *Mayo Clin Proc* 1980; **55**: 371-6.
- 3 Anonymous. Atrial myxomas (Editorial). *Br Heart J* 1980; **281**: 1587-8.
- 4 Muroff LR, Johnson PM. Right atrial myxoma presenting as non-resolving pulmonary emboli: case report. *J Nucl Med* 1976; **17**: 890-2.
- 5 Chiari H. Myxom des rechten Vorhofs: plötzlicher Tod durch Geschwulstembolie der Lungenschlagader. *Zentralbl Allg Pathol* 1931; **52**: 241-6.
- 6 Barlow J, Fuller D, Denny M. A case of right atrial myxoma with special reference to an unusual phonocardiographic finding. *Br Heart J* 1962; **24**: 120-5.
- 7 Collins HA, Collins IS. Clinical experience with cardiac myxoma. *Ann Thorac Surg* 1972; **13**: 450-7.
- 8 Tai AR, Gross H, Siegelman SS. Right atrial myxoma and pulmonary hypertension. *NY State J Med* 1970; **70**: 2996-3000.
- 9 Saha SP, Arrants JE, Lee WH Jr. Atrial myxoma. Clinical manifestations and surgical treatment. *Int Surg* 1978; **63**: 180-2.
- 10 Prichard RW. Tumors of the heart. *Arch Pathol* 1951; **51**: 98-128.
- 11 Crafoord C. Discussion on late results of mitral commissurotomy. In: Lam CR ed. *International symposium of cardiovascular surgery*. Philadelphia: WB Saunders, 1955: 202-11.
- 12 Vidne B, Atsmon A, Aygen M, Levy MJ. Right atrial myxoma: case report and review of the literature. *Isr J Med Sci* 1971; **7**: 1196-200.
- 13 Attar S, Lee Y-C, Singleton R, Scherlis L, David R, McLaughlin JS. Cardiac myxoma. *Ann Thorac Surg* 1980; **29**: 397-405.
- 14 Heath D, MacKinnon J. Pulmonary hypertension due to myxoma of the right atrium. *Am Heart J* 1964; **68**: 227-35.
- 15 Stern MJ, Cohen MV, Fish B, Rosenthal R. Clinical presentation and non-invasive diagnosis of right heart masses. *Br Heart J* 1981; **46**: 552-8.
- 16 Perry LS, King JF, Zeff HJ, Manley JC, Gross CM, Wann LS. Two-dimensional echocardiography in the diagnosis of left atrial myxoma. *Br Heart J* 1981; **45**: 667-71.

Requests for reprints to Mr H O O'Kane, The Cardiac Surgical Unit, The Royal Victoria Hospital, Grosvenor Road, Belfast, Northern Ireland.