

Dehiscence of infected aortocoronary vein graft suture lines

Cause of late pseudoaneurysm of ascending aorta

PETER SMITH, SHAKEEL QURESHI, MAGDI H YACOB

From Harefield Hospital, Harefield, Middlesex

SUMMARY Two cases are described of late pseudoaneurysm of the ascending aorta caused by dehiscence of infected aortocoronary vein graft suture lines. Both cases were associated with early post-operative *Staphylococcus aureus* superficial wound infection. This complication should be suspected in patients developing protracted wound infections after operation, particularly when associated with rigors.

Dehiscence of an aortocoronary vein graft suture line after infection and producing a late pseudoaneurysm of the ascending aorta has not, to our knowledge, been described before. The purpose of this report is to describe two patients who developed this complication and to discuss its diagnosis, possible causes, and methods of treatment.

Case reports

CASE 1

A 41 year old man presented with angina of five years' duration, with recent deterioration. He was otherwise fit, with no previous serious illnesses. Cardiac catheterisation showed severe triple vessel disease, and coronary bypass grafting was recommended.

Preoperative haemoglobin, white blood count, serum urea and electrolytes, uric acid, and glucose levels were all normal. Swabs from the nose, throat, and perianal areas grew "normal" flora only. He underwent quadruple coronary artery bypass grafts to the left anterior descending, its diagonal branch, the first and second diagonal branches of the circumflex, and right coronary arteries. A three day course of flucloxacillin was given postoperatively, starting with the premedication.

Ten days after the operation the patient became pyrexial with a superficial wound breakdown and discharge. The white blood count was 21 000/mm³. *Staphylococcus aureus* was grown from the wound. He received a two week course of flucloxacillin, 500 mg four times daily, and the superficially opened wound was cleaned daily with Eusol. Blood cultures showed no growth. He was discharged two weeks after opera-

tion, afebrile with a normal white blood count and with a clean healing wound. Two short episodes of pyrexia and rigors occurred at six and 12 weeks post-operatively. These were treated successfully in the first instance by a two week course of flucloxacillin and in the second by a six month course of oral cephadrine.

He remained well and symptom free and underwent routine angiography again 18 months after operation which showed the grafts to the diagonal of the left anterior descending coronary artery, to the first and second diagonals of the circumflex coronary artery, and to the right coronary artery to be patent, but the graft to the left anterior descending coronary artery was occluded. Two large pseudoaneurysms could be seen originating from the ascending aorta (Fig. 1). The white blood cell count at this time was normal. At reoperation it was noted that the sternum and wound were well healed, with no signs of continuing infection. The patient was put on femoro-femoral cardiopulmonary bypass and cooled to 15°C. He then underwent a two minute period of total circulatory arrest while the sternum was opened and the aneurysms excised. The aortic defects were oversewn. Debris from the pseudoaneurysms grew *Staphylococcus aureus* and he was prescribed a three month course of flucloxacillin. The postoperative course was uneventful. There was no evidence of perioperative infarction. The patient was fit and well on discharge.

CASE 2

A 38 year old man presented with a six month history of progressively worsening angina. Cardiac catheterisation showed severe stenoses in the left anterior

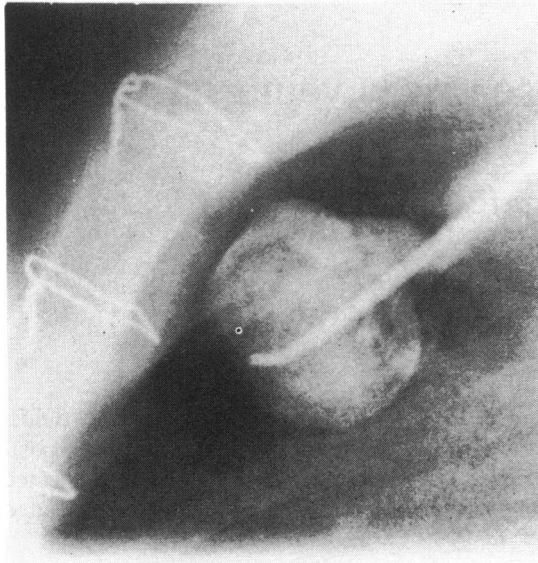


Fig. 1 One of the two similar pseudoaneurysms of the ascending aorta seen at angiography in case 1.

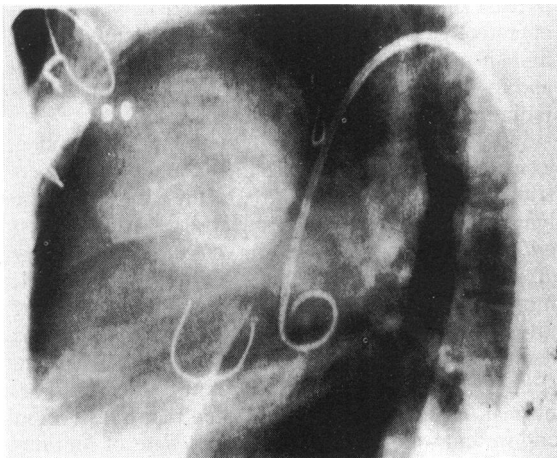


Fig. 2 The large pseudoaneurysm opacified by radiocontrast media in case 2. It can be seen lying directly posterior to the sternum, with the catheter posterior to it in the ascending aorta.

descending and right coronary arteries.

Preoperative haemoglobin, white blood count, serum urea and electrolytes, glucose, and uric acid levels were all normal but *Staphylococcus aureus* was grown from the nose swabs. Coronary artery grafting was performed to the left anterior descending and right coronary arteries. He received three days post-operative flucloxacillin and gentamycin starting with the premedication.

Three days after operation he became pyrexial. This, however, resolved spontaneously after 48 hours with no specific treatment and he was discharged well seven days later. Seventeen days after operation he again became pyrexial and his chest wound began to discharge. All swabs grew *Staphylococcus aureus* and he was prescribed a 14 day course of oral cephalixin. The superficially opened wound was cleaned with Eusol. The white blood count never rose above 7000/mm³. Six month follow up showed a completely healed wound and a well patient.

Nine years later the patient presented with a three month history of a painful non-pulsatile swelling at the top of his median sternotomy scar. The patient had been prescribed a course of tetracyclin before referral. The white blood count was normal. A small abscess was drained and a sternal wire from the base of the abscess removed.

In view of the possibility of mediastinal infection angiography was carried out again which showed a very large pseudoaneurysm of the ascending aorta (Fig. 2).

As a result of this finding the patient was operated on again. With femoro-femoral cardiopulmonary bypass and cooling to 14°C the patient's circulation was arrested for 10 minutes, the sternum was opened, and the pseudoaneurysm excised. No vegetations were noted on the aortic suture lines. The defect in the aorta was oversewn. *Staphylococcus aureus* was grown from cultures made from aneurysmal debris. Flucloxacillin was prescribed for three months, initially parenterally for three weeks and then orally.

Postoperatively, the patient sustained a right hemiparesis, possibly the result of a small intraoperative cerebral embolus. On discharge he was fit and well with minimal residual neurological deficit.

Discussion

To our knowledge, infected pseudoaneurysm formation at the aortic end of a coronary artery bypass graft has not been described in the English language publications. Several cases, however, have been described of pseudoaneurysm formation after infection and breakdown at an aortic cannulation site¹ and also at the left ventricular vent site, particularly after infection associated with the Teflon used to buttress the closing sutures.² Rupture of pseudoaneurysm at these sites is a recognised cause of death after coronary artery grafting.³ The cause of the pseudoaneurysm formation is usually infection. Both the cases described in our paper were associated with *Staphylococcus aureus* which was grown from the aneurysmal debris removed at operation. They had received treatment for superficial wound infections caused by *Staphylococcus aureus* a long time before the

Aortic pseudoaneurysm, coronary grafting

presentation with the pseudoaneurysm. Infection with gram-negative organisms has also been associated with pseudoaneurysm formation, notably at the left ventricular vent site.²

The diagnosis of a retrosternal aortic pseudoaneurysm rests on the findings at angiography. Clinically, the diagnosis should be suspected in all patients developing protracted wound infection, particularly when associated with rigors.

Untreated, the risks of this complication include uncontrolled infection, septicaemia, rupture, and myocardial ischaemia resulting from a compromised graft.⁴ It can also be speculated that emboli may be thrown off down the coronary vessels, producing myocardial infarction.

The operative technique of femoro-femoral cannulation, deep hypothermia, and short total circulatory arrest was found to be a safe and effective method of dealing with this complication which reduces the risks of associated rupture during sternal split.⁵ Repair of the aortic defect by direct suture rather than by patch grafting was favoured. If the debris removed at operation shows significant bacterial infection, as in our cases, a long course of antibiotics is recommended postoperatively.

Once diagnosis of a potentially infected pseudoaneurysm of the ascending aorta is made

angiographically, early operative intervention using the technique described can produce good early and late results.

References

- 1 Salama FD, Blesovsky A. Complications of cannulation of the ascending aorta for open heart surgery. *Thorax* 1970; 25: 604-7.
- 2 Love JW, Jahnke EJ, McFadden RB, *et al.* Left ventricular pseudoaneurysm secondary to infection after coronary bypass surgery. *Chest* 1981; 79: 100-2.
- 3 Keon WJ, Bédard P, Akyurekli Y, *et al.* Causes of death in aorto-pulmonary bypass surgery: experience with 1,000 patients. *Ann Thorac Surg* 1977; 23: 357-60.
- 4 Morissette M, Lemire J, Poirier N, Bettez P. False aneurysm of the ascending aorta presenting as an acute myocardial infarction: a late complication of aorto-coronary bypass. *Chest* 1981; 79: 591-2.
- 5 Lillehei CW, Todd DB Jr, Levy J, Ellis RJ. Partial cardiopulmonary bypass, hypothermia, and total circulatory arrest. A life saving technique for ruptured mycotic aortic aneurysms, ruptured left ventricle and other complicated cardiac pathology. *J Thorac Cardiovasc Surg* 1969; 58: 530-44.

Requests for reprints to Mr M H Yacoub, FRCS, Harefield Hospital, Harefield, Uxbridge, Middlesex UB9 6JH.