

# Amiodarone associated alveolitis and polyarthropathy *Treatment by plasma exchange*

D C RUSSELL, L PATON, A C DOUGLAS

*From the Department of Medicine and Blood Transfusion Service, Royal Infirmary, Edinburgh*

**SUMMARY** In a case of severe alveolitis and polyarthropathy occurring within two to five months of starting amiodarone treatment high plasma concentrations of immune complexes were found, suggesting a drug mediated hypersensitivity reaction. Initial symptomatic response followed high dosage corticosteroid and immunosuppressant treatment, but reduction in the dosage of corticosteroids was achieved only by successive plasma exchange with concomitant reduction in plasma concentrations of both amiodarone and immune complexes.

Amiodarone hydrochloride is an effective antiarrhythmic agent being used increasingly in Europe and the United States.<sup>1</sup> Adverse effects reported include corneal microdeposits, photosensitisation, skin discoloration, disorders of thyroid function, and peripheral neuropathy.<sup>2, 3</sup> More recently several cases of pneumonitis and pulmonary fibrosis have been reported with amiodarone treatment, which resolved after withdrawal of the drug and treatment with corticosteroids.<sup>4</sup> We report a case of severe acute alveolitis and polyarthropathy occurring within two months of starting amiodarone treatment, which required not only high dosage corticosteroid and immunosuppressant treatment but also successive plasma exchange to obtain symptomatic relief.

### Case report

A 57 year old woman with longstanding bronchiectasis presented in 1979 with palpitations and on 24 hour electrocardiogram monitoring had intermittent bradycardias and supraventricular tachycardias characteristic of the sick sinus syndrome. A demand Cardiac Pacemakers Inc programmable pacemaker was inserted, but symptomatic episodes of supraventricular tachycardia recurred over the next two years despite treatment with digoxin, metoprolol, and verapamil. In March 1982 amiodarone 200 mg three times daily was given in combination with digoxin 0.25 mg daily, and this resulted in immediate and successful control of the arrhythmias.

In early May 1982 she noticed increasing stiffness, pain, and swelling initially in the hands and later in

the knees, ankles, wrists, and elbows. By July her shoulders, neck, back, and hips were affected. Little relief was obtained after prescription of piroxicam or ketoprofen by her general practitioner, and increasing analgesic treatment was required. She also noted increasing dyspnoea on moderate exertion unrelated to any infective exacerbation of her bronchiectasis.

By August 1982 she was unable to walk, dress herself, or even rise from a chair on account of polyarthropathy and was admitted to hospital. Examination showed widespread joint involvement, and coarse crepitations were audible throughout the chest. The chest radiograph showed old right apical tuberculous changes and widespread infiltration in both lung fields. Two days later she developed severe anterior chest pain and became considerably dyspnoeic.

On examination she was dyspnoeic, peripherally vasoconstricted, and centrally cyanosed. There was no finger clubbing. The pulse rate was 75 beats/minute and regular with intermittent ventricular premature beats, blood pressure was 125/70 mmHg, and the heart sounds were normal. There were additional crepitations in both lung fields to those previously noted in association with her bronchiectasis.

The electrocardiogram showed sinus rhythm, occasional ventricular ectopic beats, and inferolateral T wave changes but no evidence of acute myocardial infarction or ischaemia. The chest radiograph (Fig. 1a) showed widespread fluffy opacities in both lung fields consistent with severe alveolitis. Haemoglobin concentration was 11.2 g/dl; white cell count  $20.9 \times 10^9/l$  (83% neutrophils); erythrocyte sedimentation rate 118 mm in the first hour; and blood urea

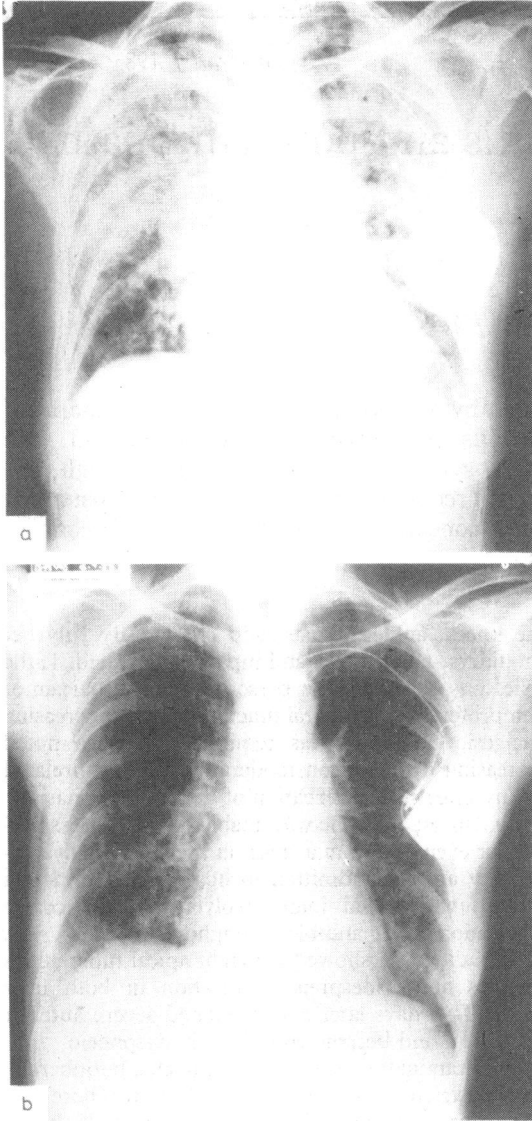


Fig. 1 Chest radiographs (a) on the day of stopping amiodarone and (b) one month later. Note the considerable clearing of pulmonary opacities after withdrawal of amiodarone and treatment with corticosteroids, azathioprine, and plasma exchange.

concentration 8.2 mmol/l (49 mg/100 ml). Arterial oxygen tension breathing room air was 5.3 kPa (40 mmHg) and carbon dioxide tension 5.2 kPa (39 mmHg). No pathogens were grown on sputum culture, and film and subsequent cultures for *Mycobacterium tuberculosis* were negative. Tests for avian and aspergillus precipitins were negative, as were investigations for antinuclear factor, lupus

erythematosus cells, DNA binding, autoantibodies, rheumatoid factor, and complement. Initially IgG (13.7 g/l), IgA (6.2 g/l), and IgM (2.9 g/l) concentrations were slightly increased, although subsequently these returned to within the normal range. Urine analysis showed no blood or protein.

An acute connective tissue disorder with severe alveolitis possibly induced by amiodarone was diagnosed. The drug was stopped, and prednisolone 60 mg daily was started together with antituberculous cover with ethambutol 800 mg and rifampicin 300 mg and isoniazid 150 mg (Rimactazid 300) twice daily. Rapid initial symptomatic recovery ensued with considerable improvement in dyspnoea and almost complete subsidence of joint pain. Considerable radiographic clearing of the pulmonary opacities occurred within three days.

Attempts to reduce the dosage of prednisolone over the next week to below 50 mg daily were unsuccessful because of recurrence of arthropathy in the hands and

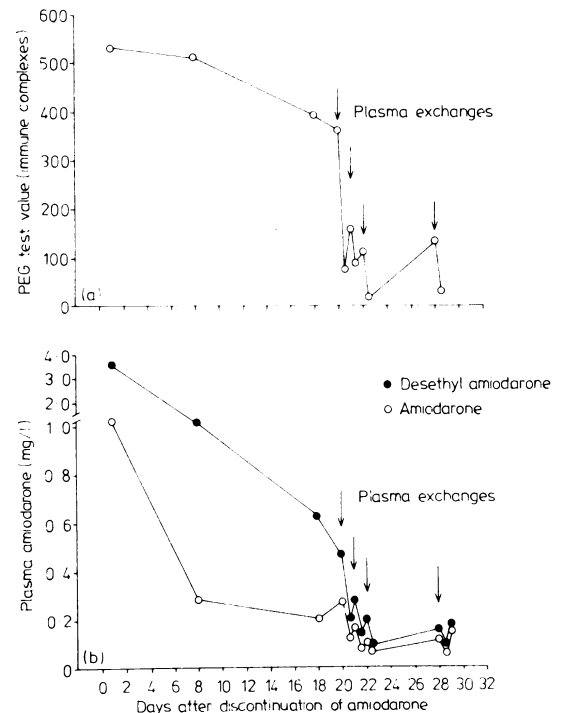


Fig. 2 Immune complex values (a) and plasma concentrations of amiodarone and desethylamiodarone (b) during the month after stopping amiodarone. Arrows indicate times of plasma exchanges. Note the fall in both immune complex values and drug concentrations after each plasma exchange. Polyethylene glycol (PEG) test values refer to extinction at 450 nm of samples containing polyethylene glycol expressed as a percentage against corresponding blanks.

knees and worsening dyspnoea. Addition of azathioprine 50 mg three times daily provided little additional benefit. In view of the possible role of immune complex formation in this condition and the extremely tight tissue binding and long plasma half life of amiodarone, plasma exchange was instituted on five occasions over the next month using a Haemanetics 30 S intermittent flow blood cell separator with vein to vein circuit via antecubital veins from both arms. Between 2.0 and 2.8 l of plasma was effectively removed during each plasma exchange procedure and was replaced by an equal volume of plasma protein solution. The procedure was well tolerated and no adverse reactions ensued. Appreciable symptomatic improvement resulted within 48 hours of each procedure, and progressive reduction in prednisolone dosage down to 20 mg daily was possible over eight weeks. The white blood count fell to  $10.3 \times 10^9/l$  and the erythrocyte sedimentation rate to 32 mm in the first hour. The chest radiograph (Fig. 1b) showed complete clearing of pulmonary infiltration.

Serial plasma concentrations of immune complexes were assessed by the polyethylene glycol test,<sup>5</sup> and plasma concentrations of amiodarone and its major metabolite, desethylamiodarone, were obtained before and after each plasma exchange (Fig. 2). On the day after amiodarone treatment was stopped the plasma concentration of amiodarone was lower and that of the metabolite higher than predicted from prior dosage. Immune complex values at this time were raised at 537% (normal range up to 150%).

During the next two weeks plasma concentrations of amiodarone and desethylamiodarone decreased but remained detectable. Immune complex values also fell over this period but remained raised at 365% before the first plasma exchange. Initial plasma exchange reduced detectable immune complex values to 74%, within the normal range, and also further reduced plasma concentrations of amiodarone and desethylamiodarone. The next day, however, both immune complex values and plasma drug concentrations were again raised, although not to pretreatment values. Successive plasma exchanges on each occasion resulted in reductions in both immune complex values and plasma drug concentrations, which remained detectable.

## Discussion

Pulmonary infiltration, hypersensitivity pneumonitis, and fibrosing alveolitis associated with amiodarone have been reported.<sup>2,3,4,6</sup> Symptoms usually appear within two to four months after the onset of treatment. Direct evidence implicating amiodarone, however, remains circumstantial. Both symptoms and radiographic abnormalities resolved after withdrawal

of the drug and corticosteroid treatment but only after some months. An association with polyarthropathy has not to our knowledge been previously described.

The time relation of events in our case strongly suggests a relation between amiodarone and the development of both polyarthropathy and alveolitis. Symptoms developed six to eight weeks after starting treatment with amiodarone 600 mg daily and progressively worsened over the next three to four months. The cumulative dose of amiodarone was 79.6 g which is within the same range (15–142 g) as that in Sobol's and Rakita's series of six patients with pulmonary fibrosis associated with amiodarone.<sup>4</sup> The patient was not receiving any other drug known to be associated with pulmonary fibrosis or polyarthropathy. The negative antinuclear factor, lupus erythematosus cells, and complement screen would make the diagnosis of an active primary connective tissue disorder unlikely. The absence of proteinuria and microscopic haematuria and any renal involvement is consistent with a drug mediated reaction. Eosinophilia was not present, excluding the possibility of pulmonary infiltration with eosinophilia.

Further indirect support for an association with amiodarone comes from the rapid resolution of symptoms and radiological resolution after high dosage corticosteroid treatment. It is of interest that the plasma half life of amiodarone is extremely long—about 30 days—and tissue binding of the drug is avid. Appreciable plasma concentrations of amiodarone may be detected up to 18 months after stopping treatment.

If a drug mediated hypersensitivity reaction is implicated then this could be mediated, as with other agents, by a hapten linked type III immune reaction with immune complex formation. The prolonged clinical course and high corticosteroid requirements might be explained therefore by the continued presence of the drug. Some additional increase in corticosteroid requirements may have resulted from concomitant treatment with rifampicin, which may reduce prednisolone bioavailability.<sup>7</sup> At the high corticosteroid dosages used, however, this effect is unlikely to have had clinical significance. An additional factor might be the presence of pre-existing lung disease in the form of bronchiectasis, which may predispose to pulmonary complications of amiodarone.<sup>2</sup> Such studies were uncontrolled, however, and require confirmation.

Appreciable plasma concentrations of amiodarone were found in our patient after stopping treatment and a further small reduction in plasma concentration was achieved after each plasma exchange. Presumably as a result of re-equilibration with tissue bound drug, however, plasma concentrations quickly reverted to their original value. None the less, plasma exchange resulted in definite subjective symptomatic improve-

ment and enabled successful reduction in prednisolone dosage. This beneficial effect may be related to the associated removal of immune complexes, which may be initiating the inflammatory reaction.

Furthermore, desethylamiodarone, the major metabolite of amiodarone, may be more active in inducing immune reactions than the parent drug. High concentrations of the metabolite were found before plasma exchange in our patient—higher than those predicted from prior dosage, higher in proportion to the parent drug than usually found, and with a faster elimination of both compounds than noted in other patients<sup>8</sup>—suggesting that amiodarone metabolism was accelerated in this patient. Reanalysis of plasma samples confirmed these findings and showed no evidence of interference by another drug or endogenous substance. Plasma exchange again might be expected to remove immune complexes linked to this metabolite.

This case should alert doctors to the possibility that severe connective tissue disorders occur with amiodarone treatment, even in low dosage, and that a protracted clinical course may result perhaps in relation to the long half life of the drug in tissue. Our patient required not only high dosage corticosteroids but also immunosuppressant treatment and sequential plasma exchange before her symptoms were brought under control. Further research into the mechanisms of this idiosyncratic reaction is required and in particular into the possible role of the major metabolite of amiodarone.

We thank Dr F E Boulton, Blood Transfusion Service, Royal Infirmary, Edinburgh, for advice on the management of this case, Labaz Laboratories, and Dr

D Holt, Guy's Hospital, London, for arranging analyses of plasma amiodarone concentrations.

#### References

- 1 Heger JJ, Prystowsky EN, Jackman WM, *et al.* Amiodarone: clinical efficacy and electrophysiology during long-term therapy for recurrent ventricular tachycardia or ventricular fibrillation. *N Engl J Med* 1981; **305**: 539–45.
- 2 Greene HL, Graham EL, Sears GK, Gross BW, Werner JA, Gorham JR. Extracardiac effects of amiodarone therapy [Abstract]. *Circulation* 1982; **66** (suppl): 224.
- 3 Harris L, McKenna WJ, Rowland E, Holt DW, Storey GCA, Krikler DM. Side effects of long-term amiodarone therapy. *Circulation* 1983; **67**: 45–51.
- 4 Sobol SM, Rakita L. Pneumonitis and pulmonary fibrosis associated with amiodarone treatment: a possible complication of a new antiarrhythmic drug. *Circulation* 1982; **65**: 819–24.
- 5 Kilpatrick DC, Weston J, Irvine WJ. Some studies on the polyethylene glycol turbidity method for detecting immune complexes in serum. *Ann Clin Biochem* 1981; **18**: 373–7.
- 6 Rotmensch HH, Liron M, Tupilski M, Laniado S. Possible association of pneumonitis with amiodarone therapy [Letter]. *Am Heart J* 1980; **100**: 412–3.
- 7 McAllister WAC, Thompson PJ, Al-Habet S, Rogers HJ. Adverse effects of refampicin on prednisolone disposition [Abstract]. *Thorax* 1982; **37**: 792.
- 8 Holt DW, Storey GCA. Amiodarone pharmacokinetics. In: Breithardt G, Loogan F, eds. *New aspects in the medical treatment of tachyarrhythmias*. Baltimore: Urban and Schwarzenberg, 1983: 69–73.

Requests for reprints to Dr D C Russell, Department of Medicine, The Royal Infirmary, Edinburgh EH3 9YW.