

# Inferior cardiac aneurysm involving the interventricular septum

## *A complication of an acquired ventricular septal defect*

JEFFREY M THEAKER

*From the Nuffield Department of Pathology, John Radcliffe Hospital, Oxford*

**SUMMARY** An acquired ventricular septal defect led to the formation of an unusual aneurysm within and overlying the posteroinferior part of the interventricular septum. This is a rare complication of a myocardial infarction and may not have been reported before. The aneurysm probably developed because of a combination of the anatomical localisation of the small ventricular septal defect and the long survival of the patient after its formation.

Rupture of the interventricular septum and formation of an aneurysm are both well recognised complications of myocardial infarction. I report a case in which an acquired ventricular septal defect following an inferior myocardial infarction was complicated by the formation of a cystic dilatation within the posteroinferior part of the interventricular septum and the overlying inferior wall of the heart.

### Case report

#### CLINICAL HISTORY

An 84 year old woman presented in 1983 with a four hour history of severe central chest pain associated with prolonged shortness of breath and vomiting on the day before admission. Examination showed severe left ventricular failure with a blood pressure of 110/70 mm Hg and a sinus tachycardia of between 100 and 120 beats/min. There was a precordial systolic thrill and a loud widespread pansystolic murmur. Despite diuretic treatment and a dopamine infusion her condition deteriorated, and she died shortly after admission.

In 1968 hypertension had been noted when she presented with angina, and this had been controlled medically. In 1972 she had an inferior myocardial infarction which was complicated by the appearance of a loud pansystolic murmur and left ventricular failure. Subsequent cardiac catheterisation showed a ventricu-

lar septal defect. She made a slow but uncomplicated recovery after treatment with bed rest, digoxin, and diuretics and ultimately returned to an active life including regular cycling. She remained generally well over the intervening 10½ years with only a couple of episodes of further acute ventricular failure. These occurred when she stopped taking diuretics because of the development of gout.

#### NECROPSY FINDINGS

At necropsy the heart was enlarged with both left and right ventricular hypertrophy (total weight 632 g). There was extensive acute anterior myocardial infarction involving the free wall of the left ventricle and, although no coronary artery thrombosis was found, all the major arteries were severely affected by calcifying atherosclerosis causing stenoses of 85% in many places. Moderately severe calcific aortic valve disease was also present.

There was a thin walled saccular aneurysm measuring 5 cm in diameter involving the inferior wall of the heart overlying the interventricular septum. This aneurysm contained no thrombus, was smooth walled interiorly, and communicated with both left and right ventricular cavities by separate orifices 3 cm apart. These both measured 0.75 cm in diameter and had a smooth rounded outline surrounded by white fibrous tissue. The free walls of both left and right ventricles showed no thinning or involvement in the aneurysm (Figs. 1 and 2).

Histological examination confirmed the presence of an acute myocardial infarct and showed that the tissue from around the ventricular septal defect and the free

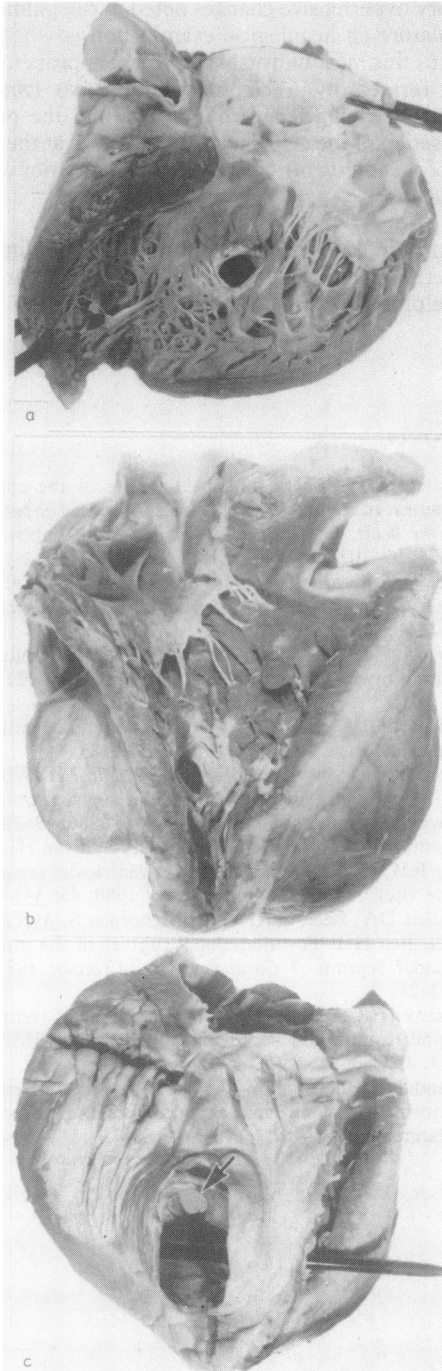


Fig. 1 Gross specimen of the heart: (a) the interior view of the left ventricle, (b) the interior view of the right ventricle showing the inferior cardiac aneurysm, and (c) the posteroinferior view with the roof of the aneurysm removed; the arrow shows the entry point to the left ventricle and the probe penetrates through the entry point to the right ventricle.

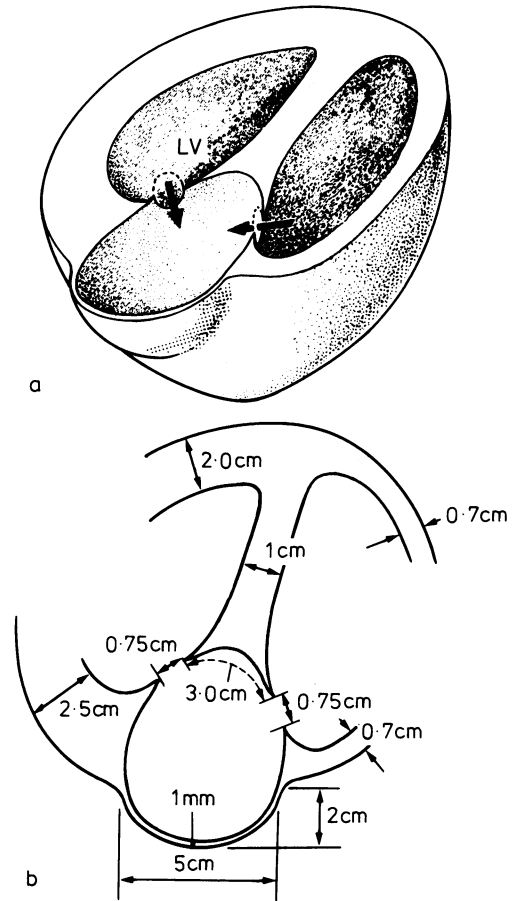


Fig. 2 (a) Diagrammatic representation of the heart and (b) transverse cross section through the aneurysm. LV, left ventricle.

external wall of the aneurysm consisted of fibrous scar tissue with surviving islands of myocardial fibres, consistent with a healed myocardial infarct. Assessment of the pulmonary vasculature showed evidence of pulmonary hypertension with medial hypertrophy and intimal fibrosis.

### Discussion

Ventricular septal defects after myocardial necrosis and rupture are seen in 1–2.5% of cases of acute myocardial infarction at necropsy.<sup>1,2</sup> They most commonly occur in the lower part of the interventricular septum and in one review of published reports were located in the posterior part in 17% of all cases.<sup>3</sup> The prognosis in unoperated cases is poor with reports of 24% mortality after 24 hours and of 81.5% at eight weeks,<sup>4</sup> although these figures represent

cumulative experience up to 1961. Since this time medical treatment has become more sophisticated, and surgical repair, where available and possible, has become the recommended management. Despite this, many patients still die in the early period following rupture with an overall mortality within the first month of approximately 50–60%,<sup>5,6</sup> with many of these deaths occurring before surgical intervention. Should surgery be successful, however, then the quality and quantity of life can be good with survival measured in terms of years for most patients.<sup>6,7</sup>

Ventricular aneurysms are seen more commonly than ventricular septal defects as complications of myocardial infarcts and are considered to be caused by stretching of a thinned fibrotic heart wall. It is not surprising that these two complications should coexist, since a single significant coronary artery lesion may give rise to both, and in one series left ventricular aneurysms were found in 37.5% of cases undergoing repair of postinfarction ventricular septal defects.<sup>8</sup> The present case, however, is distinct from these, as this patient's aneurysm was not one of either the left or the right ventricle but consisted of a cystic dilatation of the posteroinferior part of the interventricular septum.

The formation of the aneurysm was probably related to her long survival after the development of the ventricular septal defect, and her 10.5 years approaches the 13 years that represents the longest recorded survival.<sup>9</sup> This long period allowed stretching of the surrounding healed infarct at the intersection of the ventricular septal defect and the inferior wall of the heart to form the aneurysm, and there was consequent separation of the two entry points of the defect. That it was a true and not a false aneurysm is shown by the residual myocardial fibres within its free posterior wall. It is of interest that the catheter studies, performed approximately two weeks after the original infarct and 10 days after the pansystolic murmur was first noted, showed a ventricular septal defect alone with no evidence of an aneurysm. A significant left to right shunt was present as shown by the right ventricular hypertrophy and grade III pul-

monary hypertensive changes noted in the pulmonary vasculature on histological examination.

Thus this most unusual heart lesion appears to have been formed by a combination of two factors—namely, the long length of survival and the precise localisation of the ventricular septal defect at the junction of the interventricular septum and inferior wall of the heart.

I thank Professor P Sleight and Dr J G G Ledingham for permission to report this case and Dr D Tarin for his helpful comments.

#### References

- 1 Davies MJ, Robertson WB. Diseases of the coronary arteries. In: Pomerance A, Davies MJ, eds. *The pathology of the heart*. Oxford: Blackwell Scientific Publications, 1975: 99–102.
- 2 Lee WY, Cardon L, Slodki SJ. Perforation of infarcted interventricular septum. *Arch Intern Med* 1962; 109: 731–41.
- 3 Swithinbank JM. Perforation of the interventricular septum in myocardial infarction. *Br Heart J* 1959; 21: 562–6.
- 4 Barnard PM, Kennedy JH. Postinfarction ventricular septal defect. *Circulation* 1965; 32: 76–83.
- 5 Forfar JC, Irving JB, Miller HC, Kitchin AH, Wheatley DJ. The management of ventricular septal rupture following myocardial infarction. *Q J Med* 1980; 49: 205–17.
- 6 Montoya A, McKeever L, Scanlon P, Sullivan HJ, Gunnar RM, Pifarre R. Early repair of ventricular septal rupture after infarction. *Am J Cardiol* 1980; 45: 345–8.
- 7 Killen DA, Reed WA, Wathanachoroen S, McCallister BD, Bell HH. Postinfarctional rupture of the interventricular septum. *J Cardiovasc Surg (Torino)* 1981; 22: 113–26.
- 8 Daicoff GR, Rhodes ML. Surgical repair of ventricular septal rupture and ventricular aneurysm. *JAMA* 1968; 203: 457–60.
- 9 Landale DG, Schlappi JC. Thirteen year survival with acquired interventricular septal defect after myocardial infarction. *Am Heart J* 1962; 64: 33–7.