

# Continuous wave Doppler velocimetry as an adjunct to cross sectional echocardiography in the diagnosis of critical left heart obstruction in neonates

PETER J ROBINSON, RICHARD K H WYSE, JOHN E DEANFIELD, RODNEY FRANKLIN, FERGUS J MACARTNEY

*From the Department of Paediatric Cardiology, Hospital for Sick Children, London*

**SUMMARY** If cross sectional echocardiography in isolation is used to diagnose critical left ventricular outflow obstruction in neonates, false positive and false negative diagnoses may result. Continuous wave Doppler velocimetry was used to measure blood flow velocity in the ascending and descending thoracic aorta in six neonates (aged <6 weeks) presenting with reduced or absent peripheral pulses in order to determine the important sites of obstruction. This technique demonstrated abnormal high velocity blood flow jets (three times higher than normal) in the ascending aorta in three patients with normal descending aortic flow velocity, suggesting aortic stenosis. In the other three patients velocity in the ascending aorta was normal but high in the descending aorta, suggesting coarctation. The Doppler diagnosis was confirmed in the five patients who required surgery. Two patients had residual high velocity jets after aortic valvotomy. Both had significant pressure gradients across the aortic valve at cardiac catheterisation with good agreement between actual gradients and those predicted by the Doppler technique. Thus a combined anatomical and physiological approach using cross sectional echocardiography and continuous wave Doppler velocimetry enables accurate non-invasive definition of the site of left ventricular outflow obstruction and may obviate the need for invasive investigation in these sick neonates.

Critically ill neonates may undergo surgery for lesions causing obstruction to left ventricular outflow on the basis of clinical and cross sectional echocardiographic findings, thus avoiding the risks of cardiac catheterisation and angiocardiography.<sup>1</sup> Cross sectional echocardiography gives excellent imaging of intracardiac structures and the aortic arch but provides no physiological information on the degree of obstruction to flow. Furthermore, if cross sectional echocardiographic appearances alone are considered false positive and false negative diagnoses are possible.<sup>1</sup>

Doppler velocimetry can measure blood flow velocity, which has been shown to correlate well with the pressure drop across obstructive lesions in the circulation<sup>2,3</sup> in older patients, but this technique has not been used in neonates.

Requests for reprints to Professor F J Macartney, Hospital for Sick Children, Great Ormond Street, London WC1N 3JH.

Accepted for publication 12 July 1984

This study was therefore performed to determine whether the combined use of continuous wave Doppler velocimetry and cross sectional echocardiography could provide more objective and reliable non-invasive information on the site and severity of obstruction to left ventricular output in neonates presenting with reduced peripheral pulses.

## Patients and methods

We studied six neonates (four male, two female, aged 1.5-49 (mean 19) days) who presented with reduced or absent peripheral pulses. Each had a detailed physical examination including measurement of blood pressure in both upper and lower limbs with a Dynamap automated oscillometer.<sup>4,5</sup> They also underwent standard 12 lead electrocardiography, chest radiography, cross sectional echocardiography, and measurement of peak blood flow velocity in the ascending and descending aorta by continuous wave Doppler velocimetry.

Cross sectional echocardiograms were performed using an Advanced Technology Laboratory Mark 5 mechanical scanner with a 3.0 or 5.0 MHz transducer. Peak blood flow velocity was measured using the continuous wave mode of an ALFRED Doppler velocimeter ( Vingmed A/S, Norway) with a 2 MHz transducer which had a 45° angled head. This transducer shape greatly facilitated the use of the suprasternal window in these small patients. The machine has a digital display maximum frequency estimator which gives a value for peak blood flow velocity for each cardiac cycle. In two patients a spectral analyser was available to assess the quality of the waveform obtained, and in the remainder the audio signal alone was used to find the highest velocity present.

Flow in the ascending aorta was analysed by placing the transducer in the suprasternal notch and, if necessary, the right subclavian region with the patient supine and the neck extended. The ultrasound beam was aimed towards the heart, slightly anterior to the frontal plane, and then moved leftward or rightward in small sweeps until valve closure sounds could be heard. The search was then concentrated in that area to find the highest velocity jet. The highest reproducible velocity from the direct readout on the ALFRED machine, which was associated with a clean high frequency sound, was taken as the maximum velocity in the ascending aorta. The audio signal was found to be as reliable as, and more convenient than, the spectral

analyser in locating the highest velocity. For measuring descending aortic flow from the suprasternal notch approach the ultrasound beam was aimed approximately 20–30° posteriorly from the frontal plane and then slightly leftward from the saggital plane, searching as described above.

A predicted pressure gradient was calculated from Doppler velocity measurements. We used the modified Bernoulli equation:  $P=4V^2$ , where P is the pressure gradient (mm Hg) and V the peak velocity (m/s) distal to the stenosis.<sup>6</sup> No correction for angle of incidence was made. No patient was receiving a prostaglandin infusion at the time of the Doppler study.

Three patients underwent cardiac catheterisation, the patient in case 1 preoperatively, those in cases 4 and 5 before their second aortic valvotomy, and that in case 5 again after the repeat valvotomy.

**Results**

CLINICAL FINDINGS (TABLE)

Five patients were severely symptomatic and underwent surgery within 48 hours of admission. The patient in case 6 was asymptomatic and has not yet undergone surgery.

The three patients with coarctation had normal brachial pulses; of these, two had absent femoral pulses and one (case 1) variable femoral pulses. All three patients with aortic stenosis had symmetrically

Table Clinical and echocardiographic data and results of Doppler velocimetry in six neonates

Case	Age	Weight (kg)	Right brachial pulse	Femoral pulse	ECG findings	Cross sectional echocardiographic findings	Ascending aorta		Descending aorta		Final diagnosis		
							Peak BFV (ms)	Pressure gradient (mm Hg)	Peak BFV (ms)	Pressure gradient (mm Hg)			
								P	M	P		M	
	8 d	2.6 kg	Normal	Variable, RVH		AV thickened, LV function normal, PDA	1.1	N	—	3.0	36	0–20	Coarctation
	7 w	2.8 kg	Normal	Absent RVH		AV thickened, LV function normal, coarctation	1.3	N	—	3.4	46	75	Coarctation
	6 w	3.3 kg	Normal	Absent RVH		AV thickened, LV function normal, PDA, coarctation	1.2	N	—	3.6	52	50	Coarctation
}	5 d	3.1 kg	Reduced	Reduced RVH		AV thickened, LV dysfunction, PDA	3.3	44	—	1.1	N	—	Aortic stenosis
	6 w	3.1 kg	Reduced	Reduced LVH		AV thickened, LV function normal, LVH	3.8	58	60	0.8	N	—	Aortic stenosis
}	1½ d	3.1 kg	Reduced	Reduced LVH		AV very thickened, LV dysfunction, PDA	3.6	52	—	1.3	N	—	Aortic stenosis
	2½ w	3.0 kg	Normal	Normal LVH		AV thickened, LV dysfunction, LVH (severe)	3.8	58	68	—	N	—	Aortic stenosis
	6 w	3.0 kg	Normal	Normal LVH		AV thickened, LV dysfunction, LVH (severe)	4.4	77	80	—	N	—	Aortic stenosis
	7 d	3.0 kg	Reduced	Reduced Normal		AV thickened, LV function normal, PDA	3.75	56	—	1.2	N	—	Aortic stenosis

VH, right ventricular hypertrophy; LVH, left ventricular hypertrophy; AV, aortic valve; PDA, persistent ductus arteriosus; BFV, blood flow velocity; P, predicted; M, measured; N, normal.

Investigations repeated before second valvotomy.

Investigations repeated before and after second valvotomy.

reduced peripheral pulses. All but one (case 6) had cardiomegaly on a chest radiograph.

Right ventricular hypertrophy was present on the electrocardiogram in the three patients with coarctation and in one with aortic stenosis. One of the remaining patients had left ventricular hypertrophy, and the other a normal trace. Both patients with residual aortic stenosis and also the one (case 6) who had not had surgery showed left ventricular hypertrophy on follow up electrocardiograms.

#### CROSS SECTIONAL ECHOCARDIOGRAPHIC APPEARANCES (TABLE)

Thickening of the aortic valve was present in all six patients and was severe in two (cases 5 and 6). This was correctly considered to be the main lesion, and coarctation was excluded in all three patients with aortic stenosis. Coarctation of the thoracic aorta was diagnosed in the patients in cases 2 and 3, but in that in case 1 views of the aortic arch showed only isthmal hypoplasia, as well as a persistent ductus arteriosus, and the coarctation was not seen. Other echocardiographic features included pronounced right ventricular enlargement in four patients (cases 1-4) and appreciably reduced left ventricular function in two (cases 4 and 5).

#### DOPPLER VELOCIMETRY

Reproducible peak blood flow velocity measurements

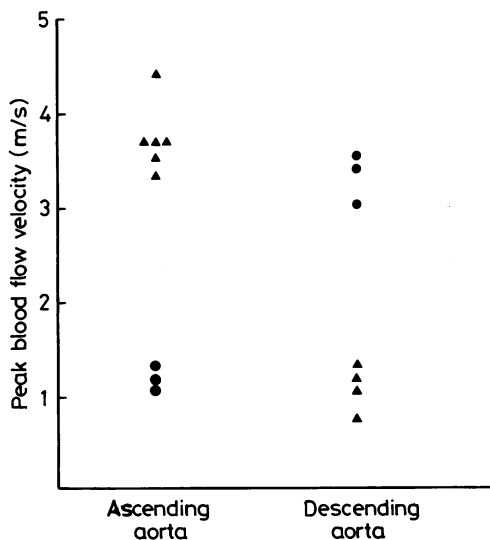


Fig. 1 Peak blood flow velocity in the ascending and descending aorta as measured with the ALFRED velocimeter in neonates with aortic stenosis (▲) and coarctation (●).

could be obtained from the ascending and descending aorta in all six patients. In the ascending aorta these ranged from 1.1 m/s to 3.8 m/s and in the descending aorta from 0.8 m/s to 3.6 m/s (Fig. 1). All three patients with a clinical diagnosis of aortic stenosis had appreciably increased peak blood flow velocities in the ascending aorta and normal velocities in the descending aorta. Two of these had surgical confirmation of the diagnosis. Doppler velocimetry showed appreciably increased blood flow velocity in the descending aorta and near normal values in the ascending aorta in all three patients with coarctation. Two patients (cases 2 and 3) had firm non-invasive diagnoses of coarctation and underwent surgery without cardiac catheterisation. In the patient in case 1 cardiac catheterisation was performed because there were equal blood pressures in the upper and lower limbs and cross sectional echocardiography was inconclusive.

The preoperative blood pressure recordings from the upper and lower limbs in all patients and the gradient across the coarctation measured at cardiac catheterisation in one patient were compared with Doppler predicted gradients (Fig. 2). In the patient in case 1 the Doppler technique correctly predicted a coarctation of the thoracic aorta despite equal Dynamap pressures in the upper and lower limbs. In the patient in case 2 severe coarctation was again diagnosed by Doppler velocimetry, but the gradient was underestimated. In the patient in case 3, the

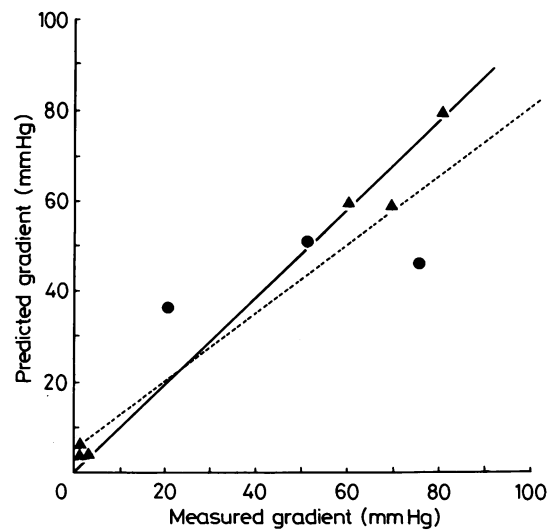


Fig. 2 Correlation between predicted and measured pressure gradients in neonates with aortic stenosis (▲) and coarctation (●). The dotted line is the line of best fit ( $r=0.94$ ,  $p<0.001$ ) and the solid line the line of identity.

Doppler predicted gradient correlated more closely with that found by cuff pressures.

#### POSTOPERATIVE STUDIES

Two patients (cases 4 and 5) required repeat valvotomy for important residual aortic stenosis. Each had a complete reinvestigation including cross sectional echocardiography, Doppler velocimetry, and cardiac catheterisation before their second operation and this was repeated after operation in one patient (case 5). Clinical and cross sectional echocardiographic findings were inconclusive in both patients, mainly because the aortic valve thickening was no longer of diagnostic value. Doppler velocimetry was able to identify high velocity blood flow jets (3.6–4.4 m/s) (Fig. 1) in the ascending aorta on each occasion, from which gradients were calculated which agreed closely with the cardiac catheterisation findings (Fig. 2).

#### Discussion

The widespread use of cross sectional echocardiography has obviated the need for potentially hazardous cardiac catheterisation and angiocardiology in a large number of patients with congenital heart disease. Our unit has recently reported the results of surgery in patients without previous invasive investigation, among whom there were 39 who were operated on for aortic or subaortic stenosis or coarctation of the thoracic aorta.<sup>1</sup> Three errors occurred, leading to an inappropriate thoracotomy for coarctation of the thoracic aorta in one. No false positive diagnoses were made in the group with aortic stenosis, and we have stressed on the basis of previous experience that an accurate diagnosis of aortic stenosis in neonates requires that the cross sectional echocardiographic appearances must be interpreted in the light of the clinical findings.<sup>7</sup> Nevertheless, in a severely ill neonate with congestive cardiomyopathy a thickened aortic valve (with no gradient) might be mistaken for severe aortic stenosis leading to inappropriate surgery based on the echocardiographic and clinical findings alone.

Continuous wave Doppler velocimetry is an easy and reliable method for locating the site of important obstruction to left ventricular outflow in neonates. We were able to predict the presence of a thoracic aortic coarctation in one patient in whom clinical and cross sectional echocardiographic findings were inconclusive and to confirm the diagnosis in the others. Despite equalisation of the upper and lower limb blood pressures because of the persistent ductus arteriosus, the jet produced from the proximal aortic blood flow through the coarctation site was identified by Doppler velocimetry. In one patient with critical

aortic stenosis and left ventricular dysfunction, the aortic valve appeared to be no more thickened on cross sectional echocardiography than it was in two of the patients with coarctation. This patient underwent aortic valvotomy on the basis of the clinical signs, which suggested aortic stenosis without coarctation. The Doppler findings reinforced the preoperative non-invasive assessment in this and the other patient who required surgery by predicting severe aortic stenosis and excluding coarctation.

Although we did not see such a patient in this study, the combination of aortic stenosis and coarctation can occur.<sup>8</sup> For the reasons outlined above, one of the diagnoses could easily be overlooked in this situation if the diagnosis was based solely on clinical and cross sectional echocardiographic findings. In our patients with aortic stenosis the velocity of blood flow had returned to normal on sampling in the descending aorta, so Doppler velocimetry should be able to differentiate these conditions in the same patient. A high velocity jet which is found in the descending aorta in a patient with aortic stenosis must be due to a local lesion in the descending aorta.

Doppler velocimetry proved very useful in the two patients who remained unwell after aortic valvotomy. Their failure to improve could have been due either to poor left ventricular function or to residual aortic stenosis or to a combination of these factors. Cross sectional echocardiography cannot differentiate between apparent residual aortic cusp deformity and significant haemodynamic obstruction in this situation. Doppler velocimetry showed that important aortic stenosis was present and predicted closely the gradient measured at cardiac catheterisation.

Although Doppler velocimetry was correct in all cases in which confirmation was available there are possible pitfalls in the method, and we have tested only a small number of patients. Nevertheless, continuous wave Doppler velocimetry cannot overestimate blood flow velocity once the gain settings on the machine are set appropriately and reproducible readings are obtained. There is, however, always a potential for underestimation as it may be difficult to align the ultrasound beam with a low angle of incidence to the high velocity jet. If this angle is greater than approximately 20° then the predicted gradient will be a significant underestimate.<sup>6</sup> The use of the abbreviated Bernoulli equation to estimate pressure gradients is appropriate since blood flow proximal to an important stenosis is usually much slower than beyond it.<sup>6</sup> Theoretically, a closing ductus may create a high velocity blood flow jet and produce a false impression of thoracic coarctation but we have not seen this phenomenon in four patients with isolated persistent ductus arteriosus and no coarctation.

In conclusion, in each patient continuous wave

Doppler velocimetry was able to recognise the site of left ventricular outflow tract obstruction by localising a high velocity blood flow jet either in the ascending or descending aorta. In this way a combined anatomical and physiological approach using cross sectional echocardiography and continuous wave Doppler velocimetry can provide objective non-invasive information and may obviate the need for invasive investigation in these sick neonates.

PJR is supported by the Wellcome Research Foundation. FJM and RKHW are supported by the Vandervell and British Heart Foundation.

#### References

- 1 Stark J, Smallhorn J, Huhta J, *et al.* Surgery for congenital heart defects diagnosed with cross-sectional echocardiography. *Circulation* 1983; **68** (suppl II):129-38.
- 2 Hatle L, Angelsen BA, Tromsdal A. Non-invasive assessment of aortic stenosis by Doppler ultrasound. *Br Heart J* 1981; **43**: 284-92.
- 3 Hatle L. Noninvasive assessment and differentiation of left ventricular outflow obstruction with Doppler ultrasound. *Circulation* 1981; **64**: 381-7.
- 4 Friesen RH, Lichtor JL. Indirect measurement of blood pressure in neonates and infants utilizing an automatic noninvasive oscillometric monitor. *Anesth Analg* 1981; **60**: 742-5.
- 5 Silas JH, Barker AT, Ramsay LE. Clinical evaluation of Dynamap 845 automated blood pressure recorder. *Br Heart J* 1980; **43**: 202-5.
- 6 Hatle L, Angelsen B, eds. Doppler ultrasound in cardiology. In: *Physical principles and clinical applications*. Philadelphia: Lea and Febiger, 1982.
- 7 Sink JD, Smallhorn JF, Macartney FJ, Taylor JFN, Stark J, de Leval MR. Management of critical aortic stenosis in infancy. *J Thorac Cardiovasc Surg* 1984; **87**: 82-6.
- 8 Keith JD. Tricuspid aortic valve. In: *Heart disease in infancy and childhood*. 3rd ed. New York: Macmillan, 1978: 733.