

# Fetal complete heart block

M VIRGINIA L MACHADO, M J TYNAN,\* P V L CURRY,† L D ALLAN

From the Departments of Perinatal Cardiology, \*Paediatric Cardiology, and †Cardiology, Guy's Hospital, London

**SUMMARY** In a series of over 6000 patients referred for fetal echocardiography during an eight year period, 37 fetuses were found to have complete heart block. There were 16 cases of isolated heart block and 21 cases associated with structural heart disease. All mothers of fetuses with isolated complete heart block had evidence of circulating syndrome Sjögren A antibody (Ro). Only one mother had clinical evidence of connective tissue disease. In the 21 cases associated with structural heart disease there were 17 cases of atrioventricular septal defect, one case of secundum atrial and perimembranous ventricular septal defects, two cases of tetralogy of Fallot, and one case of pulmonary stenosis. All fetuses with atrioventricular septal defects and complete heart block had left atrial isomerism. Additional abnormalities of the great arteries were often found in this group; these were double outlet right ventricle, transposition of the great arteries, pulmonary atresia, coarctation of aorta, and stenosis of the pulmonary or aortic valves. Intrauterine congestive heart failure was a feature of four cases in the group with isolated complete heart block and 11 cases of the group with associated structural heart disease. The outcome in the fetuses with isolated complete heart block was better than in those with heart disease: 12 of the 16 fetuses are alive, two of them have a pacemaker. But only three of the group of 21 fetuses with cardiac malformation are alive, and two of them have a pacemaker.

Complete heart block was first described as "impaired atrioventricular syndrome" by Morquio in 1901.<sup>1</sup> The condition was characterised by a slow pulse, syncopal attacks, and sudden death. Since then many workers have reported cases of isolated complete heart block and its association with structural heart lesions.<sup>2-4</sup> Hull *et al* in 1966 recognised the relation between maternal systemic lupus erythematosus and complete heart block; they described a child born to a mother with active lupus.<sup>5</sup> More recently a strong association has been found between isolated infantile complete heart block and the presence of syndrome Sjögren A antibody in maternal serum.<sup>6,7</sup> This antibody is also known as Ro, after the patient in whom it was first detected.<sup>8</sup>

The first case of fetal heart block was reported by Plant and Steven in 1945.<sup>9</sup> The diagnosis was suspected by fetal heart auscultation and fetal electrocardiogram. Fetal heart block can now be detected by M mode and Doppler echocardiographic examin-

ation.<sup>10,11</sup> Structural heart defects in the fetus can be seen by cross sectional echocardiography.<sup>12,13</sup> The association between atrioventricular septal defect, left atrial isomerism, and complete heart block has been described previously in both postnatal and prenatal life.<sup>14,15</sup> We describe a series of cases of complete heart block diagnosed in prenatal life, with the associations and outcome of these cases.

## Patients and methods

During an eight year period over 6000 fetal echocardiograms were performed in our department. All cases were referred because the fetus was considered to be at increased risk of structural heart disease. The reasons for referral included a family history of congenital heart disease, maternal diabetes, exposure to cardiac teratogens, the detection of fetal arrhythmia, non-immune hydrops, or an abnormal heart structure suspected on a routine scan. We found complete heart block in 37 fetuses.

Fetal echocardiography was performed with an Advanced Technical Laboratories Mark 4 sector scanner or a Hewlett-Packard 77020A phased array system with a 5 MHz transducer. The fetal heart was visualised and cardiac structure was established. The

Requests for reprints to Dr L D Allan, Department of Perinatal Cardiology, 15th Floor, Guy's Tower, St Thomas Street, London SE1 9RT.

Accepted for publication 14 July 1988

### Fetal complete heart block

rhythm and heart rate were identified by directing the M line through the aorta and left atrial wall. Atrial systole was demonstrated by movement of the atrial wall towards the aortic root. Ventricular systole was identified by the opening of the aortic valve. The relation between atrial and ventricular contraction was established and complete heart block diagnosed in those fetuses in which there was complete dissociation between atrial and ventricular contraction. In fetuses with isolated complete heart block we examined maternal serum for syndrome Sjögren A antibody.

### Results

Sixteen of the 37 cases of fetal heart block that we detected had no other abnormality and 21 had associated structural cardiac disease. The gestational age at diagnosis ranged from 17 to 38 weeks. There were 35 singleton pregnancies and one case of twins. Each twin had isolated heart block.

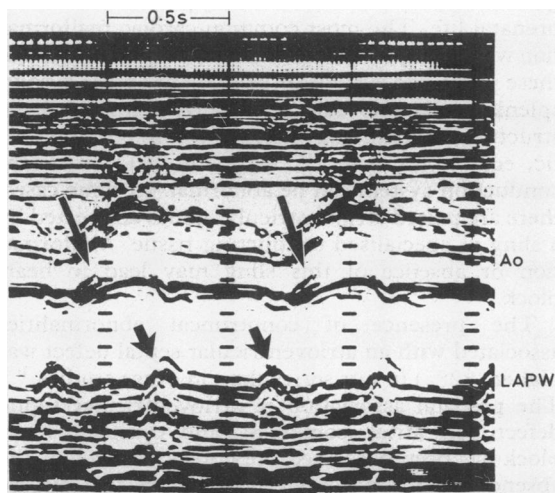
All mothers with fetuses who had isolated complete heart block had positive titres of skin sensitising antibodies. One mother had clinical evidence of Sjögren's syndrome. There was no correlation between maternal antibody titre and outcome in these cases. In the 16 with isolated complete heart block the reason for referral in all cases was because the obstetrician had detected an irregular fetal cardiac rhythm or bradycardia on a routine scan. Four of these fetuses were hydropic. In one case the pregnancy was terminated at 17 weeks because the

severity of hydrops suggested a poor prognosis. In the twin pregnancy both fetuses had gross hydrops and poor ventricular function seen initially at 34 weeks' gestation. Both twins died in utero at 36 weeks' gestation. The fourth case of hydrops presented at 21 weeks' gestation. Cardiac function was poor and intrauterine death was expected. Examination of this pregnancy, however, at 26 and 30 weeks showed resolution of the hydrops and improved cardiac function.

Another fetus died in utero at 27 weeks' gestation four weeks after premature rupture of membranes. In the remaining 11 fetuses, the course of pregnancy was uneventful. Nine patients are alive and well and have not required a pacemaker. Two children had permanent pacemaker implantation. In one infant a cardiac arrest before pacemaker implantation caused brain damage.

The 21 fetuses with complete heart block and associated cardiac abnormality were referred for fetal echocardiography because of bradycardia in six fetuses, suspected congenital heart disease in four, the association of non-immune fetal hydrops and heart abnormality in eight, and the detection of fetal bradycardia, hydrops, and congenital heart disease in three. A complete atrioventricular septal defect was found in 17 fetuses. None was associated with chromosomal abnormality. One further fetus had a large secundum atrial and perimembranous ventricular septal defect. All 18 had left atrial isomerism. Thirteen of these 18 fetuses also had abnormalities of the great arteries. Double outlet right ventricle was found in four fetuses, transposition in one, and pulmonary atresia in two. Pulmonary or aortic stenosis was found in five and three fetuses respectively. Coarctation of the aorta was found in one. In the remaining three fetuses with structural heart disease and normal atrial situs, the diagnoses were tetralogy of Fallot in two and pulmonary stenosis in one.

Non-immune fetal hydrops was found in 11 fetuses of this group. Pregnancy was terminated in nine cases: in six there was severe hydrops in the second trimester of pregnancy with complex cardiac anomalies. Four fetuses died in utero; all were hydropic with an atrioventricular septal defect. There were two neonatal deaths within the first week of life. One neonate with an atrioventricular septal defect, left atrial isomerism, and transposition of the great arteries died on the fourth day of life and the other with an atrioventricular septal defect and left atrial isomerism died immediately after birth. There were three infant deaths, one after total correction of an atrioventricular septal defect at nine months and one other after total correction of tetralogy of Fallot at six months. The third case with an atrioventricular septal defect and double outlet right ventricle died at



**Figure** The M mode echocardiogram positioned to record the aortic valve (Ao) and left atrial posterior wall (LAPW). The larger arrows show opening of the aortic valve. Atrial contraction, indicated by the smaller arrows, is unrelated to ventricular contraction.

two years of age after a Blalock shunt operation. There are three survivors. One has an atrioventricular septal defect, left atrial isomerism, and pulmonary and aortic stenosis. Although his condition improved after pacemaker implantation, he remains in heart failure. The other case with severe tetralogy of Fallot had a pacemaker implanted at one year of age and his physical development is normal. The third survivor with pulmonary stenosis has had a successful balloon dilatation and pacemaker implantation was not required.

## Discussion

Isolated fetal complete heart block has been considered to result from either an independent congenital malformation of the conduction system, maternal rheumatic disorder, or fetal myocarditis. The known association between infantile heart block and latent or symptomatic maternal connective tissue disease led us to test these mothers for syndrome Sjögren A antibody.<sup>16-18</sup> All cases of isolated heart block had circulating maternal syndrome Sjögren A antibody. One mother had overt Sjögren's syndrome. It has been postulated that syndrome Sjögren A antibodies, probably of the IgG class, cross the placenta and damage the fetal cardiac conduction system. Evidence of deposits of this antibody in atrial tissue suggests a direct action on cardiac tissue.<sup>19</sup> This may initiate an inflammatory process with a subsequent immunological response causing heart block. There is speculation about whether this immunological process interferes with normal development of the conducting tissue or damages the conducting system after it has been formed.<sup>20,21</sup> Our earliest case of complete heart block was detected in a fetus at 17 weeks' gestation. Histopathological features reported in seven patients born to mothers with skin sensitising antibodies<sup>22</sup> showed gross damage of the conduction system. In all hearts in this earlier report normal tissue in the atrioventricular node had been replaced by fibrous and adipose tissue. Also, the sinus nodes in some of these cases were hypoplastic. The mother in our study who had Sjögren's syndrome had already had a child with this condition. In this group irregularity of fetal heart rhythm or fetal bradycardia was the main reason for referral for fetal echocardiography. However, one case was referred with suspected fetal distress because of the slow heart rate, and premature delivery had been planned. This was avoided by establishing the diagnosis of complete heart block. We recommend a fetal echocardiogram in all mothers with rheumatic disease who have syndrome Sjögren A antibody. Early detection of heart block will assist in planning appropriate obstetric management. Nine of 16 fetuses with isolated

heart block are alive, symptom free, and do not require a pacemaker. Two patients are paced. It is important to recognise that complete heart block in infants is not always a benign condition. One of our patients suffered a cardiac arrest at home at the age of three months, which caused an appreciable neurological handicap. Also, pacemaker implantation in itself can be hazardous in neonates.<sup>23</sup>

Fetal hydrops was seen in four cases in this group. One pregnancy was terminated at 17 weeks because of the severity of hydrops and the poor prognosis. A set of twins died in utero at 36 weeks' gestation on the day an elective delivery was planned. The fourth fetus had pronounced hydrops and cardiomegaly at 21 weeks but had spontaneous regression of these findings by the subsequent examinations at 20 and 30 weeks' gestation. This observation conflicts with the common belief that the hydropic fetus with complete atrioventricular block will die in utero if left untreated. This view has prompted fetal trans-thoracic ventricular pacing.<sup>24</sup>

In a series reported in 1970, 80% of cases seen at necropsy had complete heart block in association with structural heart disease.<sup>25</sup> More than half of our cases seen in prenatal life had this combination. The frequency of this association in our series affected the outcome adversely. Thus of the total series of 37 cases, there are only 15 survivors of 27 continuing pregnancies. In an unselected series of children with complete heart block, only 25% had associated heart disease.<sup>26</sup> Our experience of spontaneous intrauterine death in a considerable proportion of patients suggests that many of these cases may pass undetected in prenatal life. The most common cardiac malformation was a complete atrioventricular septal defect. All these cases had left atrial isomerism and the polysplenia syndrome. The sinus node is a right atrial structure and pathology may show it to be hypoplastic, ectopic, or absent.<sup>27</sup> Also, the atrioventricular conduction system can be abnormal. In some cases there are paired atrioventricular nodes connected by a sling of specialised conducting tissue. Malformation or absence of this sling may lead to heart block.<sup>28-30</sup>

The presence of conotruncal abnormalities associated with an atrioventricular septal defect was higher (82%) in our series than in other studies.<sup>31</sup> The prenatal association of atrioventricular septal defect, left atrial isomerism, and complete heart block has been described previously<sup>15</sup> as well as the absence of chromosomal anomalies in this disease complex. Tetralogy of Fallot seen in two fetuses was an unusual association with heart block. Fetal non-immune hydrops was a feature in more than half of the fetuses with heart disease and heart block and was the main reason for termination of pregnancy in nine



patients. Four fetuses died spontaneously in utero. There were two neonatal deaths during the first week of life and three infants died after operation. Out of eight pregnancies that continued only three patients are alive and two of them have required pacing.

In conclusion, cases of complete heart block seen in prenatal life are more likely to be associated with structural cardiac abnormalities than cases which are seen postnatally. The prognosis depends on the presence or absence of structural heart disease and the type and severity of the cardiac malformation. In general, fetuses with associated heart disease have a poorer prognosis than those with isolated complete heart block.

MVLM is supported by a grant from the Brazilian Government and LDA by the British Heart Foundation.

### References

- Morquio L. Sur une maladie infantile et familiale caractérisée par des modifications permanentes du pouls, des attaques syncopales et épileptiformes et la mort subite. *Archives Medicine des Enfants* 1901;4:467.
- Aylward RD. Congenital heart block. *Br Med J* 1928; i:943.
- Aitken JK. Congenital heart block. *Lancet* 1932;ii: 1375-9.
- Lev M, Fielding RT, Zaeske D. Mixed levocardia with ventricular inversion (corrected transposition) with complete atrioventricular block. *Am J Cardiol* 1963; 12:875-83.
- Hull D, Binns BAO, Joyce D. Congenital heart block and widespread fibrosis due to maternal lupus erythematosus. *Arch Dis Child* 1966;41:688-90.
- Singsen BH, Akhter JE, Weinstein MM, Sharp GC. Congenital complete heart block and SSA antibodies: obstetric implications. *Am J Obstet Gynecol* 1985; 152:655-8.
- Scott JS, Maddison PJ, Esscher E, Scott O, Skinner RP. Connective tissue disease, antibodies to ribonucleoprotein and congenital heart block. *N Engl J Med* 1983;309:209-12.
- Clark GM, Reichlin M, Tomasi TB. Characterisation of a soluble cytoplasmic antigen reactive with sera from patients with systemic lupus erythematosus. *J Immunol* 1969;102:117-22.
- Plant RK, Steven RA. Complete atrioventricular block in a fetus. *Am Heart J* 1945;30:615-8.
- Allan LD, Anderson RH, Sullivan ID, Campbell S, Holt DW, Tynan M. Evaluation of fetal arrhythmias by echocardiography. *Br Heart J* 1983;50:240-5.
- Steinfeld L, Rappaport HL, Rossbach C, Martinez E. Diagnosis of fetal arrhythmias using echocardiographic and Doppler techniques. *J Am Coll Cardiol* 1986;9:1425-33.
- Allan LD, Crawford DC, Anderson RH, Tynan MJ. Echocardiographic and anatomical correlations in fetal congenital heart disease. *Br Heart J* 1984;52: 542-8.
- Allan LD, Crawford DC, Anderson RH, Tynan M. Spectrum of congenital heart disease detected echocardiographically in prenatal life. *Br Heart J* 1985; 54:523-6.
- Garcia OL, Mehta AV, Pickoff AS, et al. Left isomerism and complete atrioventricular block: a report of six cases. *Am J Cardiol* 1981;48:1103-10.
- Machado MVL, Crawford DC, Anderson RH, Allan LD. Atrioventricular septal defect in prenatal life. *Br Heart J* 1988;59:352-5.
- McCue CM, Mantakas ME, Tingelstad JB, Ruddy S. Congenital heart block in newborns of mothers with connective tissue disease. *Circulation* 1977;56:82-90.
- Lanham JG, Walport MJ, Hughes GRV. Congenital heart block and familial connective tissue disease. *J Rheumatol* 1983;10:823-5.
- Paredes RA, Morgan H, Lachelin GCL. Congenital heart block associated with maternal primary Sjögren's syndrome. *Br J Obstet Gynaecol* 1983;90: 870-1.
- Litsey SE, Noonan JA, O'Connor WN, Cottrill CM, Mitchell B. Maternal tissue disease and congenital heart block. *N Engl J Med* 1985;312:98-100.
- Lev M, Silverman J, Fitzmaurice FM, Paul MH, Cassells DE, Miller RA. Lack of connection between the atria and the more peripheral conduction system in congenital atrioventricular block. *Am J Cardiol* 1971; 27:481-90.
- Anderson RH, Wenick ACG, Losekoot TG, Becker AE. Congenitally complete heart block: developmental aspects. *Circulation* 1977;56:90-101.
- Ho SY, Esscher E, Anderson RA, Michaelsson M. Anatomy of congenital heart block and relation to maternal anti-Ro antibodies. *Am J Cardiol* 1986; 58:291-4.
- Gamble WJ, Owens JP. Pacemaker therapy for conduction defects in the pediatric population. In: Roberts NK, Gelband H, eds. *Cardiac arrhythmias in the neonate, infant and child*. New York: Appleton-Century-Crofts, 1977:chapter 17,469-525.
- Carpenter RJ, Strasburger JF, Garson A, Smith RT, Russel LD, Engelhardt HT. Fetal ventricular pacing for hydrops secondary to complete atrioventricular block. *J Am Coll Cardiol* 1986;8:1434-6.
- Sotelo-Avila C, Rosenberg HS, McNamara DG. Congenital heart block due to a lesion in the conduction system. *Pediatrics* 1970;45:640-50.
- Michaelsson M, Engle MA. Congenital complete heart block: an international study of the natural history. *Cardiovasc Clin* 1972;4:85-101.
- Bharati S, Lev M. The course of the conduction system in dextrocardia. *Circulation* 1978;57:163-71.
- Anderson RH, Smith A, Wilkinson JL. Right juxtaposition of the auricular appendages. *Eur J Cardiol* 1976;4:495-503.
- Dickinson DF, Wilkinson JL, Anderson KR, Smith A, Ho SY, Anderson RA. The cardiac conduction system in situs ambiguus. *Circulation* 1979;59:879-85.
- Davies MJ, Anderson RH, Becker AE. *The conduction system of the heart*. London: Butterworth, 1983:99-159.
- Thiene G, Frescura C, DiDonato R, Gallucci V. Complete atrioventricular canal associated with conotruncal malformations: anatomical observations in 13 specimens. *Eur J Cardiol* 1979;9/3:199-213.
- Toussaint M, Planche C, Graff WC, Royon M, Ribierre M. Double outlet right ventricle associated with common atrioventricular canal: report of nine anatomic specimens. *J Am Coll Cardiol* 1986;8:396-401.