

## CASE REPORTS

## Prenatal diagnosis of a complex fetal cardiac malformation associated with asplenia

Ingrid Mauser, Josef Deutinger, Gerhard Bernaschek

### Abstract

**A case of a complex fetal heart malformation with left isomerism, a "right sided" double outlet ventricle, and aortic isthmus stenosis combined with asplenia was diagnosed by ultrasonography at 26 weeks' gestation. The pregnancy was terminated at the request of the parents in the 27th week of gestation. Because the prognosis for a fetus with cardiosplenic syndromes depends mainly on the severity of the cardiac abnormality cases of visceral heterotaxy should be classified according to the predominant feature, the heart malformation.**

Congenital heart disease is sometimes associated with anomalies of the situs of the visceral organs (visceral heterotaxy). The term cardiosplenic syndrome is used to describe the combination of a heart defect with asplenia<sup>1</sup> or the so-called "polysplenia syndrome".<sup>2</sup> Absence of the spleen is usually associated with right isomerism (two morphologically right atrial appendages), bilaterally trilobed (morphologically right) lungs and bronchial trees, and a central liver ("asplenia syndrome"). The cardiac abnormalities include total anomalous pulmonary venous return, atrioventricular septal defect, double inlet ventricle, discordant ventriculoarterial connection, and pulmonary stenosis or atresia.<sup>3,4</sup> The inferior vena cava and abdominal aorta run together right or left of the spine, and the aorta is located posteriorly.

Polysplenia, or multiple small spleens, is often combined with left isomerism (two morphological left atrial appendages) and

bilateral bilobed (morphological left) lungs and bronchi. In about 70% of cases the inferior vena cava is absent and replaced by the azygos vein. In polysplenia possible cardiac defects show a wide spectrum of atrial and atrioventricular septal defects; double outlet right ventricle or transposition of the great arteries are rare.<sup>2</sup> In both asplenia and polysplenia other visceral organs are commonly affected.

Prenatal diagnosis of the unusual combination of left isomerism with asplenia has already been reported.<sup>5</sup> We report the prenatal diagnosis of left isomerism, a "right sided" double outlet ventricle, and aortic isthmus stenosis.

### Case report

A 32 year old woman (gravida 1) was referred for ultrasound examination because of fetal bradycardia during a non-stress test. Ultrasound examination (Toshiba Sonolayer SSA-250A, Toshiba Medical Systems) showed one fetus with biometric data appropriate for the gestational age of 26 weeks. The heart rate was 60 to 70 beats/min, fetal ascites was visible, as was cardiac failure.

### ECHOCARDIOGRAPHIC EXAMINATION

The fetal heart seemed to be displaced to the right more than normal and the apex seemed to be on the left. The descending aorta ran to the right of the spine. The four-chamber view showed two extremely dilated atria with a big primum atrial septal defect and two small ventricles with hypertrophic walls (Fig 1a and b). We also found a small ventricular septal defect of the hypertrophic

2nd Department of  
Obstetrics and  
Gynaecology,  
University of Vienna,  
Vienna, Austria  
I Mauser  
J Deutinger  
G Bernaschek

Correspondence to  
Dr Josef Deutinger, 2nd  
Department of Obstetrics  
and Gynaecology, University  
of Vienna, Spitalgasse 23, A-  
1090 Vienna, Austria.

**Figure 1**  
Echocardiograms showing (A) a big atrial septal defect (ASD), a small ventricular septal defect (VSD), and hypertrophic ventricular walls in four chamber view and (B) stenosis of the aortic isthmus (AIS) with dilatation proximally and distally in longitudinal section.

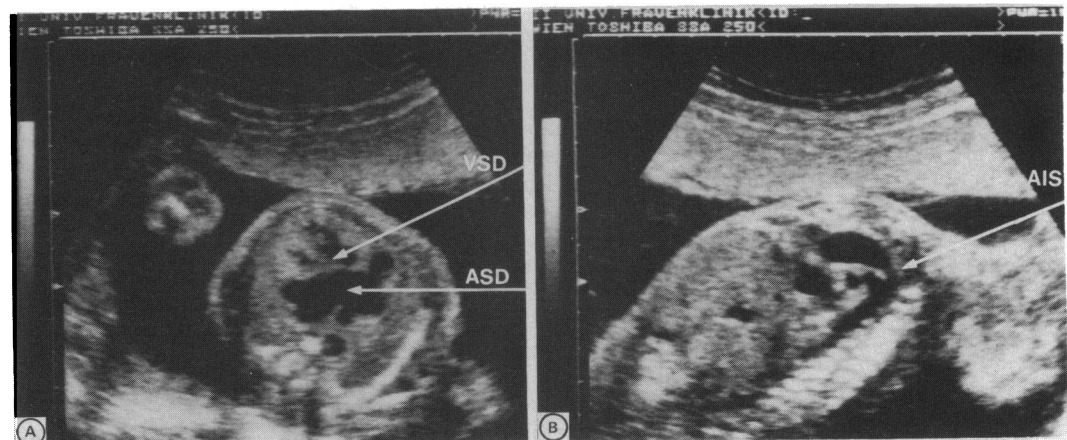
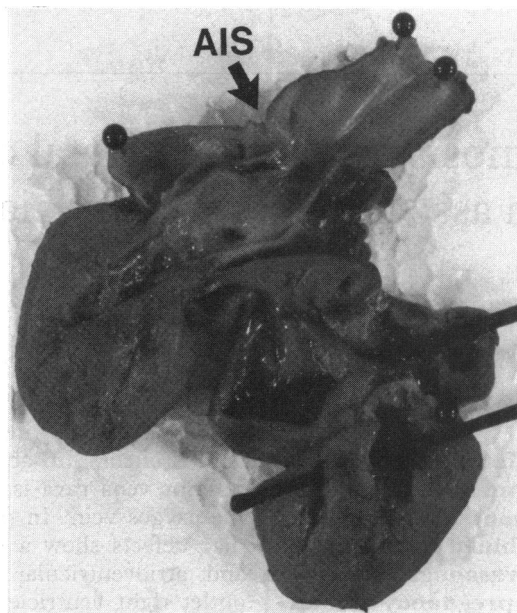


Figure 2 Necropsy of the fetal heart. Upper stylet marks the big atrial septal defect, the lower the ventricular septal defect, and the arrow indicates the aortic isthmus stenosis (AIS). Both great vessels (aorta and pulmonary trunk) arise from the right sided main chamber.



interventricular septum. Two separate atrioventricular valves were seen. Left of the larger main chamber a smaller ventricle was visualised with an atrioventricular valve inserted more apically (morphological right ventricle on the left side). This small chamber was connected to the left sided atrium. A vessel thought to be the superior vena cava and the hepatic veins drained into this atrium. A dilated venous abdominal vessel (azygos vein) that ran left of the spine and showed no connection with the hepatic veins drained into the superior vena cava and into this left sided atrium. The right sided larger ventricle seemed to be morphologically left because of the insertion of its atrioventricular valve. Both the dilated pulmonary trunk and the aorta arose from this ventricle. The aorta showed a stenosis of the isthmus with proximal and distal dilatation. The descending aorta ran right of the spine and in front of the azygos vein, which, however, ran left of the spine. M mode investigation repeated several times during the examination ruled out complete heart block.

Placental biopsy showed a normal male karyotype. The parents were told about the prognosis by the paediatrician and they requested a termination. This was performed in week 27 of gestation.

#### FINDINGS AT NECROPSY

Postmortem examination showed a male infant. The spleen was absent. The lungs were bilaterally bilobed with bilateral hyperarterial bronchial trees. The superior and inferior mesenteric arteries were connected to a single vessel. The abdominal aorta ran on the right of the spine and the abdominal venous vessel on the left. The heart was displaced to the right with its apex pointing to the left. Inspection showed that both atria had typical left atrial appendages (fig 2). The pulmonary veins drained into the right sided atrium. The

superior vena cava, which took up the azygos vein, was connected to the left sided atrium into which the hepatic veins also drained directly. A big atrial septal defect and a small subvalvar ventricular septal defect were found. There were two separate atrioventricular valves. The walls of the right and left ventricles could not be morphologically distinguished because of hypertrophy. Both the pulmonary trunk and the aortic arch arose from the right sided ventricle. The aortic valve was in continuity with the atrioventricular valve of the right ventricle. On both sides of the stenosis at the isthmus the aorta was dilated.

#### Discussion

The term "cardiosplenic syndrome" describes complex congenital malformations of the heart and spleen in which there is a tendency toward symmetrical development of organs and organ systems that are usually asymmetrical.<sup>6</sup> Because many other organs including the lungs, intestines, kidneys, and venous system may be affected it is more accurate to use the term visceral heterotaxy to describe this syndrome.

The anatomical details of the fetal spleen, lungs, and intestines cannot be reliably displayed by current ultrasound methods. Therefore prenatal diagnosis of such malformations in combination with the absence or multiplication of the spleen and cardiac abnormalities must focus on examination of the heart. In fetal echocardiography, as in anatomical studies, sequential analysis of the chambers and connections of the heart is based on morphological characteristics.<sup>7-9</sup> Usually the morphological right structures are found on the right side (situs solitus). In situs inversus, the morphological right structures are found on the left side. The term isomerism is used to describe the situation when paired organs such as the atria (or lungs) have identical morphological characteristics.

Classic terminology combines absence of the spleen with right isomerism. The prognosis is generally considered to be poor because transposition of the great arteries with pulmonary stenosis or atresia and total anomalous pulmonary venous drainage are often present.<sup>10</sup>

Polysplenia typically is associated with left isomerism and azygos vein continuation. The overall outcome is thought to be better than for asplenia and the accompanying cardiac defects show a wide range of severity.<sup>4,10</sup>

Cases of right isomerism (no spleen expected) with detectable splenic tissue as well as left isomerism with asplenia (polysplenia expected) do not belong to either group.<sup>11-14</sup> These cases, however, were diagnosed at necropsy.

Stewart *et al* were the first to report two cases of left atrial isomerism diagnosed prenatally by fetal echocardiography in which necropsy showed asplenia.<sup>5</sup> We report prenatal diagnosis of left isomerism, a double outlet "right sided" ventricle, and stenosis of the aortic isthmus associated with absence of the spleen. Because

of several "crossover" cases, "asplenia" and "polysplenia" are regarded as imperfect terms to describe cardiosplenic syndromes. The combined heart lesions of our fetus fit perfectly into a classification based on the atrial arrangement according to atrial appendage morphology.

In left isomerism (two morphological left atrial appendages) azygos vein continuation is typical.<sup>13 15</sup> Also two morphologically left (that is, bilobed) lungs and bronchial trees were present.<sup>2 4 14</sup> Atrial septal defect and ventricular septal defect are often found, as in our case. A double outlet ventricle is encountered in about 9–20%.<sup>4 10</sup> The association of isomerism of the left atrial appendages with aortic outflow obstruction at different levels has been reported<sup>13</sup>; however, this is a rare combination. The malformations typical of right isomerism such as anomalous pulmonary venous drainage, transposition of the great arteries, and pulmonary stenosis or atresia were not present in our case. Fetal bradycardia is usually due to complete heart block<sup>16</sup> which is often present in cases with left isomerism.<sup>17</sup> However, in our case severe sinus bradycardia followed by ascites showed that the fetus was about to die. After consulting the paediatrician the parents decided to request termination of the pregnancy, because surgical correction of the heart defect was regarded as impossible.

Prenatal evaluation of splenic disorders is unreliable. However, even complex and uncommon cases of cardiosplenic syndromes can be diagnosed prenatally by sequential morphological echocardiographic analysis of the heart and great vessels, as shown in our case. The prognosis of a fetus with a malformation of this kind depends on the severity of cardiac abnormality. Therefore, cardiosplenic syndromes should be classified according to the most important clinical feature—the heart malformation.

We thank Dr Patricia Stewart, Erasmus University, Dijkzigt, Rotterdam, for her invaluable advice.

- 1 Ivemark IB. Implication of agenesis of the spleen on the pathogenesis of conotruncus anomalies in childhood: analysis of the heart malformations in splenic agenesis syndrome, with fourteen new cases. *Acta Paediatr Scand* 1955;44 (suppl 104):1–110.
- 2 Moller JH, Nakib A, Anderson RC, Edwards JE. Congenital cardiac disease associated with polysplenia. A development complex of bilateral "left-sidedness." *Circulation* 1967;36:789–99.
- 3 Van Mierop LHS, Wigglesworth FW. Isomerism of the cardiac atria in the asplenia syndrome. *Lab Invest* 1962;11:1303–5.
- 4 Van Mierop LHS, Gessner IH, Schiebeler GL. Asplenia and polysplenia syndrome. *Birth Defects* 1972;1:74–82.
- 5 Stewart PA, Becker AE, Wladimiroff JW, Essed CA. Left atrial isomerism associated with asplenia: prenatal echocardiographic detection of complex congenital cardiac malformations. *J Am Coll Cardiol* 1984;4:1015–20.
- 6 Romero R, Pilu G, Jeanty P, Ghidini A, Hobbins JC. *Prenatal diagnosis of congenital anomalies*. Connecticut: Appleton and Lange, 1988:184–6.
- 7 Shinebourne EA, Macartney FJ, Anderson RH. Sequential chamber localization—logical approach to diagnosis in congenital heart disease. *Br Heart J* 1976;38:327–40.
- 8 Allan LD, Tynan MJ, Campbell S, Wilkinson JL, Anderson RH. Echocardiographic and anatomical correlates in the fetus. *Br Heart J* 1980;44:444–51.
- 9 Stewart PA. *Echocardiography in the human fetus*. 's-Gravenhage: Pasmans Offsetdrukkerij BV, 1989:13–21.
- 10 Rose V, Izukawa T, Moës CAF. Syndromes of asplenia and polysplenia. A review of cardiac and non-cardiac malformations in 60 cases with special reference to diagnosis and prognosis. *Br Heart J* 1975;37:840–52.
- 11 Layman TE, Levine MA, Amplatz K, Edwards JE. "Asplenic syndrome" in association with rudimentary spleen. *Am J Cardiol* 1967;20:136–40.
- 12 Macartney FJ, Zuberbuhler JR, Anderson RH. Morphological considerations pertaining to recognition of atrial isomerism. Consequences for sequential chamber localisation. *Br Heart J* 1980;44:657–67.
- 13 Sharma S, Devine W, Anderson RH, Zuberbuhler JR. The determination of atrial arrangement by examination of appendage morphology in 1842 heart specimens. *Br Heart J* 1988;60:227–31.
- 14 Anderson C, Devine WA, Anderson RH, Debich DE, Zuberbuhler JR. Abnormalities of the spleen in relation to congenital malformations of the heart: a survey of necropsy findings in children. *Br Heart J* 1990;63:122–8.
- 15 Huhta JC, Smallhorn JF, Macartney FJ. Two dimensional echocardiographic diagnosis of situs. *Br Heart J* 1982; 48:97–108.
- 16 Crawford D, Chapman M, Allan L. The assessment of persistent bradycardia in prenatal life. *Br J Obstet Gynaecol* 1985;92:941–4.
- 17 Anderson RH, Allan L. The heart. In: Reed GB, Claireaux AE, Bain AD, eds. *Diseases of the fetus and newborn. Pathology, radiology and genetics*. London: Chapman and Hall Medical, 1989:217–46.