

Thallium scans in syndrome X

Ann C Tweddel, W Martin, I Hutton

Abstract

Objective—To review thallium scans in patients with angina and normal coronary arteriograms.

Design—Retrospective review of data.

Setting—Regional cardiac centre in Glasgow.

Patients—100 patients selected from those undergoing diagnostic angiography for typical angina who had normal arteriograms (around 10%), no other cardiovascular abnormality, and available thallium scans (performed routinely before angiography).

Main outcome measures—Coronary arteriography, exercise tests, and gated thallium scans at peak exercise.

Results—The exercise test was positive in 30 and negative in 70 patients. Thallium defects were found in 98 patients, but no consistent pattern and no significant correlation existed between the extent of thallium defect and positive exercise test or exercise tolerance.

Conclusions—Thallium defects described in 98 of 100 patients with angina and normal coronary arteriograms suggest that microvascular angina may be commoner than is generally appreciated.

The possibility that angina might in some cases be due to small vessel disease emerged with the advent of coronary angiography in the late 1960s. After an editorial comment on one report of such cases in 1973,¹ chest pain with normal coronary arteries has come to be known by cardiologists as syndrome X. Despite the many subsequent reports, however, differences in diagnostic criteria together with the lack of direct evidence of small vessel disease, and ignorance about the underlying pathology of this putative entity, have left many unanswered questions. Indeed the prevalence of the condition is unknown, estimates varying by one or more orders of magnitude.² Patients with chest pain and normal coronary arteriograms present a common diagnostic problem, but there is general agreement that in most cases the pain is non-cardiac,³ often musculoskeletal or oesophageal in origin.⁴ A small proportion remains in whom incontrovertible evidence exists for inducible myocardial ischaemia, implying coronary microvascular dysfunction.² This has been inferred from stress induced left ventricular dysfunction,^{5,6} and pacing induced lactate production as specific but insensitive evidence of myocardial ischaemia,⁷⁻¹⁰ and

evidence by a number of different techniques of reduced coronary vascular reserve.^{9,11-13}

Here we report the results of thallium scans in 100 patients investigated for angina but found to have normal coronary arteriograms.

Patients and methods

PATIENTS

A total of 328 of the 3150 diagnostic coronary arteriograms performed in the cardiology department at the Glasgow Royal Infirmary during the period 1988 to 1990 inclusive were reported as normal. We reviewed these 328 normal coronary arteriograms and selected the first 100 in whom (a) the arteriogram was confirmed as entirely normal, (b) an exercise thallium scan was available, and (c) there was no other cardiovascular or potentially related abnormality (including overt present or known past hypertension, diabetes, or conduction defect). To obtain 100 patients who fulfilled all three criteria in this retrospective study, the first 115 of those reported to have normal coronary arteriograms were reviewed, 10 were excluded because the arteriograms were not entirely normal, and five were excluded because the resting electrocardiogram showed left bundle branch block (LBBB). All patients had been considered before investigation to have typical stable angina of effort by at least two experienced cardiologists. Maintenance treatment was continued throughout the investigations.

EXERCISE TEST AND THALLIUM IMAGING

A symptom limited maximal upright bicycle exercise test was performed in all cases during the one to two days before angiography. An ST depression of ≥ 1 mm at 0.8 s past the J point was considered diagnostically positive. An intravenous injection of 60 MBq of thallium-201 was given 15-30 s before the end of exercise. Scans were then obtained with a mobile gamma camera (General Electric) fitted with a high sensitivity parallel collimator (reperfusion scans were not routinely performed). Data were acquired in list mode (Link MAPS 2000) gated to the electrocardiogram in three standard projections: 40° and 70° left anterior oblique, and anterior. Data were reconstructed into eight frames per cardiac cycle and viewed both as static smoothed images and in cine mode. Images were reported independently by two experienced persons unaware of the angiographic findings or patient identity. Each of the three images was subdivided into five regions (fig 1), and each region was further divided into three, giving a total of 45 segments. Thallium uptake in each region

University
Department of
Medical Cardiology,
Royal Infirmary,
Glasgow G31 2ER
A C Tweddel
W Martin
I Hutton

Correspondence to
Dr Ann C Tweddel,
University Department of
Medical Cardiology, Royal
Infirmary, 10 Alexandra
Parade, Glasgow G31 2ER.

Accepted for publication
9 February 1992

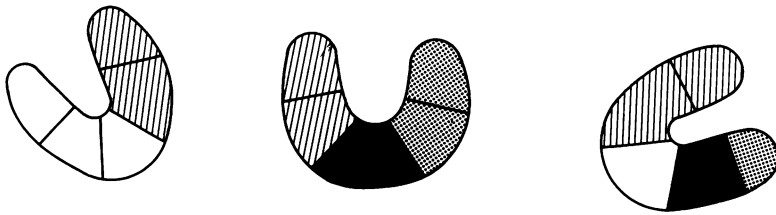


Figure 1 Anterior, 40° and 70° left anterior oblique projections, subdivided into regions. Lined area, territory of left anterior descending artery; black, right coronary artery distribution; stippled, circumflex coronary artery distribution; blank, indeterminate. Each region was further subdivided into three making a total of 45 segments.

was reported as either normal or abnormal. Figure 1 illustrates the method, showing the territories supplied by each of the major coronary vessels, with unmarked areas considered as indeterminate. The predictive accuracy of this method for detection of atheromatous coronary disease is 91% ($n = 100$).¹⁴ To avoid false positive scans due to breast attenuation, septal defects in women were required to be present in all three views. The extent of the thallium defect was assessed by circumscribing the abnormality and expressing this as a percentage of the left ventricular region of interest in each projection. Wall motion was assessed by a four point scoring system (1, normal; 2, reduced; 3, greatly reduced; and 4, no motion). The reproducibility of this reporting technique is $\pm 2\%$ as previously reported.¹⁴

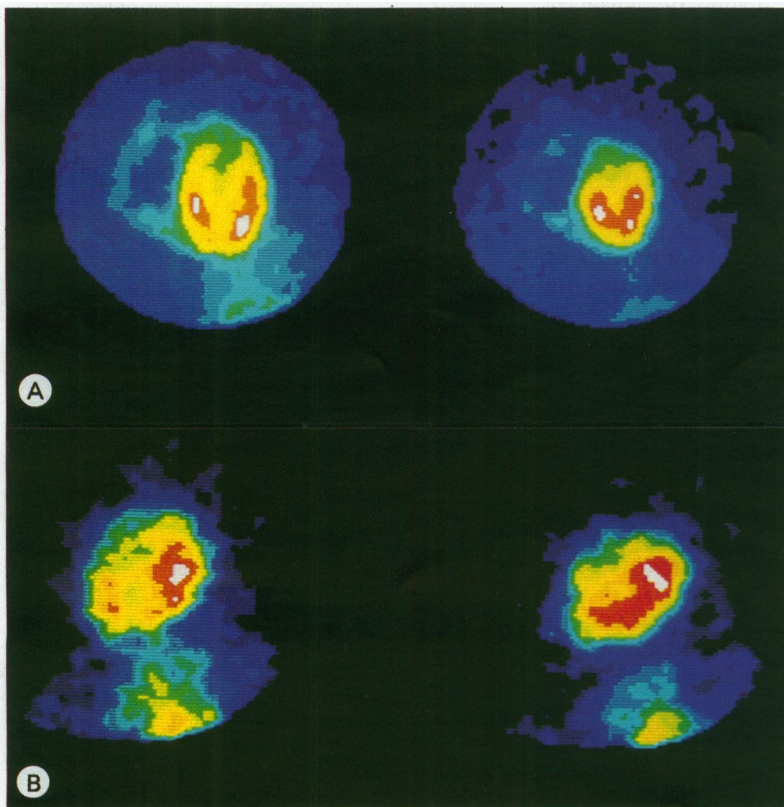


Figure 2 (A) Representative normal thallium scan, in end diastole and end systole in the 40° left anterior oblique projection, with homogeneous activity within the left ventricle. (B) Representative thallium scan showing a septal defect in end diastole and systole in the 40° left anterior oblique projection.

Results

CLINICAL AND ELECTROCARDIOGRAPHIC CHARACTERISTICS

The age range of the group was 29–64 (mean 57), and 58 of the 100 patients were women. Resting heart rate was 76 (13) (mean (SD)) beats/min and blood pressure 124 (20)/77 (10) mm Hg. None gave a history or showed electrocardiographic evidence of previous myocardial infarction. Resting electrocardiogram was normal in 61%, but showed T wave changes in 31% and ≤ 1 mm ST elevation in 8%. Echocardiography was not routinely performed but no patient showed evidence of left ventricular hypertrophy by electrocardiographic criteria or on left ventricular angiogram. Treatment included β blockers in 47%, calcium channel blockers in 59%, nitrovasodilators in 27%, and diuretics in 22%; 12% of patients were taking no cardio-active drugs.

The exercise test was electrocardiographically positive (≥ 1 mm ST depression) in 30 patients but negative in the other 70. The limiting symptom was chest pain in 44 patients, dyspnoea in 25, leg fatigue in 20, fatigue in eight, and nausea or dizziness in three.

Ninety eight patients had abnormal thallium scans. Figure 2 shows representative examples of a normal and an abnormal scan. The table shows the distribution of the defects in thallium uptake. The extent of the defect varied widely (fig 3) and showed no significant correlation with peak exercise “double product” (heart rate \times systolic pressure) or with a positive exercise test though patients with positive exercise tests tended to have more extensive thallium defects (fig 4). Minor abnormalities of wall motion were seen in two patients.

Discussion

Some authors have suggested on empirical grounds that a positive exercise test be included as a necessary diagnostic criterion before patients with chest pain and normal coronary arteriograms can be diagnosed with certainty as having syndrome X, defined as angina due by implication to reduced coronary perfusion reserve at the microvascular level (microvascular angina), as distinct from the much commoner non-cardiac conditions.² The exercise test is nevertheless recognised as having limited specificity and sensitivity¹⁵: we found sensitivity to be 57% ($n = 100$) at a specificity of 75% for angiographically significant coronary disease (unpublished observations). Inclusion of the exercise test may thus underestimate the true prevalence of microvascular angina, which has been estimated on

Segments with defective thallium uptake

Segment	No	Segment	No
A	14	AI	15
Ap	2	PI	8
I	11	AP	19
P	2	PIA	27

A, anterior; Ap, apical; I, inferior; P, posterior.

Figure 3 Extent of thallium defect expressed as % total left ventricle, plotted against the product of heart rate \times systolic blood pressure on exercise (double product).

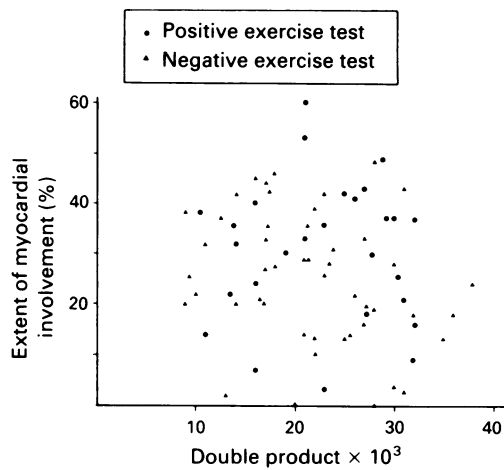
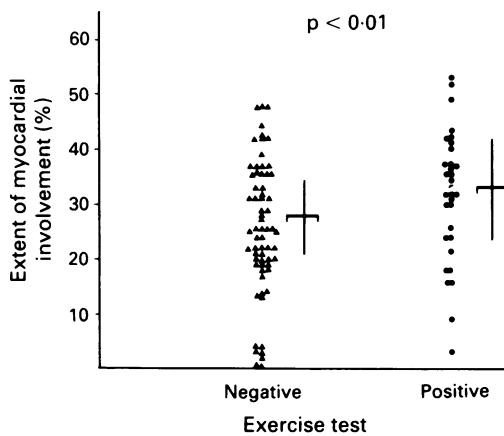


Figure 4 Extent of myocardial involvement in patients with positive and negative exercise tests. The mean is represented by the horizontal bar with the SD shown as vertical bar.



this basis as $<1\%$ of diagnostic coronary arteriograms performed.²

Our experience was that about 10% of diagnostic coronary arteriograms were normal. This is of the same order as the 10%–30% reported by other units.^{4,16} Only 30 of our 100 patients had electrocardiographically positive exercise tests but almost all (98%) had abnormal thallium scans. This high proportion must be viewed in the context of our practice of generally using the thallium scan as a screening test before proceeding to angiography. The distribution of thallium defects was wide with no consistent pattern, and the extent of the defect was not significantly correlated with exercise tolerance or the presence of a positive exercise test.

Impairment of myocardial intracellular uptake of thallium (a potassium analogue) is due generally to impaired perfusion.^{17,18} Gating images to the electrocardiogram improve their predictive accuracy to 91% in respect of significant epicardial coronary disease.¹⁴ Thallium defects were not found in 14 volunteers whose scans were reported after interspersing them blindly among the scans of this patient population. Thallium defects are thus strongly sug-

gestive of critically reduced perfusion. No patients in this series showed evidence of hypertrophy, heart failure, overt hypertension, LBBB, or primary cardiomyopathy, which can be associated with thallium defects¹⁹ and none had diabetes. Artefactual defects due to breast attenuation or relative apical thinning were also excluded. Finding defects in thallium uptake on peak exercise in such a large proportion of the total number of patients undergoing diagnostic coronary arteriography suggests that inducible myocardial dysfunction, consistent with microvascular angina, may be much commoner than has been recognised from less sensitive tests.

- 1 Kemp HG. Left ventricular function in patients with the anginal syndrome and normal coronary arteriograms. *Am J Cardiol* 1973;32:375–6.
- 2 Anonymous. Syndrome X. *Lancet* 1987;ii:1247–8.
- 3 Master AM. The spectrum of angina and non-cardiac chest pain. *JAMA* 1964;187:894–9.
- 4 Dart AN, Alban Davies H, Dalal J, Ruttley M, Henderson AH. "Angina" and normal coronary arteriograms: a follow-up study. *Eur Heart J* 1980;1:97–100.
- 5 Cannon RO, Bonow RO, Bacharach SL, et al. Left ventricular dysfunction in patients with angina pectoris, normal epicardial coronary arteries, and abnormal vasodilator reserve. *Circulation* 1985;71:218–26.
- 6 Legrand V, Hodgson J, Bates E, et al. Abnormal coronary flow reserve and abnormal radionuclide exercise test results in patients with normal coronary angiograms. *J Am Coll Cardiol* 1985;6:1245–53.
- 7 Arbogast R, Bourassa MG. Myocardial function during atrial pacing in patients with angina pectoris and normal coronary arteriograms. *Am J Cardiol* 1973;32:257–63.
- 8 Boudoulas H, Cobb TC, Leighton RF, Wilt SM. Myocardial lactate production in patients with angina-like chest pain and angiographically normal coronary arteries and left ventricle. *Am J Cardiol* 1974;34:501–5.
- 9 Opher D, Zebe H, Weihe E, et al. Reduced coronary dilatory capacity and ultrastructural changes of the myocardium in patients with angina pectoris but normal coronary arteriograms. *Circulation* 1981;63:817–25.
- 10 Greenberg MA, Grose RM, Neuberger N, Silverman R, Strain JE, Cohen MV. Impaired coronary vasodilator reserve as a cause of lactate production during pacing induced ischaemia in patients with angina pectoris and normal coronary arteries. *J Am Coll Cardiol* 1987;9:743–51.
- 11 Cannon RO, Watson RM, Rosing DR, Epstein SE. Angina caused by reduced vasodilator reserve of the small coronary arteries. *J Am Coll Cardiol* 1983;1:1359–73.
- 12 Geltman EM, Henes CG, Senneff MJ, Sobel BE, Bergmann SR. Increased myocardial perfusion at rest and diminished perfusion reserve in patients with angina and angiographically normal coronary arteries. *J Am Coll Cardiol* 1990;16:586–95.
- 13 Cannon RO, Leon MB, Watson RM, Rosing DR, Epstein SE. Chest pain and "normal" coronary arteries—role of small coronary arteries. *Am J Cardiol* 1985;55:50–60B.
- 14 Martin W, Tweddel AC, McGhie AI, Hutton I. Gated thallium scintigraphy in patients with coronary artery disease, an improved planar imaging technique. *Clin Phys Physiol Meas* 1987;8:343–54.
- 15 Epstein SE. Value and estimation of the electrocardiographic response to exercise in the assessment of patients with coronary artery disease. *Am J Cardiol* 1978;42:667–74.
- 16 Proudfit WL, Shirley EK, Jones FM. Selective cine coronary arteriography: correlation with clinical findings in 1000 cases. *Circulation* 1986;33:901–10.
- 17 Berman DS, Garcia EV, Maddahi J, Rozanski A. Thallium 201 myocardial perfusion scintigraphy. In: Freeman LM, ed. *Freeman and Johnson's Clinical Radionuclide Imaging*. 3rd ed. Orlando Grune and Stratton, 1984:479–537.
- 18 Wackers FJ, Fetterman RL, Meltera JA, Clements JP. Quantitative planar thallium 201 stress scintigraphy: a critical evaluation of the method. *Semin Nucl Med* 1985;15:46–66.
- 19 Tweddel AC, Martin W, McGhie I, et al. The value of radionuclide assessment in cardiomyopathy. *Scott Med J* 1985;30:127.