

Outcome from balloon induced coronary artery dissection after intracoronary β radiation

I P Kay, M Sabate, G Van Langenhove, M A Costa, A J Wardeh, A L Gijzel, N V Deshpande, S G Carlier, V L M A Coen, P C Levendag, W Van der Giessen, P J de Feyter, P W Serruys

Abstract

Objective—To evaluate the healing of balloon induced coronary artery dissection in individuals who have received β radiation treatment and to propose a new intravascular ultrasound (IVUS) dissection score to facilitate the comparison of dissection through time.

Design—Retrospective study.

Setting—Tertiary referral centre.

Patients—31 patients with stable angina pectoris, enrolled in the beta energy restenosis trial (BERT-1.5), were included. After excluding those who underwent stent implantation, the evaluable population was 22 patients.

Interventions—Balloon angioplasty and intracoronary radiation followed by quantitative coronary angiography (QCA) and IVUS. Repeat QCA and IVUS were performed at six month follow up.

Main outcome measures—QCA and IVUS evidence of healing of dissection. Dissection classification for angiography was by the National Heart Lung Blood Institute scale. IVUS proven dissection was defined as partial or complete. The following IVUS defined characteristics of dissection were described in the affected coronary segments: length, depth, arc circumference, presence of flap, and dissection score. Dissection was defined as healed when all features of dissection had resolved. The calculated dose of radiation received by the dissected area in those with healed versus non-healed dissection was also compared.

Results—Angiography (type A = 5, B = 7, C = 4) and IVUS proven (partial = 12, complete = 4) dissections were seen in 16 patients following intervention. At six month follow up, six and eight unhealed dissections were seen by angiography (A = 2, B = 4) and IVUS (partial = 7, complete = 1), respectively. The mean IVUS dissection score was 5.2 (range 3–8) following the procedure, and 4.6 (range 3–7) at follow up. No correlation was found between the dose prescribed in the treated area and the presence of unhealed dissection. No change in anginal status was seen despite the presence of unhealed dissection.

Conclusion— β radiation appears to alter the normal healing process, resulting in unhealed dissection in certain individuals. In view of the delayed and abnormal healing observed, long term follow up is indicated given the possible late adverse effects of radiation. Although in this cohort no increase in cardiac events following coronary dissections was seen, larger populations are needed to confirm this phenomenon. Stenting of all coronary dissections may be warranted in patients scheduled for brachytherapy after balloon angioplasty.

(Heart 2000;83:332-337)

Keywords: dissection; intravascular ultrasound; angiography; coronary artery; brachytherapy; angioplasty

Thoraxcenter Bd 418,
University Hospital
Dijkzigt, Dr
Molewaterplein 40,
3015 GD Rotterdam,
The Netherlands

I P Kay
M Sabate
G Van Langenhove
M A Costa
A J Wardeh
A L Gijzel
N V Deshpande
S G Carlier
W Van der Giessen
P J de Feyter
P W Serruys

The Daniel den Hoed,
Cancer Center,
Rotterdam, The
Netherlands
V L M A Coen
P C Levendag

Correspondence to:
Professor Serruys
email: serruys@card.azr.nl

Accepted 12 October 1999

Despite excellent acute results, restenosis at six month follow up after coronary artery balloon angioplasty remains a serious problem.¹ Excessive neointimal formation, extracellular matrix synthesis, and negative vessel remodelling in response to balloon injury have been documented as the main mechanisms of restenosis.¹⁻⁷ Intracoronary radiation treatment has recently emerged as a means of preventing and treating restenosis in coronary arteries treated by balloon angioplasty. The theoretical benefit of radiation in preventing neointimal proliferation resides in the destruction of more rapidly dividing smooth muscle cells.⁸⁻¹⁴ It may not be surprising that by inhibiting the above deleterious features of healing after balloon angioplasty, intracoronary radiation may also alter normal healing processes.

Coronary artery dissection is common after balloon angioplasty. This is angiographically visible in 20–45% of cases following balloon angioplasty¹⁵ and present in up to 85% of cases when intravascular ultrasound (IVUS) assess-

ment is used.¹⁶ If further angioplasty of the lesion is not undertaken, then it is recognised that nearly all angiographic dissection will heal over a six month time frame.¹⁵⁻¹⁷ Whether intracoronary radiation will prevent the process of natural healing after balloon induced dissection has not been documented thus far in humans. To examine this, we retrospectively analysed coronary artery dissections using angiography and IVUS, at the time of treatment and at six month follow up, in patients treated with intracoronary radiation following balloon angioplasty. We also aimed to compare the prescribed dose received by the treated area in individuals with non-healing dissection with the dose received by those individuals with healed dissection.

Methods

PATIENT SELECTION

Patients eligible for the study were those treated successfully with balloon angioplasty followed by intracoronary irradiation according

Table 1 IVUS dissection score

Arc	Length	Depth	Flap
< 90° = 1	< 5 mm = 1	Partial = 1	Yes = 1
90–180° = 2	5–10 mm = 2	Complete = 2	No = 0
> 180° = 3	> 10mm = 3		

Table 2 Baseline characteristics (n = 22)

Mean (SD) age (years)	55.7 (9.3)
Coronary risk factors	
Smoking (n (%))	15 (68)
Hypercholesterolaemia (n (%))	12 (55)
Family history (n (%))	12 (55)
Hypertension (n (%))	11 (50)
Diabetes (n (%))	6 (26)
Treated vessel	
LAD (n (%))	12 (55)
LCX (n (%))	6 (26)
RCA (n (%))	4 (18)
Prescribed dose	
16 Gy (n (%))	9 (41)
14 Gy (n (%))	5 (23)
12 Gy (n (%))	8 (36)

LAD, left anterior descending coronary artery; LCX, left circumflex coronary artery; RCA, right coronary artery.

to the beta energy restenosis trial (BERT-1.5). The purpose of this trial was to evaluate the safety and efficacy of low dose β source irradiation following balloon angioplasty with and without stent implantation in patients with single “de novo” lesions of native coronary arteries. The design of this trial was a prospective multicentre non-randomised feasibility study. We used a strontium 90 (^{90}Sr) source with yttrium as a pure β emitter, and patients were randomised to receive 12, 14, or 16 Gray (Gy). The inclusion and exclusion criteria of this trial have been previously reported.¹⁴

RADIATION DELIVERY SYSTEM

The Beta-Cath system (Novoste Corp, Norcross, Georgia, USA) was used to deliver localised β radiation to a coronary artery at the site of coronary intervention. The device consists of three components: (1) the transfer device which stores the radiation source train and allows the positioning of these sources within the catheter; (2) the delivery catheter, which is a 5 F multilumen over the wire non-centred catheter which uses saline solution to send and return the radiation source train; and (3), the radiation source train consisting of a series of 12 independent cylindrical seeds which con-

tain the radioisotope ^{90}Sr sources and is bordered by two gold radiopaque markers separated by 30 mm.¹⁸

IVUS IMAGE ACQUISITION ANALYSIS SYSTEM

The segment subject to analysis was examined with a mechanical IVUS system (ClearView, CardioVascular Imaging System (CVIS), Sunnyvale, California, USA) with a sheath based IVUS catheter incorporating a 30 MHz single element transducer rotating at 1800 rpm. The transducer is placed inside a 2.9 F 15 cm long sonolucent distal sheath which alternatively houses the guidewire (during the catheter introduction) or the transducer (during imaging, after the guidewire has been pulled back). To assure the correct identification and analysis of the irradiated segment, certain steps were followed. First, an angiogram was performed after positioning the delivery catheter, and the relation between anatomical landmarks and the two gold markers was noted. Typically, the aorto-ostial junction and the side branches were used as landmarks. The landmark closest to either of the gold markers was used as a guide. During the motorised IVUS pullback, all side branches were counted and the guiding landmark was identified. The correct selection of the marker was confirmed by visualising the position of the IVUS probe during a contrast injection. Once the acquisition was completed, we selected the segment of interest by taking the digitised cross-sectional images proximal or distal to the guiding landmark up to 30 mm, which is the area encompassed by the two gold markers of the radiation source. At follow up, we selected the same region of interest and compared it with that after treatment.

PROCEDURE

The medical ethics committee of the Erasmus Medical Center, Rotterdam approved the study and all patients signed a written informed consent form. In the BERT-1.5 trial balloon angioplasty was performed according to standard clinical practice. Following successful angioplasty, patients were randomised to receive 12, 14, or 16 Gy, as calculated at 2 mm from the centre of the radiation source. The 5 F delivery catheter of the Beta-Cath

Table 3 Angiographic parameters pre- and postintervention and at six month follow up for patients with dissection

Patient	Dose prescribed	Pre-procedure		Postprocedure			Follow up				
		MLD	Dissection grade	RD	DS (%)	MLD	Dissection grade	RD	DS (%)	MLD	LLI
1	12	0.77	C	2.58	40	1.56	–	2.41	32	1.63	–0.09
2	14	1.23	A	2.72	17	2.25	–	2.84	8	2.60	–0.34
3	12	0.78	B	2.44	26	1.80	–	2.77	36	1.77	0.02
4	12	0.78	B	3.17	31	2.18	–	3.11	44	1.75	0.31
5	14	1.21	B	3.21	34	2.12	B	3.32	35	2.15	–0.03
6	16	0.82	A	2.73	30	1.92	A	3.01	52	1.44	0.44
7	16	0.96	B	2.40	23	1.85	B	2.04	23	1.58	0.31
8	16	1.42	C	2.82	25	2.12	–	2.96	51	1.44	0.97
9	16	0.88	C	2.18	29	1.54	–	2.16	49	1.10	0.67
10	16	1.31	C	3.98	38	2.45	A	3.25	54	1.50	0.83
12	12	1.06	A	2.62	3	2.54	–	3.21	75	0.81	1.17
13	12	1.17	A	2.82	29	2.00	–	3.27	65	1.14	1.04
16	16	1.33	B	3.21	22	2.49	B	3.39	31	2.35	0.12
17	14	1.36	B	2.49	25	1.87	–	2.79	13	2.44	–1.14
19	12	0.61	B	2.68	21	2.12	B	2.80	31	1.94	0.12
20	12	1.70	A	4.69	44	2.63	–	3.86	29	2.75	–0.13
Mean	13.9	1.09		2.92	27.31	2.09		2.95	39.25	1.77	0.27

MLD, minimal luminal diameter; RD, reference diameter; DS, diameter stenosis; LLI, late loss index.

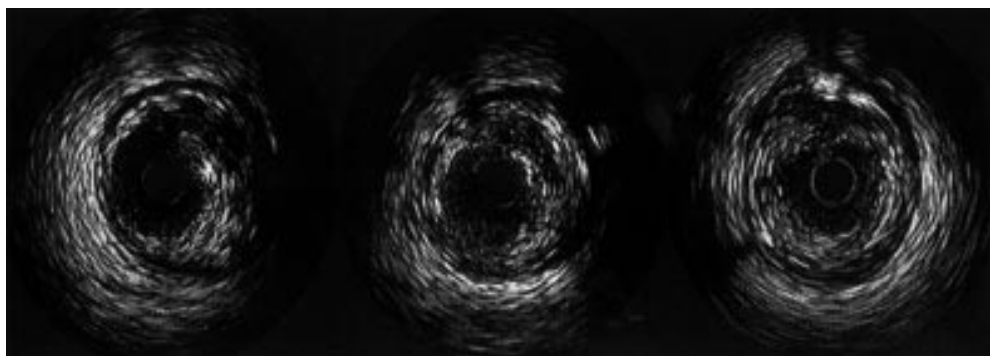


Figure 1 Intravascular ultrasound images (left and centre) showing a double lumen between 12 and 3 o'clock postintervention. The right image shows the same lesion at six month follow up with the unhealed false lumen seen between 11 and 2 o'clock.

system was inserted over the guidewire and advanced such that the two marker bands encompassed the angioplasty site. The guidewire was removed and the radiation source train containing 12 ^{90}Sr seeds was positioned between the gold markers using fluoroscopic visualisation. The seeds remained in place for 2.5–3.5 minutes to deliver the assigned dose of radiation. Following irradiation, repeat angiography and IVUS pullback were performed. Intracoronary nitrates were administered before the treated artery was examined with IVUS. The 2.9 F IVUS catheter (CVIS, Sunnyvale) was advanced distal to the treated site. A continuous motorised pullback at a speed of 0.5 mm/s was carried out, followed by an angiographic control. At six month angiographic follow up, identical quantitative coronary angiography (QCA) and IVUS examination of the treated area was performed.

DEFINITIONS

Dissection was defined both angiographically and by IVUS. Angiographic dissection was defined using the National Heart Lung and Blood Institute criteria for the classification of dissection.¹⁹ QCA analysis was performed before the intervention, after treatment, and at six month follow up using identical gantry positions. Coronary angiography was performed after intracoronary administration of nitrates. The offline analysis of at least two orthogonal projections was performed by means of the cardiovascular angiography analysis system (CAAS II, Pie Medical BV, Maastricht, The Netherlands). Calibration of the system was based on dimensions of the catheters not filled with contrast medium. This method of analysis has been previously validated.^{20–22} The following measurements were obtained in each projection: minimal luminal diameter (MLD), reference diameter, % diameter stenosis, and lesion length. Lesion length was user defined and not done by an algorithm using curvature analysis of the diameter function. The reference diameter was obtained by an interpolated method. Acute gain was defined as MLD measured after treatment minus MLD preintervention. Late loss was defined as MLD after treatment minus MLD at follow up. Late loss index was defined as late loss divided by acute gain. Restenosis was defined as > 50% diameter stenosis at follow up and located within the treated area.

IVUS dissection was defined as a longitudinal tear parallel to the vessel wall.¹⁶ In all patients with IVUS detected dissection, length, arc, and depth were recorded. For inclusion in the study all dissections were located within the area treated by radiation. Axial length was measured in millimetres. Circumferential extension was measured as an arc in degrees. The maximal depth of wall disruption was defined as follows: partial—plaque between tear and adventitia; complete—full thickness tear extending through the plaque to the adventitia.¹⁶

An IVUS dissection score was created to rank the severity of dissection (table 1). This score facilitates comparison of dissection after the procedure and at follow up. Assuming that a dissection is present, the potential range of the dissection score was 3–9. The dissection was considered to be healed when all features

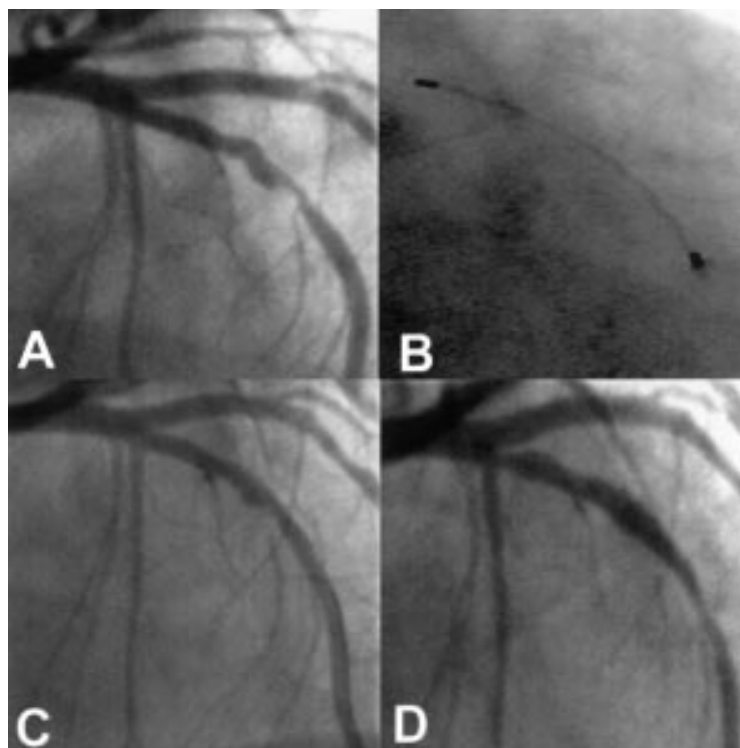


Figure 2 Coronary angiogram showing: (A) lesion pretreatment; (B) radioactive source in situ; (C) postintervention; and (D) the same lesion at six month follow up. Note the presence of an edge effect and absence of angiographic dissection at six month follow up.

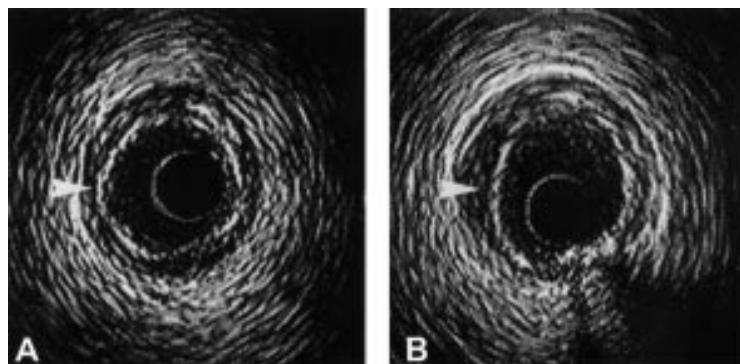


Figure 3 This IVUS image correlates with the angiogram in fig 2. The arrowheads show the presence of an intact lumen (A) and an unhealed flap (B), corresponding to the same area.

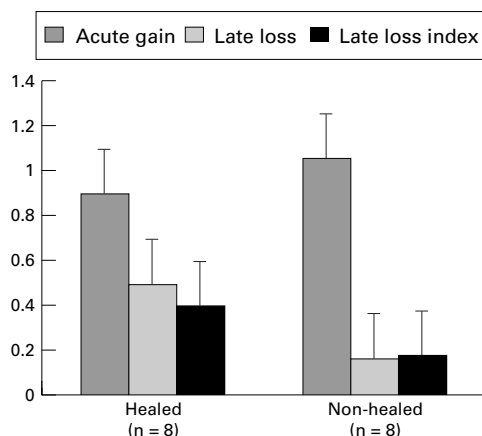


Figure 4 QCA analysis of healed versus non-healed dissection ($p = NS$).

of dissection had disappeared. Partial healing was considered to have occurred when at least one feature of dissection persisted at follow up. Absence of healing was defined as no change to the dissection on follow up.

The prescribed radiation dose delivered to 2 mm from the source was recorded and compared between individuals with and without healed dissection.

STATISTICAL ANALYSIS

Quantitative data are presented as mean (SD). The non-paired two tailed Student's *t* test was

used to compare dose levels and healed/non-healed dissection.

Results

BASELINE CHARACTERISTICS

From April to December 1997, 31 patients were treated at our institution according to the BERT 1.5 trial. Eight patients, who received stent implantation because of important recoil or angiographic and IVUS proven dissection after balloon angioplasty, were excluded from the assessment. One patient refused IVUS at follow up; the same patient had no evidence of dissection following treatment. Therefore the study population was 22 patients. The baseline characteristics of the patients are shown in table 2.

CLINICAL, ANGIOGRAPHIC, AND IVUS FOLLOW UP

At follow up 14 patients (63%) remained asymptomatic. Six patients presented with stable angina pectoris: one with Canadian Cardiovascular Society (CCS) class 1 angina, one with CCS class 2, and four with CCS class 3. The follow up angiography demonstrated restenosis (> 50% diameter stenosis on quantitative coronary angiography) in five patients (24%). These included the four patients with CCS class 3 angina. One restenotic patient showed aneurysmatic formation within the irradiated area. The prescribed dose in restenotic patients was 12 Gy in one patient, 14 Gy in one patient, and 16 Gy in three patients.

Dissection was seen in 16/22 patients (73%) after intervention using both angiographic and IVUS criteria. At six month follow up dissection was seen in six patients on angiography (38%) and eight patients on IVUS (50%) (table 3). Disagreement between IVUS and angiography was caused by the presence of a double lumen in one individual (fig 1) and a flap in another (figs 2 and 3), neither of which was detected by angiography. Angiographic analysis of healed versus non-healed dissection is presented in fig 4. No difference was seen in the reference diameter, % diameter stenosis, and MLD before or after the procedure or at follow up for either the healed or the non-healed dissection groups (table 3). As

Table 4 Postintervention and six month follow up of dissection evaluated by IVUS

Patient	Postintervention					Follow up				
	Arc	Length (mm)	Depth	Flap	IVUS score	Arc	Length (mm)	Depth	Flap	IVUS score
1	60°	5	P	N	4	60°	5	P	N	4
2	45°	2	P	N	3	-	-	-	-	-
3	90°	5	C	N	6	-	-	-	-	-
4	60°	5	P	N	4	30°	2	P	N	3
5	90°	5	P	N	5	30°	2	P	N	3
6	180°	2	C	Y	7	180°	2	C	Y	7
7	90°	6	P	Y	6	-	-	-	-	-
8	120°	8	P	N	5	-	-	-	-	-
9	180°	3	P	N	5	180°	3	P	N	5
10	270°	25	C	N	8	-	-	-	-	-
12	90°	4	P	N	4	-	-	-	-	-
13	90°	6	P	N	5	-	-	-	-	-
16	90°	7	P	N	5	90°	5	P	N	5
17	120°	6	C	N	6	-	-	-	-	-
19	90°	7	P	N	5	90°	5	P	N	5
20	120°	3	P	Y	5	120°	3	P	Y	5
Mean	112°	6.2	P = 12/16	N = 13/16	5.2	98°	3.4	P = 7/8	N = 6/8	4.6

P, partial; C, complete; N, no; Y, yes

expected late loss and late loss index were greater in the healed dissection group, but the difference was not significant. Eight patients had persisting dissection after IVUS examination—six had no evidence of healing and two had partial healing (table 4). Three of the healed dissections resulted in restenosis. The mean IVUS dissection score was 5.2 (range 3–8) after the procedure and 4.6 (range 3–7) at follow up. IVUS healed dissection received a mean prescribed dose of 14 Gy and non-healed dissection received 13.8 Gy (p value not significant).

Discussion

We describe coronary artery dissection following intracoronary radiation treatment in a group of individuals who had dissection noted angiographically and with IVUS, but who did not undergo stent implantation as the lesion appeared stable under standard clinical conditions. These dissections were not associated with any significant acute or subacute clinical sequelae. What is remarkable is that after six month follow up, six of the angiographic dissections and eight of the IVUS proven dissections persisted. In a similar patient population who had undergone conventional balloon angioplasty (n = 183), 87 patients (47%) suffered a type A–C dissection after coronary angioplasty. Only one dissection persisted at six month follow up coronary angiography (DEBATE 1 subanalysis, unpublished data, 1999).

Why should these dissections fail to heal in a predictable manner as previously described in conventional angioplasty? In an experimental model, a reduction of cell proliferation in the media and adventitia has been observed in the early phase after balloon injury and radiation treatment. Furthermore, the expression of α smooth muscle actin in the adventitia is reduced after radiation treatment, suggesting a positive effect on vascular remodelling.²³ Consequently it appears that radiation treatment is directly implicated in altering the healing process after balloon angioplasty, increasing the potential for positive remodelling,²⁴ arterial dilatation, and non-healing dissection.

It remains uncertain as to whether the dissections described represent permanent disruptions to the vessel wall or merely a retardation in the healing process. The possible inhibitory healing effect of radiation may diminish with time such that at a critical point there may be a further activation of the restenotic process associated with the healing of the dissection.

In an animal model, Farb and colleagues showed a reduction in neointimal formation in ³²P-emitting radioactive stents three months after implantation; endothelialisation was incomplete, however, with only one third of the entire intimal surface showing endothelialisation with poor formation of cell junctions.²⁵ As a result of incomplete or delayed endothelialisation, late thrombosis may also occur among the described dissections. It therefore would be of considerable interest to repeat IVUS assessment of individuals undergoing intracoronary

radiation treatment at a later date (12–18 months postintervention) so as to see if there is evidence of persisting dissection or of wound healing/restenosis, which may present in a delayed fashion.²⁶

Although the dissections did not lead to an increase of cardiac events in our population, Preisack and colleagues recently described a higher event rate in patients who suffered coronary dissections after balloon dilatation only.²⁷ In this study, the dissection type was highly correlated with the probability of a clinical event. Other authors have not found a difference in six month clinical event rate in patients with stable coronary dissections.²⁸

We feel that additional stent implantation may be justified in patients with dissections who are about to receive brachytherapy following balloon angioplasty. This approach may be warranted even if the dissection is stable. After stent implantation in these circumstances, we feel that a long term antiplatelet regimen (> 3 months) may prove helpful in the prevention of late thrombotic occlusion, given re-endothelialisation seems to be delayed in this patient cohort.

There have been no reports on γ radiation causing interference with the healing of dissection. Compared with γ radiation a higher dose of β energy is required in the near field to deliver the prescribed dose to 2 mm. This intrinsic feature of β radiation may be causing the deleterious effect witnessed.

The IVUS dissection score was created to obtain a means of ranking and comparing dissection between postprocedural and follow up features. Up to this point, there has been no system that employs the well described features of dissection (arc, length, depth, and presence of flap) to create such a ranking. Clearly, the fate at six month follow up of IVUS proven postprocedural dissection is not well described and we must rely on evidence that is extracted from angiographic follow up data. An IVUS ranking system may be useful to describe the fate at follow up of dissection not only in the context of normal balloon angioplasty, but also after intracoronary radiotherapy.

Using the prescribed dose delivered to the total treated area there was no difference between the dose prescribed and the presence of non-healing dissection. On the one hand this relation may be genuine, on the other it may be argued that this lack of correlation results from the use of the measure of radiation received by the total vessel; this may not reflect the radiation dose received by the specific area of dissection,²⁹ or the radiation which is potentially transmitted down the disrupted tissue planes of the dissection. It is possible that such tissue planes may permit greater passage of radiation with deleterious consequences such non-healing or aneurysmal change. Equally, it is possible that certain tissue characteristics, such as heavy calcification, may interrupt radiation dosing to the level of the adventitia. Clearly, IVUS provides superior information to angiography in describing tissue characteristics and is likely to be an integral part in the calculation of appropriate radiation dose in the

future,²⁹ so as to maximise efficacy and minimise the complications of over- and underdosing.

The design of the radioactive source delivery catheter may also be relevant to its efficacy. A non-centred catheter as used in this study may lead to inhomogeneous dosing. Alternative centred devices are available; however, the issue is as yet unresolved and will be the subject of further research.³⁰

LIMITATIONS

We describe the phenomenon of non-healing coronary artery dissection after balloon angioplasty in a small group of patients. The outcome of dissection in those with flow limiting dissection has not been defined, as these individuals all had stents implanted. The angiographic dissection control group for this study is historical and there is no good description in the literature on the long term outcome of those with IVUS proven dissection.

CONCLUSION

β Radiation alters the normal healing process, resulting in unhealed dissection in certain individuals. In view of the delayed and abnormal healing witnessed, long term follow up may be prudent. Although no increase in cardiac events at six months following coronary dissection was seen in this cohort, larger populations are needed to confirm this phenomenon. Stenting of all coronary dissections and the use of prolonged courses of antiplatelet agents may be warranted in patients scheduled for brachytherapy following balloon angioplasty.

The Wenckebach prize was awarded to PW Serruys by the Dutch Heart Foundation for brachytherapy research in the catheterisation laboratory. The authors appreciate the efforts of the catheterisation and radiation laboratory staff. Dr Kay is supported by the National Heart Foundation of New Zealand.

- 1 Califf RM, Fortin DF, Frid DJ, *et al.* Restenosis after coronary angioplasty: an overview. *J Am Coll Cardiol* 1991;17:2-13B.
- 2 Nobuyoshi M, Kimura T, Nosaka H, *et al.* Restenosis after successful percutaneous transluminal coronary angioplasty: serial angiographic follow-up of 229 patients. *J Am Coll Cardiol* 1988;12:616-23.
- 3 Steele PM, Chesebro JH, Stanson AW, *et al.* Balloon angioplasty: natural history of the pathophysiological response to injury in a pig model. *Circ Res* 1985;57:105-12.
- 4 Schwartz RS, Huber KC, Murphy JG, *et al.* Restenosis and the proportional neointimal response to coronary artery injury: results in a porcine model. *J Am Coll Cardiol* 1992;19:418-32.
- 5 Muller DW, Ellis SG, Topol EJ. Experimental models of coronary artery restenosis. *J Am Coll Cardiol* 1992;19:418-32.
- 6 Nobuyoshi M, Kimura T, Oshishi H, *et al.* Restenosis after percutaneous transluminal coronary angioplasty: pathologic observations in 20 patients. *J Am Coll Cardiol* 1991;17:433-9.
- 7 Post MJ, Borst C, Kuntz RE. The relative importance of arterial remodelling compared with intimal hyperplasia in lumen renarrowing after balloon angioplasty: a study in the normal rabbit and the hypercholesterolemic Yucatan micropig. *Circulation* 1994;89:2816-21.
- 8 Waksman R, Robinson KA, Crocker IA, *et al.* Intracoronary low-dose-irradiation inhibits neointima formation after coronary artery balloon injury in the swine restenosis model. *Circulation* 1995;92:3025-31.
- 9 Verin V, Popowski Y, Urban P, *et al.* Intraarterial beta irradiation prevents neointimal hyperplasia in a hypercholesterolemic rabbit restenosis model. *Circulation* 1995;92:2284-90.
- 10 Waksman R, Robinson KA, Crocker IR, *et al.* Endovascular low-dose irradiation inhibits neointima formation after coronary artery balloon injury in swine. A possible role for radiation therapy in restenosis prevention. *Circulation* 1995;91:1553-9.
- 11 Mazur W, Ali MN, Khan MM, *et al.* High dose rate intracoronary radiation for inhibition of neointimal formation in the stented and balloon-injured porcine models of restenosis: angiographic, morphometric, and histopathologic analyses. *Int J Radiat Oncol Biol Phys* 1996;36:777-88.
- 12 Wiederman JG, Marboe C, *et al.* Intracoronary irradiation markedly reduces restenosis after balloon angioplasty in a porcine model. *J Am Coll Cardiol* 1994;23:1491-8.
- 13 Condado JA, Waksman R, Gurdziel O, *et al.* Long-term angiographic and clinical outcome after percutaneous transluminal coronary angioplasty and intracoronary radiation therapy in humans. *Circulation* 1997;96:727-32.
- 14 King SB III, Williams DO, Chogule P, *et al.* Endovascular β -radiation to reduce restenosis after coronary balloon angioplasty. Results of the beta energy restenosis trial (BERT). *Circulation* 1998;97:2025-30.
- 15 Hermans WRM, Rensing BJ, Foley DP, *et al.* Therapeutic dissection after successful coronary balloon angioplasty: No influence on restenosis or on clinical outcome in 693 patients. *J Am Coll Cardiol* 1992;20:767-80.
- 16 Di Mario C, Gorge G, Peters R, *et al.* Clinical application and image interpretation in intracoronary ultrasound. *Eur Heart J* 1998;19:207-29.
- 17 Alfonso F, Hernandez R, Goicolea J, *et al.* Coronary stenting for acute coronary dissection after coronary angioplasty: implications of residual dissection. *J Am Coll Cardiol* 1994;24:789-95.
- 18 Hillstead RA, Johnson CR, Weldon TD. The Beta-Cath system. In: Waksman R, Serruys PW, eds. *Handbook of vascular brachytherapy*. London: Martin Dunitz, 1998.
- 19 Huber MS, Mooney JF, Madison J, *et al.* Use of a morphological classification to predict clinical outcome after dissection from coronary angioplasty. *Am J Cardiol* 1991;68:467-71.
- 20 Haase J, Escaned J, van Swijndregt EM, *et al.* Experimental validation of geometric and densitometric coronary measurements on the new generation cardiovascular angiography analysis system (CAAS II). *Cathet Cardiovasc Diagn* 1993;30:104-14.
- 21 Di Mario C, Hermans WR, Rensing BJ, *et al.* Calibration using angiographic catheters as scaling devices—importance of filming the catheters not filled with contrast medium [letter; comment]. *Am J Cardiol* 1992;69:1377-8.
- 22 Serruys PW, Foley DP, de Feyter PJ. *Quantitative coronary angiography in clinical practice*. Dordrecht/Boston/London: Kluwer Academic Publishers, 1994.
- 23 Wilcox JH, Waksman R, King SB III, *et al.* The role of the adventitia in the arterial response to angioplasty: the effect of intravascular radiation. *Int J Radiat Oncol Biol Phys* 1996;36:789-96.
- 24 Sabate M, Serruys PW, van der Giessen WJ, *et al.* Geometric vascular remodelling after balloon angioplasty and β -radiation therapy: a three dimensional intravascular ultrasound study. *Circulation* 1999;100:1182-8.
- 25 Farb A, Tang A, Virmani R. The neointima is reduced but endothelialisation is incomplete 3 months after ³²P β -emitting stent placement [abstract]. *Circulation* 1998;98(suppl):I-779.
- 26 Brenner DJ, Miller RC, Hall EJ. The radiobiology of intravascular irradiation. *Int J Radiat Oncol Biol Phys* 1996;36:805-10.
- 27 Preisack MB, Elsenberger R, Athanasiadis A, *et al.* The influence of coronary artery dissection on long-term outcome after percutaneous transluminal coronary angioplasty. *Z Kardiol* 1998;87:41-50.
- 28 Kobayashi N, De Gregorio J, Adamian M, *et al.* New approaches to evaluate coronary dissections post coronary intervention: all dissections are not malignant. *J Am Coll Cardiol* 1999;33(suppl A):71A.
- 29 Carlier SG, Marijnissen JPA, Visser AG, *et al.* Guidance of intracoronary radiation therapy based on dose-volume histograms derived from quantitative intravascular ultrasound. *IEEE Trans Med Imaging* 1998;17:772-8.
- 30 Waksman R, Serruys PW. *Handbook of vascular brachytherapy*. London: Martin Dunitz, 1998:53-8.