

## SCIENTIFIC LETTER

# Endogenous, local, vascular endothelial growth factor production in patients with chronic total coronary artery occlusions: further evidence for its role in angiogenesis

H El-Gendi, A G Violaris, R Foale, H S Sharma, D J Sheridan

Heart 2002;87:158–159

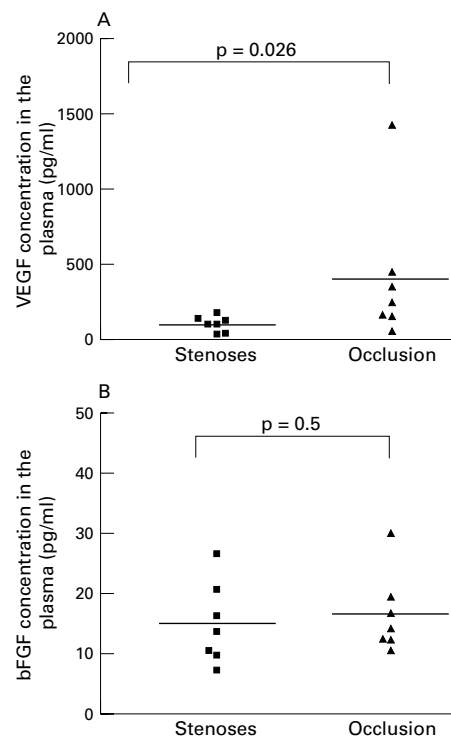
Growth factors are currently emerging as a new therapeutic tool in coronary heart disease.<sup>1</sup> Endogenous expression patterns of a number of angiogenic growth factors have been described in the chronically ischaemic and collateralised hearts.<sup>2</sup> Through their proven experimental angiogenic effect, the administration of vascular endothelial growth factor (VEGF)<sup>3</sup> and basic fibroblast growth factor (bFGF)<sup>4</sup> have been explored as a means of increasing the degree of collateralisation in patients with end stage coronary heart disease. Questions remain however on the optimal dose, duration of administration, and monitoring of these agents<sup>1–3</sup> as well as on the magnitude of risk posed by angiogenic cytokine treatment for accelerating atherosclerosis,<sup>4,5</sup> partly because of the paucity of data on local growth factor concentrations and changes in living man. Patients with total coronary artery occlusions are known to have more developed collateral circulation compared to patients with stenosis and consequently, we hypothesised, that they may represent the ideal human model to examine endogenous, local growth factor production in vivo.

## METHODS

Endogenous VEGF and bFGF concentrations were prospectively examined in the coronary circulation and periphery of 14 male patients (seven with mean (SEM) diameter stenosis 83 (6)%, mean age 63 (2.4), and a further seven with total coronary artery occlusion, mean age 64 (4.4)) undergoing elective left coronary system intervention. Local (coronary sinus) and systemic (femoral) venous samples were obtained before coronary intervention and blood samples were centrifuged, plasma separated and stored at  $-80^{\circ}\text{C}$  for further analysis. The concentrations of VEGF and bFGF in the plasma was then determined using an enzyme linked immunosorbent assay (ELISA) (R&D Systems Europe Ltd, UK). All data were analysed using the GraphPad Prism statistical software package (GraphPad Software, San Diego, California, USA). The non-parametric Mann-Whitney U test was used. Two tailed values of  $p < 0.05$  were considered significant.

## RESULTS

There was a difference between local and systemic concentrations of VEGF in the whole cohort of patients (251.8 (94.8)  $\nu$  93.6 (14.1) pg/ml, respectively,  $p = 0.07$ ). The difference was chiefly attributable to a fourfold increase in local VEGF concentrations in the occlusion group (400.2 (176.7)  $\nu$  111.9 (22.9) pg/ml,  $p = 0.07$ ) compared to the stenosis group (103.3 (19.8)  $\nu$  75.2 (15.1) pg/ml,  $p = 0.5$ ). The basal VEGF concentrations were significantly higher in the coronary sinus samples of patients with occlusions compared to those with stenoses (400.2 (176.7)  $\nu$  103.3 (19.8) pg/ml,  $p = 0.026$ ) (fig 1A). In contrast, no significant differences between local and systemic concentrations of bFGF for either the whole cohort of patients (15.7 (1.7)  $\nu$  12.7 (1.0) pg/ml, respectively,  $p = 0.17$ ),



**Figure 1** (A) Plasma vascular endothelial growth factor (VEGF) concentration in the coronary sinus, in patients with occlusion versus stenosis. (B) Plasma basic fibroblast growth factor (bFGF) concentration in the coronary sinus, in patients with occlusion versus stenoses.

patients with occlusions (16.3 (2.5)  $\nu$  12.5 (1.0) pg/ml,  $p = 0.26$ ), or patients with stenoses (15.1 (2.5)  $\nu$  12.9 (1.7) pg/ml,  $p = 0.54$ ) were observed. The basal bFGF concentrations were not different in the coronary sinus samples of patients with occlusions compared to those with stenoses (16.3 (2.5)  $\nu$  15.1 (2.5) pg/ml,  $p = 0.53$ ) (fig 1B).

## DISCUSSION

Our study provides the first direct evidence for increased local VEGF but not bFGF production in the diseased coronary circulation. The high concentrations of local, endogenous production and secretion of VEGF in patients with total coronary occlusions suggest a potential paracrine role for this growth

**Abbreviations:** bFGF, basic fibroblast growth factor; ELISA, enzyme linked immunosorbent assay; VEGF, vascular endothelial growth factor

factor in pathophysiologic collateral formation and supports its use as a therapeutic tool for angiogenesis, particularly in patients with inoperable coronary heart disease. The lack of any increase in local concentrations of bFGF could be attributed to impaired secretion caused by the absence of signal peptide in this growth factor and/or its restricted participation in local angiogenesis as compared to VEGF. In addition our methodology can potentially be extended to provide further insight into the dose, duration of administration, side effects, and long term monitoring of this promising method of treatment for end stage coronary heart disease.

.....  
**Authors' affiliations**

**H El-Genidi, A G Violaris, R Foale, D J Sheridan**, Division of National Heart and Lung Institute, St Mary's Hospital, Academic Cardiology Unit, London, UK  
**H S Sharma**, Erasmus University Medical Center, Rotterdam, The Netherlands

Correspondence to: Dr AG Violaris, Academic Cardiology Unit, 10th

Floor QEQM Wing, St Mary's Hospital, Paddington W2 1NY, UK; d.sheridan@ic.ac.uk

Accepted 19 September 2001

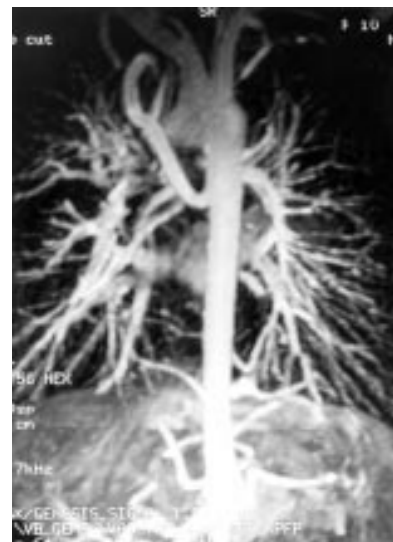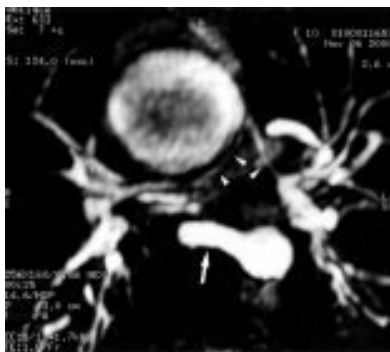**REFERENCES**

- 1 **Schumacher B**, Pecher P, von Specht BU, *et al*. Induction of neoangiogenesis in ischaemic myocardium by human growth factors: first clinical results of a new treatment of coronary heart disease. *Circulation* 1998;**97**:645–50.
- 2 **Sharma HS**, Zimmermann R. Growth factors and development of coronary collaterals. In: Cummins P, ed. *Growth factors and the cardiovascular system*. Boston: Kluwer Academic Publishers, 1993:119–48.
- 3 **Losordo DW**, Vale PR, Symes JF, *et al*. Gene therapy for myocardial angiogenesis: initial clinical results with direct myocardial injection of phVEGF 165 as sole therapy for myocardial ischaemia. *Circulation* 1998;**98**:2800–4.
- 4 **Lazarous DF**, Shou M, Scheinowitz M, *et al*. Comparative effects of basic fibroblast growth factor and vascular endothelial growth factor on coronary collateral development and the arterial response to injury. *Circulation* 1996;**94**:1074–82.
- 5 **Isner JM**. Cancer and atherosclerosis: the broad mandate of angiogenesis. *Circulation*. 1999;**99**:1653–5.

**IMAGES IN CARDIOLOGY**.....

**Evaluation of pulmonary atresia with magnetic resonance imaging**

**A** 10 year old girl was re-evaluated for pulmonary atresia with ventricular septal defect. She had not undergone previous surgical intervention. Clinically she presented with well tolerated cyanosis. On her previous blood test, the red blood cell count was  $7.4 \times 10^{12}/l$  and haematocrit was 68%. Cardiac catheterisation was performed to evaluate both central pulmonary arteries and major aortopulmonary collateral arteries (MAPCA). MAPCA were well depicted but the hypoplastic central pulmonary arteries were not visualised. Three dimensional gradient echo contrast enhanced magnetic resonance angiography was then performed, using breath holding acquisition. On axial transverse reconstructions (thick slab maximum intensity projection or MIP), magnetic resonance imaging was able to detect the course of the central pulmonary main arteries, and showed the presence of the main trunk (arrow heads in left panel). In addition, right MAPCA origin was also seen in the same axial plane (straight arrow). A projectional aortogram provides excellent definition of the pulmonary vascular supply (right panel). Because the patient was clinically well, it was decided not to proceed with surgical intervention at the present time.



**J Baque**  
**J-F Paul**  
 baquej@yahoo.fr