

IMAGES IN CARDIOLOGY

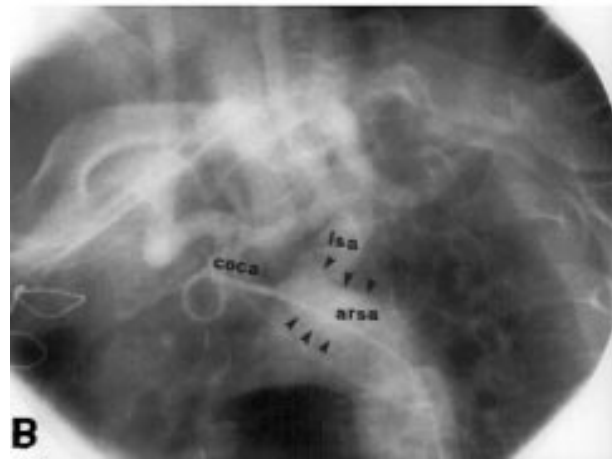
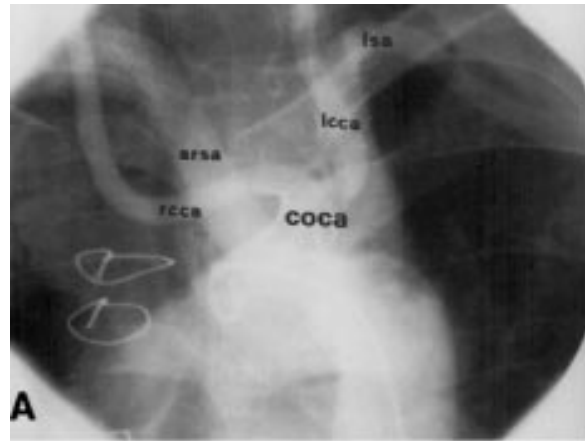Angiographic evidence of aberrant right subclavian artery associated with common carotid trunk

A 56 old man was referred for cardiac catheterisation because of effort angina for the previous few days. He had a history of ischaemic heart disease and had undergone coronary artery bypass graft surgery 12 years earlier. The left internal mammary artery (LIMA) was used for anterior descending grafting. The patient had a sinus rhythm of 85 beats/min and normal QRST complexes. The treadmill test was negative. Coronary arteriography was performed. The right coronary artery and left circumflex artery were free of significant lesions. The left anterior descending artery was severely narrowed in the middle tract.

Because of difficulty in selectively cannulating the left subclavian artery, aortography was performed. The left oblique view (A) revealed a common origin for the carotid arteries (COCA). The lateral view (B) showed, from left to right, an aberrant right subclavian artery (arteria lusoria, ARSA) arising from distal aortic arch, coursing to the right behind the trachea and oesophagus, the left subclavian artery, and finally the common carotid trunk (COCA). Selective LIMA angiography revealed the patency of the graft.

Anomalies of the aortic arch and its branches may cause compression of the trachea and oesophagus or simply yield anatomic patterns which vary from the normal, without causing specific symptoms. This patient did not report stridor or dyspnoea and no other associated anomaly was observed. This is a rare case of combined anomalies of the aortic arch that has not been described angiographically before.

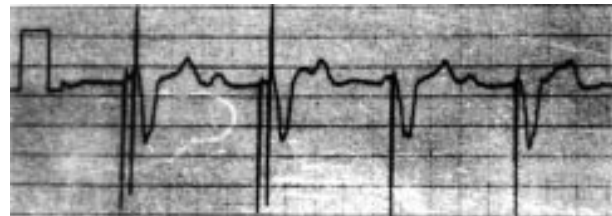
M Fineschi
A Iadanza
G Sinicropi
C Pierli
orfine@tin.it



Autocapture stimulus simulating atrioventricular sequential pacing

This ECG was obtained from a patient on VVI pacemaker with autocapture function. The ECG shows two pacemaker spikes simulating dual chamber pacing.

Pacemakers with autocapture function automatically adjust the stimulation output of the pacemaker to changes in stimulation threshold of the heart, decreasing energy consumption. It verifies every single stimulus by monitoring the evoked response signal from myocardial depolarisation; it also increases patient safety by delivering a high output backup pulse if there is a loss of capture. The ECG shown here illustrates such a phenomenon. The first stimulus was ineffective, so the pacemaker delivered a high output backup pulse, which captured the ventricle. The two pacemaker stimuli coming together simulate atrioventricular sequential pacing. Fusion or pseudo-fusion beats can result if the evoked response stimulus resulting from myocardial depolarisation is insufficient.



C G Sajeev
T N S Roy
J Francis
cgsajeev@hotmail.com