

Editor

Roger J Hall

Deputy Editor

David Lefroy

Commissioning Editor

Peter Mills

Associate Editors

Adrian P Banning, Gary F Baxter, Martin Cowie, Filippo Crea, John L Gibbs, Bernard Jung, Andreas Mügge, Iain A Simpson

US Associate Editor

Catherine M Otto
(Washington)

JournalScan Editor

Iqbal S Malik

Statistical Advisor

Ian Ford

Managing Editor

Janet O'Flaherty

Technical Editor

John Weller

Editorial Assistants

Ian Betteridge
Stephanie Watkins

International Advisory Board

Gianni de Angelini (UK)
Faust Attie (Mexico)
Philip E G Aylward (Australia)
George A Beller (USA)
Martin R Bennett (UK)
Nicholas A Boon (UK)
Roger M Boyle (UK)
Paulo G Camici (UK)
Terry Campbell (Australia)
Alfred Cheng (Singapore)
Stuart M Cobbe (UK)
Lawrence S Cohen (USA)
David C Crossman (UK)
Nicolas Danchin (France)
Henry J Dargie (UK)
Mark A de Belder (UK)
Pim J de Feyter (Netherlands)
Carlo di Mario (Italy)
Jean-Noel Fabiani (France)
Roberto Ferrari (Italy)
Peter J Fitzgerald (USA)
Keith A A Fox (UK)
D S Gambhir (India)
Clifford J Garratt (UK)
Marc H Gewillig (Belgium)
Sally Greaves (New Zealand)
Jorgen Fischer Hansen (Denmark)
Axel Haverich (Germany)
Otto M Hess (Switzerland)
Gerd Heusch (Germany)
Pierre Jaïs (France)
Jean Kachaner (France)
Sanjiv Kaul (USA)
Bruce Keogh (UK)
Robert A Kloner (USA)
Cornelius Kluyt (Netherlands)
Michael Komajda (France)
S Krishnaswami (India)
C C Lang (Malaysia)
Herve LeMarec (France)
Janet M McComb (UK)
Bernard Meier (Switzerland)
R Gordon Murray (UK)
Catherine M Otto (USA)
Dudley J Pennell (UK)
Shahbudin H Rahimtoolah (USA)
John Sanderson (Hong Kong)
Maurice E Sarano (USA)
Pinchas Sareli (South Africa)
James Scott (UK)
Ajay M Shah (UK)
Man Fai Shiu (UK)
Jordi Soler-Soler (Spain)
Giuseppe Specchia (Italy)
Martin St John Sutton (USA)
William G Stevenson (USA)
Kenneth M Taylor (UK)
Adam D Timmis (UK)
James D Thomas (USA)
Eric Topol (USA)
Dimitris Tousoulis (Greece)
Pavlos K Toutouzas (Greece)
Alec Vahanian (France)
Cees A Visser (Netherlands)
Ludwig K von Segesser (Switzerland)
Carole A Warnes (USA)
Hugh Watkins (UK)
Gary Webb (Canada)
Sylvan Lee Weinberg (USA)
Harvey D White (New Zealand)
Peter Wilde (UK)
Neil Wilson (UK)
Junichi Yoshikawa (Japan)
Editor: *British Medical Journal*
Editor Emeritus: Michael J Davies

Instructions to authors

Full instructions are available online at www.heartjnl.com/misc/ifora.shtml

If you do not have web access please contact the editorial office: Heart

9 Fitzroy Square
London W1T 5HW, UK
Telephone +44 (0) 20 7383 4006
Fax +44 (0) 20 7388 0323
Email heartjournal@bmjgroup.com

Subscription information

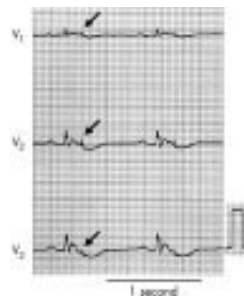
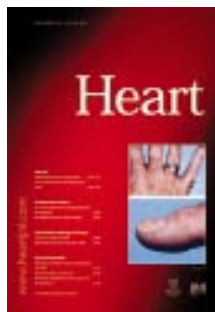See page ii

Copyright

© 2002 Heart. All rights reserved; no part of this publication may be reproduced, stored in a retrieval system, or transmitted in any form or by any means, electronic, mechanical, photocopying, recording, or otherwise without the prior permission of Heart

Authors are required to grant Heart an exclusive licence to publish; further details available online at www.heartjnl.com/misc/ifora.shtml

- Heart is published by BMJ Publishing Group and printed in UK on acid free paper by Stephens and George Magazines Limited, Merthyr Tydfil
- Periodicals postage paid, Rahway, NJ. Postmaster: send address changes to: Heart, c/o Mercury Airfreight International Ltd, 365 Blair Road, Avenel, NJ 07001, USA



See p 444



www.publicationethics.org.uk

This journal is a member of and subscribes to the principles of the Committee on Publication Ethics

Editorials

- 441 Depression, stress, and the heart *P C Strike, A Steptoe*
- 445 Vessel restenosis versus "streamlining" *C E Mullins*
- 447 The unnatural history of tetralogy of Fallot: surgical repair is not as definitive as previously thought *C van Doorn*
- 449 A standard from the classical period *W O Myers*

Viewpoint

- 451 Angioplasty, bypass surgery or medical treatment: how should we decide? *J P Pell, M A Denvir*

Cardiovascular medicine

- 453 Does lung diffusion impairment affect exercise capacity in patients with heart failure? *P G Agostoni, M Bussotti, P Palermo, M Guazzi*
- 460 Utilisation of coronary angiography after acute myocardial infarction in Ontario over time: have referral patterns changed? *Y Khaykin, P C Austin, J V Tu, D A Alter*
- 467 Increased plasma concentrations of interleukin-18 in acute coronary syndromes *Z Mallat, P Henry, R Fressonnet, S Alouani, A Scoazec, P Beaufils, Y Chvatchko, A Tedgui*
- 470 Non-invasive coronary angiography with multislice spiral computed tomography: impact of heart rate *K Nieman, B J Rensing, R J M van Geuns, J Vos, P M T Pattynama, G P Krestin, P W Serruys, P J de Feyter*
- 475 Increasing plasma potassium with amiloride shortens the QT interval and reduces ventricular extrasystoles but does not change endothelial function or heart rate variability in chronic heart failure *C A J Farquharson, A D Struthers*
- 481 Automated quantification of aortic regurgitant volume and regurgitant fraction using the digital colour Doppler velocity profile integration method in patients with aortic regurgitation *Y Miyake, T Hozumi, I Mori, K Sugioka, A Yamamuro, T Akasaka, S Homma, K Yoshida, J Yoshikawa*

Interventional cardiology and surgery

- 485 Surgical closure of atrial septal defects in adults: effect of age at operation on outcome *S Ghosh, S Chatterjee, E Black, R K Firmin*
- 488 Mortality and recurrent cardiac events after coronary artery bypass graft: long term outcomes in a population study *P J Bradshaw, K Jamrozik, M Le, I Gilfillan, P L Thompson*
- 495 Coronary artery perforation during percutaneous intervention: incidence and outcome *M G Gunning, I L Williams, D E Jewitt, A M Shah, R J Wainwright, M R Thomas*

- 499 New insights into onset mechanisms of atrial fibrillation and flutter after coronary artery bypass graft surgery *A D Taylor, J G Groen, S L Thorn, C T Lewis, A J Marshall*

Congenital heart disease

- 505 Various reasons for repeat dilatation of stented pulmonary arteries in paediatric patients *M B E Schneider, P Zartner, K Duvencek, P E Lange*
- 510 Influence of the pulmonary annulus diameter on pulmonary regurgitation and right ventricular pressure load after repair of tetralogy of Fallot *A Uebing, G Fischer, M Bethge, J Scheewe, F Schmiel, J Stieh, J Brossmann, H H Kramer*
- 515 ECG predictors of ventricular arrhythmias and biventricular size and wall mass in tetralogy of Fallot with pulmonary regurgitation *W A Helbing, A A W Roest, R A Niezen, H W Vliegen, M G Hazekamp, J Ottenkamp, A de Roos, E E van der Wall*

Basic research

- 521 Arterial endothelial function is impaired in treated depression *A J M Broadley, A Korszun, C J H Jones, M P Frenneaux*
- 525 Cardiac remodelling in end stage heart failure: upregulation of matrix metalloproteinase (MMP) irrespective of the underlying disease, and evidence for a direct inhibitory effect of ACE inhibitors on MMP *D Reinhardt, H H Sigusch, J Henße, S C Tyagi, R Körfer, H R Figulla*

Education in Heart

- 531 Management of cardiogenic shock complicating acute myocardial infarction *V Menon, J S Hochman*
- 538 Exercise testing in the assessment of chronic congestive heart failure *J G Lainchbury, A M Richards*
- 544 Patients with ventricular arrhythmias: who should be referred to an electrophysiologist? *J M Morgan*

JournalScan

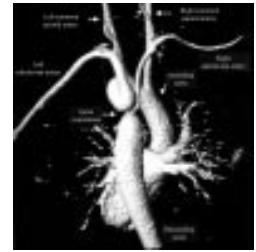
- 551 Cardiovascular highlights from non-cardiology journals

Electronic pages

- e6 Large intracoronary thrombi with good TIMI flow during acute myocardial infarction: four cases of successful aggressive medical management in patients without angiographically detectable coronary atherosclerosis *F Burzotta, M Hamon, R Sabatier, A Boccanelli, G Grollier*

Miscellanea

- 443 Images in cardiology: Ventricular tachycardia as a presenting feature of dermatomyositis *M Adler, S Banerjee, R Stratton*
- 444 Images in cardiology: Unusual echocardiographic appearance of traumatic aortic dissection *A Karabinis, E Rentoukas, G Lazaros, G Dounis*
- 444 Images in cardiology: Epsilon waves in a patient with arrhythmogenic right ventricular cardiomyopathy *R Anan, T Takenaka, C Tei*
- 446 Images in cardiology: Giant left ventricular pseudoaneurysm following left ventricular rupture caused by myocardial infarction *M Kanna, H Kakuchi, H Nonogi*
- 448 Web Top 10
- 459 Images in cardiology: Subaortic stenosis caused by two discrete membranes *M B Yilmaz, E Akarca, Ü Güray*
- 466 Images in cardiology: Use of intravascular ultrasound in evaluating coronary artery aneurysm *S Reith, O Volk, H G Klues*
- 474 Images in cardiology: Large thrombus entrapped in a patent foramen ovale of the atrial septum, which apparently "disappeared" without embolic events *N Watanabe, T Akasaka, K Yoshida*
- 494 Images in cardiology: Torsades de pointes in Prinzmetal's variant angina *A Athanasiadis, U Sechtem*
- 498 Images in cardiology: Coarctation of the aorta with lower blood pressure at the right upper extremity *J A Goudevenos, A Papathanasiou, L K Michalis*
- 520 Images in cardiology: Left anterior descending and circumflex coronary artery spasm after right coronary artery stent implantation *F Versaci, A Gaspardone, I Proietti*
- 524 Images in cardiology: Mycotic aneurysms of the pulmonary arteries *P Lertsapcharoen, P Chottivittayatarakorn, V Benjacholamas*



See p 498