

Editor

Roger J Hall

Commissioning Editor

Iain Simpson

Associate Editors

Adrian P Banning, Eric Butchart, Filippo Crea, David Crossman, John L Gibbs, Bernard Jung, Andreas Mügge

US Associate Editor

Catherine M Otto
(Washington)

JournalScan Editor

Iqbal S Malik

Statistical Advisor

Ian Ford

International Advisory Board

Gianni de Angelini (UK)
Fause Attie (Mexico)
Philip E G Aylward (Australia)
Gary Baxter (UK)
George A Beller (USA)
Martin R Bennett (UK)
Nicholas A Boon (UK)
Roger M Boyle (UK)
Paulo G Camici (UK)
Terry Campbell (Australia)
Alfred Cheng (Singapore)
Stuart M Cobbe (UK)
Lawrence S Cohen (USA)
Martin Cowie (UK)
Nicolas Danchin (France)
Henry J Dargie (UK)
Christopher Davidson (UK)
Mark A de Belder (UK)
Pim J de Feyter (Netherlands)
Carlo di Mario (UK)
Jean-Noel Fabiani (France)
Roberto Ferrari (Italy)
Peter J Fitzgerald (USA)
Keith A A Fox (UK)
D S Gambhir (India)
Clifford J Garratt (UK)
Marc H Gewillig (Belgium)
Sally Greaves (New Zealand)
Jorgen Fischer Hansen
(Denmark)
Axel Haverich (Germany)
Otto M Hess (Switzerland)
Gerd Heusch (Germany)
Pierre Ja'fks (France)
Jean Kachaner (France)
Sanjiv Kaul (USA)
Bruce Keogh (UK)
Robert A Kloner (USA)

Instructions to authors

Full instructions are available online at www.heartjnl.com/misc/ifora.shtml
If you do not have web access please contact the editorial office:
Heart
9 Fitzroy Square
London W1T 5HW, UK
Telephone +44 (0) 20 7383 4006
Fax +44 (0) 20 7388 0323
Email heartjournal@bmjgroup.com

Subscription information

See inside back cover

Copyright

© 2003 BMJ Publishing Group and British Cardiac Society. All rights reserved; no part of this publication may be reproduced, stored in a retrieval system, or transmitted in any form or by any means, electronic, mechanical, photocopying, recording, or otherwise without prior permission
Authors are required to grant *Heart* an exclusive licence to publish; further details available online at www.heartjnl.com/misc/ifora.shtml
• *Heart* is published by BMJ Publishing Group, typeset by The Charlesworth Group, and printed in UK on acid free paper by Stephens and George Magazines Limited, Merthyr Tydfil
• Periodicals postage paid, Rahway, NJ. Postmaster: send address changes to: *Heart*, c/o Mercury Airfreight International Ltd, 365 Blair Road, Avenel, NJ 07001, USA

Deputy Editor

David Lefroy

Series Editor,

Education in Heart
Peter Mills

Managing Editor

Janet O'Flaherty

Technical Editor

John Weller

Editorial Assistants

Andy Fosberry
Stephanie Watkins

Cornelius Kluyt (Netherlands)

Michael Komajda (France)

S Krishnaswami (India)

C C Lang (Malaysia)

Herve LeMarec (France)

Janet M McComb (UK)

Bernard Meier (Switzerland)

R Gordon Murray (UK)

Dudley J Pennell (UK)

Shahbudin H Rahimtoolah
(USA)

John Sanderson (Hong Kong)

Maurice E Sarano (USA)

Pinchas Sareli (South Africa)

James Scott (UK)

Ajay M Shah (UK)

Richard Schilling (UK)

Man Fai Shiu (UK)

Jordi Soler-Soler (Spain)

Giuseppe Specchia (Italy)

Martin St John Sutton (USA)

William G Stevenson (USA)

Kenneth M Taylor (UK)

Adam D Timmis (UK)

James D Thomas (USA)

Eric Topol (USA)

Dimitris Tousoulis (Greece)

Pavlos K Toutouzas (Greece)

Alec Vahanian (France)

Cees A Visser (Netherlands)

Ludwig K von Segesser
(Switzerland)

Carole A Warnes (USA)

Hugh Watkins (UK)

Gary Webb (Canada)

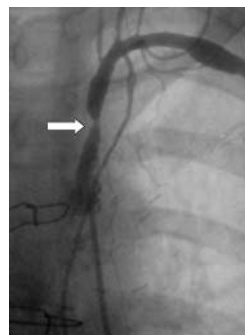
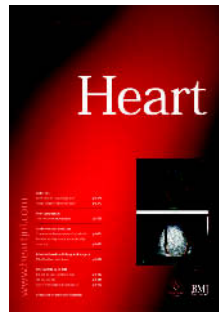Sylvan Lee Weinberg (USA)

Harvey D White (New Zealand)

Neil Wilson (UK)

Junichi Yoshikawa (Japan)

Editor: *British Medical Journal*



See page 1424



www.publicationethics.org.uk

This journal is a member of and subscribes to the principles of the Committee on Publication Ethics

Editorials

- 1375 The debate on public place defibrillators: charged but shockingly ill informed *J P Pell*
- 1377 Clinical applications of tissue Doppler imaging: a promise fulfilled *T H Marwick*
- 1379 Maurice Campbell: first editor of *Heart*
M E Silverman

Review

- 1383 Why cardiologists should be interested in air pollution *H C Routledge, J G Ayres, J N Townend*

Mini-symposium

- 1389 Contrast echocardiography: from left ventricular opacification to myocardial perfusion. Are the promises to be realised?
M J Monaghan
- 1391 Stress myocardial contrast echocardiography
M J Monaghan
- 1394 Contrast echocardiography for left ventricular opacification *J Timperley, A R J Mitchell, H Becher*
- 1398 Role of myocardial contrast echocardiography in the clinical evaluation of acute myocardial infarction *R Senior*

Cardiovascular medicine

- 1401 Interventricular and intra-left ventricular electromechanical delays in right ventricular paced patients with heart failure: implications for upgrading to biventricular stimulation
P Bordachar, S Garrigue, S Lafitte, S Reuter, P Jais, M Haissaguerre, J Clementy
- 1406 Sources of diagnostic inaccuracy of conventional versus new diagnostic criteria for myocardial infarction in an unselected UK population with suspected cardiac chest pain, and investigation of independent prognostic variables *J Trevelyan, E W A Needham, S C H Smith, R K Mattu*
- 1411 Angiogenesis, thrombogenesis, endothelial dysfunction and angiographic severity of coronary artery disease *N A Chung, C Lydakis, F Belgore, F L Li-Saw-Hee, A D Blann, G Y H Lip*
- 1416 Improving the positive predictive value of exercise testing in women *Y K Wong, S Dawkins, R Grimes, F Smith, K D Dawkins, I A Simpson*
- 1422 Prevalence of impaired left ventricular systolic function and heart failure in a middle aged and elderly urban population segment of Copenhagen *I Raymond, F Pedersen, F Steensgaard-Hansen, A Green, M Busch-Sorensen, C Tuxen, J Appel, J Jacobsen, D Atar, P Hildebrandt*

Interventional cardiology and surgery

- 1430 Clinical and haemodynamic profiles of young, middle aged, and elderly patients with mitral stenosis undergoing mitral balloon valvotomy *T R D Shaw, N Sutaria, B Prendergast*

Congenital heart disease

- 1437 Common arterial trunk in the fetus: characteristics, associations, and outcome in a multicentre series of 23 cases *P Volpe, D Paladini, M Marasini, A L Buonadonna, M G Russo, G Caruso, A Marzullo, M Vassallo, P Martinelli, M Gentile*

Scientific letters

- 1442 Importance of β blockade in the treatment of advanced heart failure *R S Gardner, W Martin, R Carter, T A McDonagh*
- 1445 Quality of life assessment using the short form 12 questionnaire is as reliable and sensitive as the short form 36 in distinguishing symptom severity in myocardial infarction survivors *M R Melville, M A Lari, N Brown, T Young, D Gray*

Education in Heart

- 1447 The role of echocardiography in atrial fibrillation and cardioversion *R W Troughton, C R Asher, A L Klein*
- 1455 Athlete's heart *R Fagard*
- 1462 Optimal management of acute ventricular septal rupture *A Murday*

JournalScan

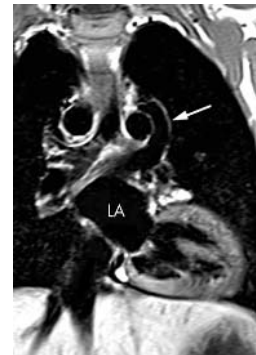- 1467

Electronic page

- e27 Single coronary artery: a familial clustering *P G Horan, G Murtagh, P P McKeown*

Miscellanea

- 1376 Electronic pages
- 1381 Images in cardiology: Multiple coronary artery fistulas visualised by three dimensional computed tomography *O Seguchi, M Terashima, K Awano*
- 1382 Images in cardiology: Ruptured thoracic aortic aneurysm resulting in cutaneous haematoma *D Perera, Z Dent, M Signy*
- 1382 Images in cardiology: Imitating ventricular tachycardia *A Bauer, G Schmidt*
- 1388 Images in cardiology: Pulmonary artery sarcoma *N Kotooka, N Nagaya, R Tanaka*
- 1405 Images in cardiology: A case of rheumatic fever *S De Freitas, S Frankton, J M Tremble*
- 1410 From BMJ journals: Defining clinical features of amiodarone induced optic neuropathy
- 1415 Images in cardiology: A case of bepridil induced interstitial pneumonitis *S Gaku, K Naoshi, A Teruhiko*
- 1421 Images in cardiology: Complications of pacemaker leads *H Burri, H Sunithorn, D Shah*
- 1429 Images in cardiology: Subclavian artery stenosis as a cause for recurrent angina after LIMA graft stenting *R S Bilku, S S Khogali, M Been*
- 1436 Images in cardiology: Anomalous origin of the pulmonary artery from the left coronary artery *S S Kothari, N K Goyal*
- 1444 Images in cardiology: Levotricuspid vein without cardiac malformation and normal pulmonary venous return *T Jaecklin, M Beghetti, D Didier*
- 1444 Images in cardiology: Pacing the left ventricle through the coronary sinus in a patient with a prosthetic tricuspid valve replacement *S W Lord, S C Clark*
- 1446 Web Top 10



See page 1444