

PERCUTANEOUS CORONARY INTERVENTION FOR BIFURCATION CORONARY DISEASE

Coronary disease

713

Yves Louvard, Thierry Lefèvre, Marie-Claude Morice

Heart 2004;90:713–722. doi: 10.1136/hrt.2002.007682

Ever since coronary angioplasty was first undertaken, treatment of coronary bifurcation lesions has posed technical problems.^{w1 w2} Specific difficulties involving access to the side branch and the snow plough effect, as well as the role of kissing balloon inflation, have been rapidly identified even before the era of near universal stenting. Consequently, until the late 1980s, patients with bifurcation lesions were generally referred for surgery and seldom treated by percutaneous techniques. However, in cases where angioplasty was considered an option, the kissing dilatation technique was widely used in order to avoid recurrent problems of plaque shifting observed when the two branches were dilated separately.^{w3}

The new tools developed in the early 1990s seemed likely at first to facilitate the approach to bifurcation lesions. However, the results achieved with the debulking technique alone (rotative or directional atherectomy) were rather disappointing. Conversely, coronary stenting through its scaffolding properties became the treatment of choice, at least for reducing the risk of acute complications. In the mid 1990s, the question remained as to how to perform optimal stenting of the main branch while preserving the side branch. The data collected from bench test studies proved crucial. They allowed the operators to understand stent behaviour and the effect of empirically implemented strategies, and to develop new concepts such as dedicated stents.

IN VITRO BIFURCATION STENTING

Numerous techniques of stent deployment in bifurcation lesions have been described.^{1–5 w4–w21}

These techniques have been indexed⁶ in our institution and evaluated in vitro in a bench test mimicking coronary bifurcations with diameters of 3.5 mm for the main branch and 3.00 mm for the side branch. The pitfalls of such a model are the absence of stenosis, the constant longitudinal diameter of the main branch, and the impossibility to study other branch diameters.

Nevertheless, the problem of access to the side branch, stent deformation during the various steps of a stenting procedure, and scaffolding achieved at the bifurcation level can be successfully studied. The four treatment options in our classification have been defined as follows:

- ▶ *Type A treatment*—placement of a stent at the side branch ostium followed by placement of another stent in the main branch covering the ostium of the side branch
- ▶ *Type B treatment*—stenting of the main branch followed by stenting of the side branch at the ostium level through the struts of the main branch stent.
- ▶ *Type C treatment*—this technique is known as the “culotte” or “trousers” technique or in some instances as the Y technique. It consists of implanting a first stent from the proximal to the distal segment of the main branch jailing the side branch ostium. A second stent is then placed from the proximal main branch towards the side branch while jailing the ostium of the distal main branch. This results in a double layer of stents in the proximal part of the main branch.
- ▶ *Type D treatment*—this strategy consists of placing two stents at the level of the ostia, followed by implantation of another stent in the proximal segment if necessary. This technique is also known as the Y implantation technique.

In theory, type A treatment allows good scaffolding of the bifurcation at a right angle. However, accurate stent placement may prove difficult. If not positioned at a right angle, implantation of a stent at the ostium level may leave an unstented segment in the form of a crescent at the side branch level (fig 1).⁶ In order to avoid this problem, some operators have suggested that the side branch stent should be partly positioned inside the main branch. The drawback of this approach is a pronounced protrusion, which may complicate the insertion of a second guide wire in the main branch or placement of a balloon catheter or a second stent (fig 1). The modified T stenting technique proposed by Colombo (fig 1)⁴ provides a solution to this problem, though requires the use of larger size guiding catheters (8 or 9 French). Two guide wires are inserted at the beginning of the procedure; the ostial stent is deployed in the side branch with a second stent being positioned in the main branch and subsequently deployed after removal of the wire and balloon catheter from the side branch. In order to ensure adequate scaffolding of the side branch ostium, the proximal part of the stent is deployed in the main branch in the presence of the second stent,



Additional references appear on the *Heart* website—<http://www.heartjnl.com/supplemental>

See end of article for authors' affiliations

Correspondence to:
Dr Yves Louvard, Institut
Cardiovasculaire Paris Sud,
Institut Hospitalier Jacques
Cartier, 6 avenue du Noyer
Lambert, 91300 Massy,
France; y.louvard@icps.com.fr

and then “crushed” during deployment of the main branch stent. In such a case, the main branch proximal to the bifurcation lesion is scaffolded with a triple layer of stent. This technique, known as the “crush technique” (fig 1),^{w12} was originally a failed modified T stenting strategy (P Serruys, oral communication, 18th annual Interventional Cardiology meeting, 3 March 2003). In all the instances described above, the secondary placement of a stent in the main branch results in the side branch ostium being jailed with stent struts, which may cause flow impairment, turbulence, and hinder subsequent access to the branch.

Type B treatment^{w5 w6} has apparently several drawbacks. One is the placement of the second stent in the side branch through the struts of the main branch stent, which can prove impossible in extremely angulated bifurcation lesions. Another theoretical drawback is the impossibility to achieve adequate scaffolding of the side branch ostium when the angle is $> 90^\circ$. However, opening one of the main stent struts towards the side branch^{w22} has two interrelated consequences: inflation attracts the opposite struts towards the centre of the lumen^{e 7 w23} and in the majority of cases one or two struts of the main branch stent are applied against the wall of the side branch ostium (the “crescent” effect) (fig 2).^{6 w5 w24} Deformation of the main stent is dictated by the degree of stent expansivity^{w23} and by the size of the side branch and balloon catheter used⁷; it is also accentuated when the strut opened toward the side branch is distal and closer to the carina, which generally ensures optimal

scaffolding of the side branch ostium (fig 2). This permits placement of a non-bevelled stent in the side branch with excellent coverage. Optimal scaffolding of the side branch is achieved with tubular stents.^{w24}

Kissing balloon inflation at the bifurcation site may correct deformation (fig 1)^{6 7 w23 w25} of the main branch stent and efficiently apply the stent struts against the wall of the side branch ostium, depending upon the size of the two branches, stent expansivity, and location of the dilated strut.

Type C treatment involves placement of a second stent through one of the struts of the first stent. The drawbacks are the high concentration of metal (two layers) in the proximal part of the bifurcation and the presence of struts in the lumen at the bifurcation site even after kissing balloon inflation (fig 1). In order to address the metallic concentration issue, some stents have been designed with larger proximal struts.

Type D treatment (touching stents)^{w7 w8} seems to be well adapted to the treatment of exclusively bi-ostial lesions. This strategy carries the advantage of being fast and simple. There are a number of variants (fig 1).^{w10} However, in cases when stenosis extends proximal to the ostium, this treatment type involves the placement of a third proximal stent (Y stenting),^{w7 w9} which does not permit optimal scaffolding of the main branch proximal to the bifurcation. This can be corrected by implanting the two stents side by side proximal to the ostia, thus creating a new carina, or by mounting the proximal stent onto two balloons which are individually inserted in each branch (“trouser legs and seat” technique

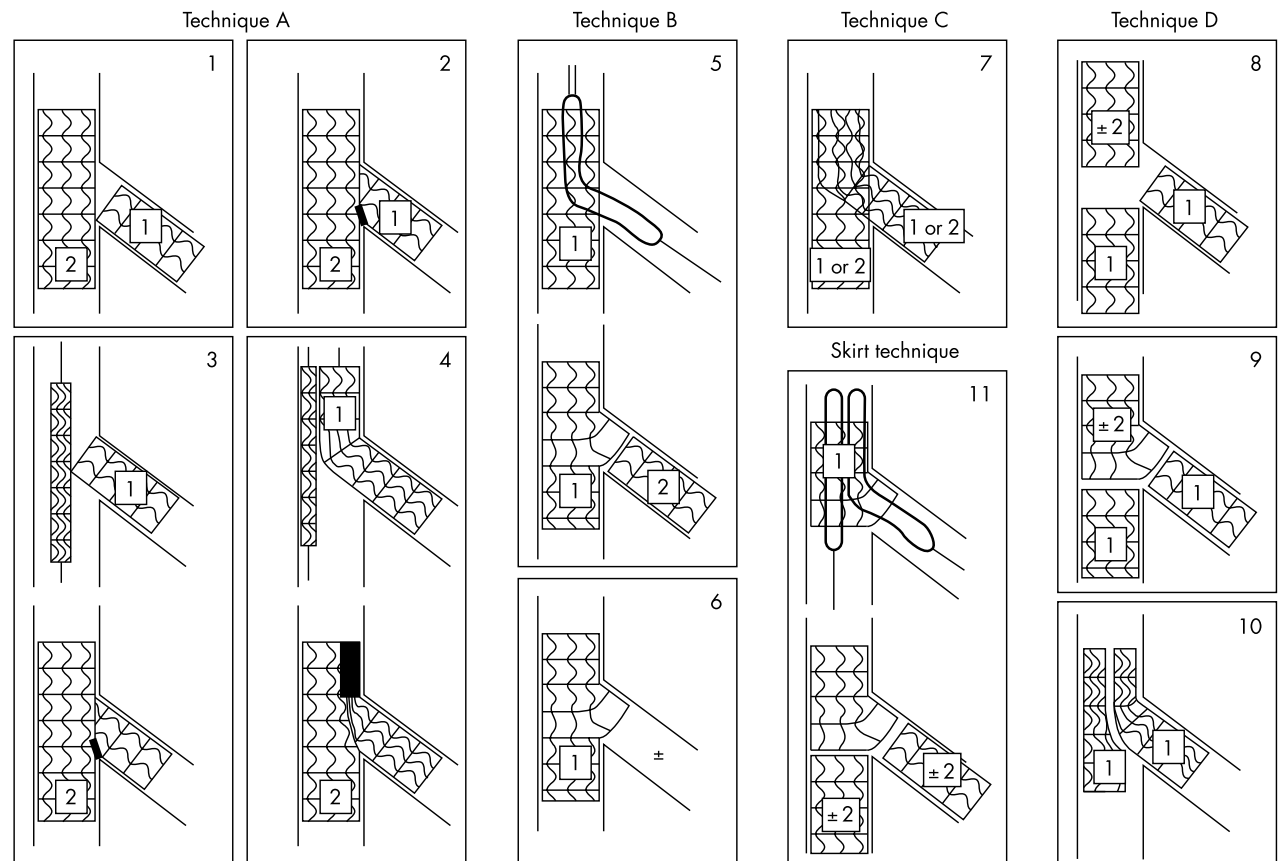


Figure 1 Classification of treatment. (1) and (2): Classic T stenting beginning with side branch stenting. (3): “Modified T stenting”. (4): “Crush” technique. (5): Classic T stenting beginning with main branch stenting. (6): Provisional T stenting. (7): “Culotte” or “trousers” technique. (8): “Touching stents” completed or not as Y technique. (9): “Trousers legs and seat” technique, a classic “touching stents” technique completed proximally by a “skirt” technique. (10): “Kissing stents” technique. (11): “Skirt” technique.

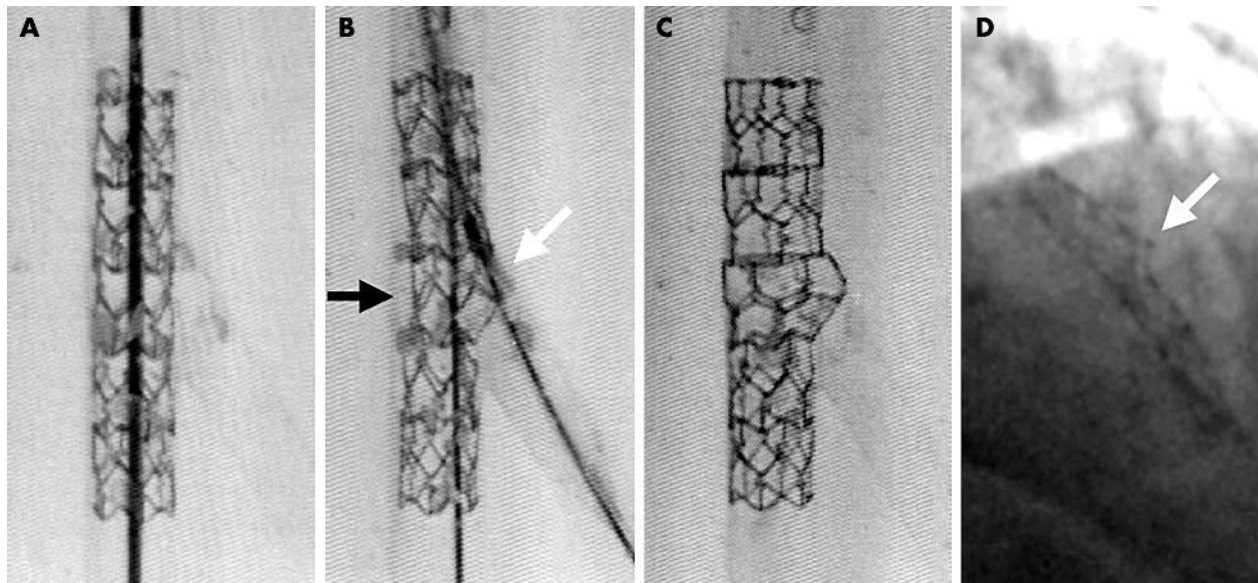


Figure 2 Main branch stent deformation during type B treatment. (A) Biocompatible stent deployed in main branch. (B) After balloon inflation toward the side branch: the ostium of the side branch is stented, the opposite struts of the stent are attracted towards the middle of the main branch lumen. (C) Correction of deformation by kissing balloon inflation. (D) The same figure is observed in a left anterior descending (LAD)-diagonal bifurcation.

described by Colombo or trouser-like stenting technique described by Khoja).³ This can even lead to “gun barrel” stenting (V stenting or kissing stents).^{8 w4} Such a technique results in the placement of a metallic partition in the middle of the proximal main branch lumen which may cause thrombosis and hinder distal access with a wire or a balloon.

Various stents have been assessed in the treatment of bifurcation lesions. In vitro testing permitted the evaluation of arterial wall coverage, wire access to the branches, deformation caused by access to the side branch through the main branch stent,^{6 7 w23–25} and stent ability to expand towards the side branch during kissing balloon inflation. It is very important to know the maximal stent and strut opening size which can be easily obtained from the manufacturers (table 1). Angulation must be taken into account in order to assess the opening area required (fig 3). Coil stents, which are no longer available, did not provide adequate wall coverage at the bifurcation site but permitted excellent access to the side branch. Hybrid stents also provide good access to the branches, but some of them may become totally dislocated upon strut opening towards the branch. The main advantage of tubular stents is that they provide excellent wall scaffolding in segments where plaque volume is greatest. They can also allow good access to the side branch, be widely expanded, and are designed with a large strut opening capacity (table 1).^{w23}

Several stent types have been designed for bifurcation lesion treatment:

- ▶ Stents with one (NIR side, AST SLK), or several larger struts (Jomed). The main drawback is the scarcity of struts where they are most needed, which does not permit stenting of the side branch ostium. Accurate positioning of a stent at the side branch ostium level may be difficult. No studies have yet been published with these devices.
- ▶ Bifurcated stents. The Bard XT Carina, the AVE Bifurcation and Cordis DBS have already been evaluated.^{9 w26} The size of the Bard XT stent struts varies from the proximal segment to the distal branches, and

metallic scaffolding of the bifurcation is very inadequate. The scaffolding properties of the AVE bifurcation stent have been improved but the stent has never been used in human patients. The DBS stent has the best scaffolding properties and was clinically evaluated in a pilot study (unpublished). Though the results looked promising, we are still waiting for a second, more flexible generation.

- ▶ A new concept of dedicated stents (stenting the main branch and the side branch ostium with one non-bifurcated stent) is emerging. It combines the design of a specific stent, which provides optimal scaffolding of the main branch and the side branch ostium, with a delivery system allowing permanent access to both branches and accurate placement of the stent at the carina level. Four devices have undergone in vitro testing: the Frontier, the AST-slit-view, and Invatec’s IBD-SDS and IBS-SDS, and have been shown to permit predictable stenting of the side branch ostium.

THE “PLAQUE SHIFTING” PHENOMENON

The main difference between in vitro models and a real patient is of course the presence of atheromatous plaque that can be calcified or not, concentric or eccentric, thick or thin, with a varying degree of arterial wall remodelling and plaque volume. Atheromatous plaque causing > 50% narrowing of both branches at the bifurcation level could be the definition of “true” coronary bifurcation lesions.

It has been clearly shown that, subsequent to balloon inflation, atheromatous plaque may shift proximally and distally^{w27} and even along the arterial circumference (axial plaque redistribution is not only longitudinal but also circumferential). This phenomenon is accentuated by stent placement.¹⁰ Thus, dilatation or stenting of a lesion located proximal or distal to a bifurcation often results in plaque shifting towards the side branch, which requires dilatation or even stenting of the ostium and, sometimes, even placement of a third stent in the proximal or distal segment of the main branch in order to address plaque shifting from the side

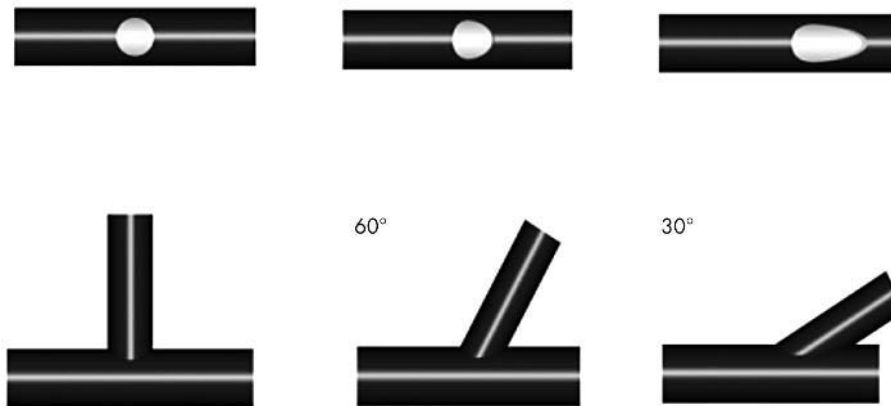


Figure 3 Relation between ostium circumference and angulation of the bifurcation.

branch. The same phenomenon occurs during dilatation or stenting of a main branch lesion located opposite a side branch; side branch occlusion is reported in 4.5–26% of cases^{w28–36} and predictors are: side branch originating in the main branch lesion,^{w32 w34 w35} presence of an ostial lesion in the side branch,^{w28 w31–36} small side branch reference diameter,^{w34} stent/artery ratio in the main branch,^{11w34} and unstable coronary syndromes. The type of stent used does not seem to impact the risk of side branch occlusion.^{w33} Side branch occlusion is usually considered to be of little consequence (temporary chest pain, moderate creatine phosphokinase (CPK) elevation) and patency of most of these occluded branches is spontaneously restored.^{w28 w31 w33 w34} However, in the recent NIRVANA study¹¹ the use of NIR stents was associated with a 4.7% risk of side branch occlusion and 27% risk of significant stenosis. The rate of Q wave myocardial infarction (MI) was 7% when side branch occlusion occurred (CPK elevation was > 8 times the normal value in 20%, > 5 times in 33%). Overall, the rate of Q wave or non-Q wave MI (creatin kinase (CK)-MB \geq 5 times the normal value) was 40% in the side branch occlusion group.

Consequently, because of the risk of side branch occlusion, tight lesions located in the main branch next to a bifurcation must be considered bifurcation lesions. These lesions have been indexed.^{6 w37 w38} In addition to type 1 (“true” bifurcation lesions), the Institut Cardiovasculaire Paris Sud (ICPS) classification (fig 4)⁶ includes type 2 lesions where the main branch lesion is located opposite a lesion-free side branch, type 3 with stenosis located proximal to the bifurcation, and type 4 with stenosis distal to the bifurcation in both branches, in the main branch only (type 4a), or in the side branch only (type 4b or side branch ostial stenosis).

Atheromatous plaque also shifts during the stenting procedure. For example, primary stent placement at the side

branch ostium (type A or modified T treatment) causes the plaque to shift towards the wall of the main branch. Subsequent stent implantation in the main branch covering the side branch origin may also result in plaque shifting towards the side branch ostium, covering the proximal part of the ostial stent, or even pushing the plaque in the ostium through the first strut of the stent (fig 5). Stent deformation generated by the opening of the stent struts towards the side branch may be corrected by kissing balloon inflation, but not the presence of plaque inside the stent. These difficulties can be avoided by using the provisional T stenting strategy.

THE OUTCOME OF IN VIVO BIFURCATION STENTING

The percentage of primary success associated with coronary bifurcation stenting varies from 87–100% according to the literature, with an in-hospital major adverse cardiac event (MACE) rate ranging from 0–13%.^{12–14 w39–48}

These results are significantly inferior to those reported in patients who do not present with bifurcation lesions,^{w49} and bifurcation lesions remain a predictor of failure as are thrombotic and calcified lesions.^{w50} Studies reported in the literature are often retrospective and involve various lesion types (“true” or “false” bifurcations), and various techniques are often inadequately described and require different stents. It is, consequently, difficult to give satisfactory answers to several important questions.

Should both branches of the bifurcation be stented or the main branch only?

In the era of bare stents, there has been no randomised comparison between the outcome of stenting both branches versus the main branch only. Several registries have compared the results of stenting the main branch combined with angioplasty of the side branch through the struts versus stenting of both branches.^{8 12 13 w41 w43 w46 w51} Most of the time, these comparative registries were not assessed by intention-to-treat analysis. This means that most patients received a stent in the side branch because of suboptimal results or complications, and that some patients did not receive a stent in the side branch because of technical procedural failure. Among the recipients of two stents, in some the side branch was stented first (systematic double stenting; type A treatment) and in others as a secondary strategy because of suboptimal results or complications in the side branch.¹³ The type of bifurcation lesion is not always mentioned. The techniques used for double stenting vary

Table 1 Stent and stent cell maximal diameters

3.5 mm stents	Stent diameter (mm)	Maximum strut diameter (mm)
BioDyvisio (Abott)	4.4	2.9
Bx Velocity (Cordis)	4.75	3.0
Carbostent (Sorin)	3.8	3.0
Express (Boston)	4.25	3.7
Flexstent (Jomed)	5.0	2.9–3.6
Penta (Guidant)	4.5	4.0
R stent (Orbus)	4.5	4.5

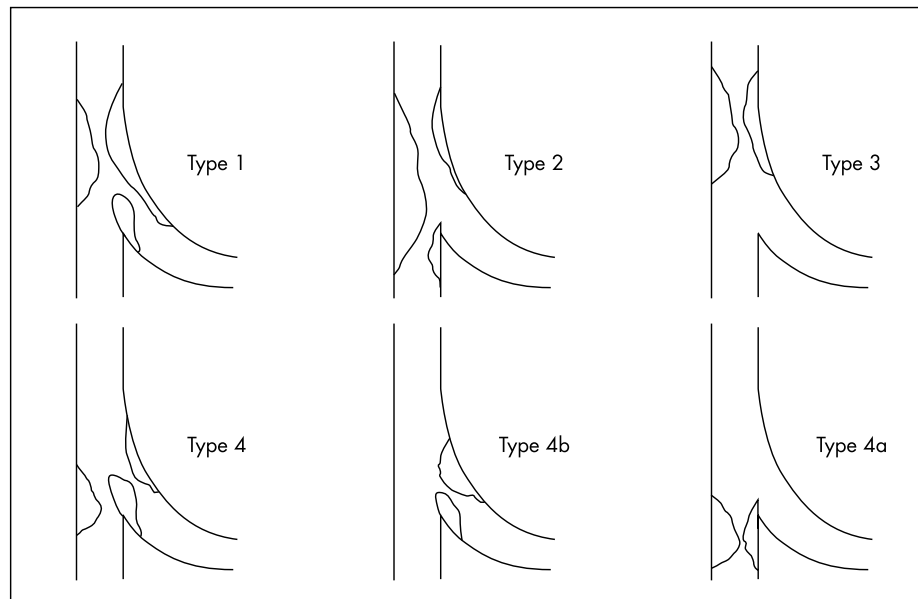


Figure 4 Institut Cardiovasculaire Paris Sud (ICPS) classification of bifurcation lesions.

according to the series and sometimes even within the same series.^{8 13 w41 w51} Their description is brief and one technique may have several names (type A treatment described by Al Suwaidi becomes the culotte technique for Yamashita). In certain series, stenting was performed after debulking by directional or rotative atherectomy.^{8 13} The common conclusion of all these series was the absence of superiority of systematic double stenting; the angiographic outcome was often better in the double stenting group, in the side branch especially,^{8 w41 w43} and angiographic success rates were identical most of the time; the rate of in-hospital MACE was sometimes even higher in the double stenting group^{8 w43} (13% v 0% in the study by Yamashita with a higher debulking rate in the double stenting group). The restenosis rate, in the side branch especially, tended to be higher in the double stenting group as well as the event rate and mid term target lesion revascularisation (TLR) (6–18 months). In the study by Anzuini, the restenosis rate was 37.5% in the side branch with T stenting versus 12.5% ($p < 0.05$); in the study by Pan, the 18 month event rate was 56% versus 25% ($p < 0.05$); and Bacquet reported a 47.6% TLR versus 24% ($p < 0.05$).

Has the technique used had any influence on the outcome?

Many bifurcation stenting techniques have been described in case reports or in short series often without follow up and have not been evaluated through prospective registries. Certain techniques have been more carefully assessed.

The culotte or trousers technique that we call type C treatment (Y stenting for Al Suwaidi) is no longer used in our institution because of a poor result in the bench test and a high percentage of in-hospital MACE (37.5% of in-hospital MACE and 44.4% at seven months).^{w52} Similar results are published in the literature: 5% rate of stent thrombosis at one month with the Bard XT stent,^{w40} 14% MI rate despite use of glycoprotein IIb/IIIa inhibitors in 51% of cases, and kissing balloon inflation in 79% of cases in the “Culotte stenting” study¹⁵ with the Duet stent. Finally, the study by Al Suwaidi and colleagues¹³ on single versus double stenting showed that the use of the culotte technique resulted in a 5.3% rate of Q wave MI and emergency surgery. Such an excess of acute complications seems related to the excess of metal at the bifurcation site and in the vessel lumen, despite the highly

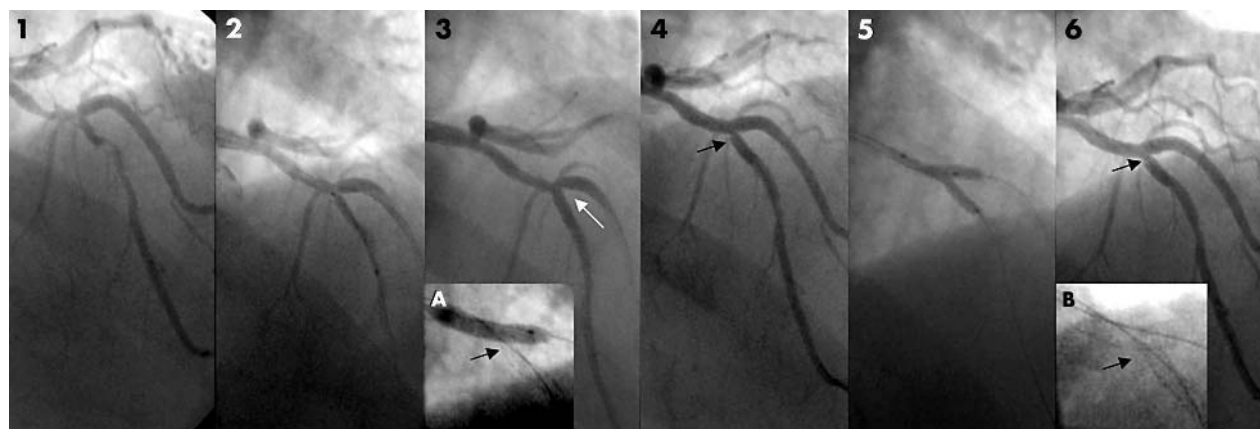


Figure 5 (1) Left anterior descending (LAD)/diagonal type 2 bifurcation lesion. (2) The distal LAD is stented first at the ostium. (3) The stent is slightly protruding in the diagonal ostium. (A) Balloon inflation in the diagonal. (4) After LAD to diagonal stenting, plaque shifting has occurred inside the LAD stent. (5) Kissing balloon inflation. (6) Final result with a residual stenosis in mid LAD ostium. (B) No gap in the T stenting.

recommended use of kissing balloon inflation. This was confirmed by the endocoronary echography study by Robinson and colleagues^{w53} showing that a cross sectional area (CSA) equal to 97% of the reference can be obtained in the stent but out of the bifurcation. Conversely, the CSA was 70% and 78% of the reference at the bifurcation site in the main branch and the side branch, respectively. Moreover, this residual stenosis is not angiographically visible (fig 6). The procedural difficulties and poor in-hospital outcome have been well illustrated by Morocutti^{w54} who reported a case where rotational strut ablation of two multilink stents was required, and by De Sheerder^{w55} who underlined the procedural duration and amount of contrast media used. These findings may explain the poor mid term results reported in almost all series: 45% target vessel revascularisation (TVR) in the “culotte” study,¹⁵ 86.3% one year composite event rate versus 30.4% in patients treated by T stenting in the study by Al Suwaidi and colleagues. In patients not treated with the culotte technique in this study,¹⁵ the comparison of single versus double stenting showed a comparable one year event rate of 26.8% versus 30.4% (NS). It is probable that the use of culotte stenting may have negatively impacted the comparison between single and double stenting in several other studies.^{8 w41 w43 w51}

Several studies have also shown lower success rates associated with T stenting compared with main branch stenting followed by balloon angioplasty of the side branch. Pan and Anzuini^{12 w46} showed similar in-hospital results with both techniques. However, the 12–18 months' event rate was significantly higher in the double stenting group: 56% versus 25% at 18 months ($p < 0.05$) as reported by Pan and colleagues, and 39% versus 20% using type A treatment in the series reported by Anzuini. The same author also reported a 15.5% TLR in the single stenting group versus 35.5% in the double stenting group (NS); the main branch restenosis rate was comparable in the two groups (25% v 12.5%) and the side branch restenosis rate was higher in the double stenting group (37.5% v 12.5%). In the study conducted by Sheiban on 54 bifurcation lesions, the overall restenosis rate was 60.5%; 42.2% and 47.3% in the main and side branch, respectively.

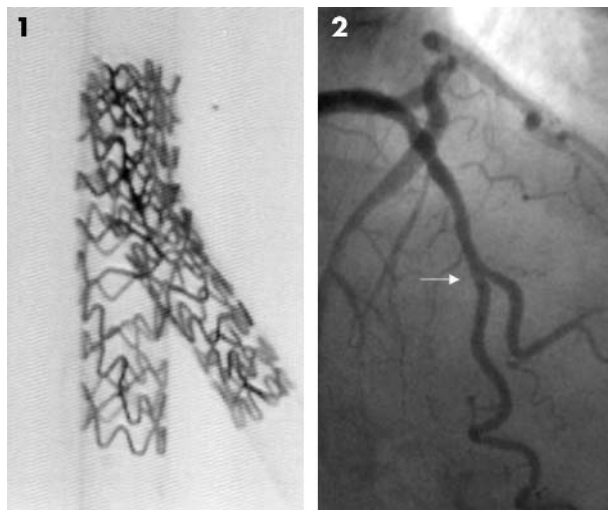


Figure 6 (1) “Culotte” technique in the bench (Crossflex stent). (2) Final result of a “culotte” technique in a LAD/diagonal bifurcation (Crossflex stent): the excess of metal is not visible.

Predictive factors of restenosis were a high score injury, high metal density in small arteries,^{w46} and gaps between stents. In order to address the gap issue, technique A was modified into “modified T stenting”¹⁴ (fig 1) which was evaluated in two series involving 41 and 38 bifurcation cases, respectively.^{w56 w57} Procedural success rate was excellent, no in-hospital MACE was reported; gaps were observed in 13.2% of cases in the series reported by Sheiban, and Meztger reported the occurrence of symptomatic restenosis in 17% of patients.

As the comparison between implantation of one versus two stents seemed to be in favour of the single stent strategy, even with T stenting techniques, the provisional T stenting strategy was proposed⁵ and evaluated, consisting of stent placement in the main branch first, followed by implantation of another stent in the side branch ostium through the struts of the main branch stent in cases of residual stenosis and/or dissection. The “jailed wire technique” has led us to develop this strategy. In single^{w52 w58} as well as multicentre studies,^{14 w36 w45} using only one stent^{14 w36 w45} or multiple stents, the reported angiographic success rate in both branches was in the range of 92–98%, in-hospital MACE was 2–5.4%, and MACE at follow up was 16.9–19.9% with a 9.3–15% TVR rate and side branch stenting performed in 25–34% of cases. When applied to “false bifurcation lesions” this strategy resulted in a 95–100% angiographic success rate according to the lesion type, with in-hospital MACE ranging from 1.5–4.4%, 5.4–16.7% TVR rate, with side branch stenting being reported in 14.9–19.5% of cases only.^{w59} Because ostial lesions in side branches are often short, the same strategy can be implemented in the presence of “true” bifurcation lesions with a similar angiographic success rate and a 32.6% rate of stenting in the side branch.^{w52} Pan has described a very interesting strategy comprising three steps: the first step consists of dilating the side branch first and then stenting the main branch; then the side branch is dilated through the main branch stent if necessary, and the third step is to stent the side branch if required. The reported success rate of each individual step was 28%, 88.1%, and 92%, respectively.¹⁶ The provisional T stenting strategy is associated with excellent in-hospital results, reduced procedure duration^{w52} and cost, and better mid-term results compared with systematic side branch stenting. The better outcome of the provisional T stenting strategy may be due to the fact that main branch stenting is performed first. Indeed, we retrospectively compared the results of type B treatment with and without side branch stenting and observed the same MACE rate at seven months follow up in both the single and double stenting groups (17.4% v 15.1% with 8.5% v 13.5% TVR, respectively) (unpublished data). Consequently, stent placement in the side branch should still be considered an option in the presence of suboptimal results after kissing balloon inflation.

In vitro studies have demonstrated that final kissing balloon inflation corrects the main branch stent deformation induced by balloon inflation in the side branch through the struts.^{6 7 w23 w25} Analysis of our early results confirmed the benefit of this strategy in vivo. Indeed, we observed that increased use of kissing balloon inflation and tubular stents was associated with a lower in-hospital MACE rate, and especially stent thrombosis rate, as well as lower TVR rates.^{w39} These two factors have been reported as predictors of TVR in a large “true” bifurcation series.^{w60} Homogeneous registries assessing the same stents and techniques with a

very broad use of kissing balloon inflation have shown very low rates of MACE and TVR at short and long term follow up.^{14 w45} Systematic intravascular ultrasound evaluation performed in two groups of 10 patients who received a stent in the main branch with simultaneous or consecutive dilatation of the side branch^{w61} has shown a larger main branch lumen proximal to the bifurcation in the kissing inflation group, whereas the lumen area within the stent was reduced in the consecutive group. There has been only one randomised study so far comparing the “kissing” inflation technique with consecutive inflation of two balloons.¹⁷ The side branch was shown to be more frequently compromised in the consecutive inflation group ($p = 0.02$) and there was a non-significant trend towards a higher angiographic success rate in the side branch as well as a lower rate of non-Q wave MI in the kissing inflation group (0% v 15%). Though the small size of this study does not permit any definite conclusion, its results seem in favour of the kissing technique.

Debulking and stenting

The benefit of debulking before stenting has been assessed in three studies. One of these studies evaluated the results of rotational or directional atherectomy performed in both branches followed by stent implantation in the main branch. The other two studies assessed the outcome of stenting alone versus stenting after directional atherectomy. The study conducted by Ghambir involved 67 bifurcation lesions; the main branch was treated by balloon angioplasty in 74.6% of cases, by rotational atherectomy in 22.4%, and directional atherectomy in 3%, and then stented. The side branch was treated by atherectomy in 30 patients and balloon dilatation in 37. Procedural success rate was 95.6% and the occurrence of non-Q wave MI was 1.5%. At nine month follow up, TLR was lower in the “debulking” group (10% v 29.7%, $p = 0.045$).^{w62} Karvouni and colleagues compared two matched groups of 31 patients and 62 lesions. In one group, directional atherectomy was performed followed by stent implantation in at least one branch, and in the other group primary stenting was performed in at least one of the two branches. Primary success rate was higher in the stent group (100% v 87.1%, $p = 0.03$) due to the occurrence of MACE (non-Q wave MI) in the atherectomy group (12.9% v 0%; $p = 0.03$). Conversely, the minimal lumen diameter (MLD) was larger and the acute gain higher with lower percentage residual stenosis in the main branch. MACE and restenosis rate at follow up evaluation were shown to be lower in the atherectomy group (NS).¹⁸ The study conducted by Chieffo compared the results achieved in 58 bifurcation lesions treated by directional atherectomy and stenting with those obtained in 332 lesions treated with stent alone. There was no difference in the occurrence of in-hospital MACE between the two groups and the MLD was larger in the in-hospital phase and at follow up in the atherectomy group. The restenosis rate in the side branch was significantly lower in the atherectomy group (16% v 41%, $p = 0.02$).^{w63} The absence of significant randomised comparisons precludes any conclusion regarding the benefit of atherectomy performed before stenting in the treatment of coronary bifurcation lesions.

Specific settings

Bifurcation of the left main coronary artery

Left main angioplasty has become an established alternative to bypass surgery.^{w64-67} However, several studies have shown that the presence of stenosis in a left main bifurcation is a

predictor of death, MACE, and TLR at one and three years follow up^{w67} as well as restenosis.^{w66} Debulking by directional atherectomy before stenting seems to reduce the restenosis rate.^{w64} Atherectomy was a predictor of no restenosis by multivariate analysis in the recent study by Park and colleagues.^{w68}

Bifurcation lesions and myocardial infarction

Bifurcation lesions are frequently observed in the acute phase of MI. However, as their presence is generally hidden, they are often underestimated. As a result, when the main branch is stented, access to the side branch is often difficult or impossible. Consequently, anticipation is crucial and all significant side branches who might originate in the occluded territory should be identified at the beginning of the procedure.

In our experience,^{w69} the angiographic success rate as well as the six month complication and TVR rates are comparable with those reported in non-acute settings.

HOW TO PERFORM SUCCESSFUL BIFURCATION STENTING

Angiography of bifurcation lesions

Angiographic quality is crucial for optimal diagnosis and treatment of bifurcation lesions.

Adequate visualisation of the side branch ostium permits accurate diagnosis and indexing of the lesion as well as easy wire access or stent positioning. Right anterior oblique (RAO) + caudal, spider, and TIMI (thrombolysis in myocardial infarction) views are very useful for visualising left main bifurcations. TIMI and LAO + cranial views are generally used for LAD/diagonal bifurcations and the spider view for proximal bifurcations. RAO + caudal and spider views permit accurate visualisation of lesions located in the circumflex artery, and RAO, LAO + cranial views can be used for distal lesions of a dominant circumflex artery. For the distal right coronary artery, anteroposterior (AP) + cranial view is very useful.

The difficulty of performing quantitative coronary angiography (QCA) is one of the problems associated with angiography of bifurcation lesions. Indeed, though automatic drawing of the artery edges and MLD measurement are not an issue, the interpolated reference given as the real reference diameter of the main branch is questionable; this is because in type 1, 2 or 3 lesions, measurement of the artery reference diameter is influenced by the diameter of the distal main segment only. In type 4 lesions, the size of the proximal segment causes overestimation of both the interpolated reference and percent stenosis.

In the side branch the reference diameter is frequently underestimated because there is no proximal reference (ostial lesion). This problem can be resolved by drawing the proximal segment of the main branch and the side branch, and then considering only the side branch for measurement (flagging). But this human intervention may lead to highly variable results, especially when the difference between the two distal vessel sizes is large. Automatic drawing as well as analysis of the reference diameter of both branches according to Murray's law may provide interesting information.^{w70}

The double wire technique

Implementation of this technique from the beginning of the procedure has several advantages and carries practically no risk.

Access to one branch while the other is being dilated must be preserved whatever the technique used. When two guide wires are used, care must be taken to avoid wire crossing which would prevent balloon insertion. A number of rules can be applied: the first wire must be inserted into the less accessible branch, the second wire must be inserted with minimal torquing (less than a wrist rotation), and last but not least, the wires must be kept in the same position on the table outside the guiding catheter during the whole procedure, even after wire exchange. Usually wires are best managed by an assistant.

Insertion of a wire into the side branch often changes the angle between the proximal main branch and the side branch and thus facilitates access, especially in a T shaped bifurcation which is a predictor of procedural failure.^{w71} The change in angle is more pronounced when the initial angle is very acute. In a study population of 76 patients, angles $< 120^\circ$ before guide wire insertion were improved by 40° and angles $> 120^\circ$ at baseline were improved by only 12° (Y Louvard, unpublished data). The angle between the two distal branches is modified to the same extent, which can prevent optimal coverage of the bifurcation when double stenting is required. Improved access to the side branch is associated with a higher success rate using technique B.

Indeed, the side branch wire is jailed between the stent and the wall of the proximal main branch. In addition to the change in angle, this technique preserves side branch patency^{w72 w73} by opening the side branch ostium as a slit (fig 7). Finally, if the side branch is occluded, the jailed wire permits identification of the ostium position.

The jailed wire cannot be used as such and must be replaced by a second wire after main branch stenting. The second wire can be the main branch wire in most cases. Wire exchange is facilitated by adequate shaping of the distal wire extremity; the wire initially inserted into the main branch must be shaped in order to permit access to the side branch through the most distal cell of the main branch stent, which will improve coverage of the side branch ostium. The jailed wire must then be removed from both the side branch and the main branch stent, and pushed into the distal segment of the main branch if possible with a distal loop to avoid strut crossing.

The risks of the jailed wire technique are associated with wire withdrawal. We have observed four distal ruptures of the jailed wire from several hundred cases. These ruptures always occurred with hydrophilic wires which must therefore be avoided as jailed wires though they are sometimes useful to access a side branch through stent struts. Another risk is the uncontrolled movement of the guiding catheter upon wire removal; this should be anticipated in order to avoid proximal coronary dissection. These risks can be minimised by avoiding large diameter deployment (0.9 to 1 ratio) of the main branch stent on a jailed wire.

Should we predilate?

Though direct stenting does not seem to be associated with lower restenosis rates, it reduces the risk of geographic miss, as well as procedural time and cost and x ray exposure. In cases of unstable coronary syndromes, direct stenting allows a reduction in the risk of distal coronary embolisation. Predilatation during treatment of coronary bifurcation lesions facilitates stent insertion. It also induces plaque shifting and permits correction of this phenomenon before stent implantation by means of the kissing inflation technique. Predilatation of the side branch alone may allow access through a distal strut during wire exchange (B technique). However, use of this technique does not always reduce the risk of side branch occlusion during main branch stenting. The major pitfall is the risk of dissection which may considerably complicate the rest of the procedure, especially in the side branch when type B treatment is used. In such a case, wire exchange requires crossing the struts of the main branch stent and the dissection site in order to reach the distal vessel, and stenting of the side branch cannot be avoided.

Matching technique to lesion

In "false" bifurcation lesions, the side branch should only be stented when a complication occurs (occlusive or non-occlusive dissection) or in cases of suboptimal result. Type B treatment (provisional T stenting) is therefore most often used except in cases when access to the side branch is very difficult because of severe angulations, or when the main branch is small or calcified. The use of type A treatment or modified type A treatment is not recommended because it

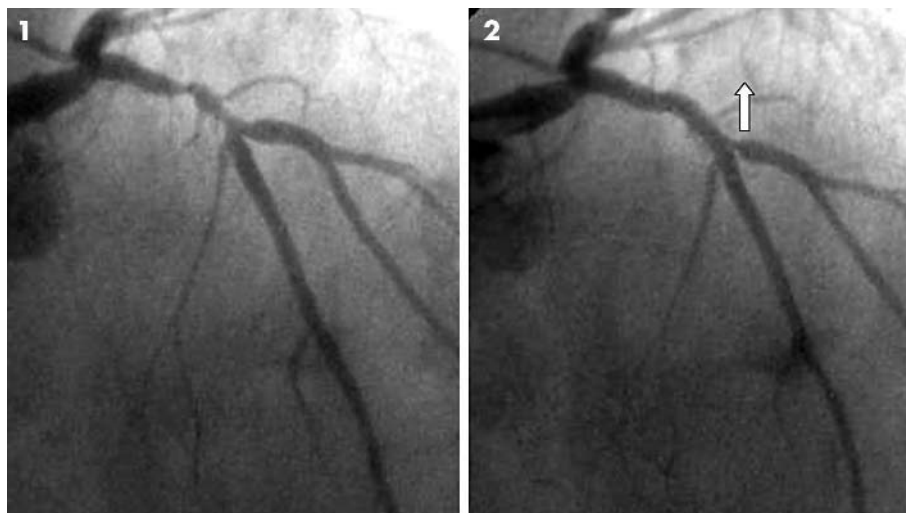


Figure 7 (1) Type 3 LAD/diagonal bifurcation lesion. (2) After stenting the LAD across the diagonal branch with a jailed wire in the diagonal artery; the diagonal artery ostium is pulled up by the stent and the jailed wire.

consists of stenting preventively the side branch which is free of significant disease at the beginning of the procedure. In type I lesions, the choice between type A or B treatment is more difficult. However, lesions in side branches are often very short (mean (SD) 3.6 (3.5) mm in length in our experience) and the provisional T stenting strategy seems very well adapted in the majority of cases. Type A treatment should be limited to cases when access to the side branch proves difficult, even after double wiring due to angulation, and when the side branch lesion is long or difficult to wire or stent because of calcifications or severe dissection following predilatation. The double wire technique increases angioplasty safety and permits step by step adaptation of the strategy according to the objective of the procedure. Selection between type A and B treatment can be made according to the angle between the two branches after wire insertion and according to the angiographic result after predilatation. If the objective is to preserve patency of a small branch, it is often not necessary to perform wire exchange and side branch dilatation after main branch stenting. Conversely, in the presence of a side branch at risk, the procedure should be completed by dilating and stenting the branch.

In true type 4 lesions, type D treatment with simultaneous deployment of two stents is fast and effective.

Stent selection

Non-specific tubular stents are used in most cases. Choice should be made on the basis of previous clinical experience and according to the branches' diameter and angulation. The ability to expand the main branch stent during kissing balloon inflation must be commensurate with the combined diameter of both branches. The maximal opening capacity of a strut must be equal to the side branch lumen area. These rules preclude the use of stents with irregular struts. Certain stents are more adapted to large proximal bifurcations such as the distal left main coronary artery (Penta by Guidant, R stent by Orbus, or Express by Boston scientific).

Final kissing balloon inflation

This technique is strongly recommended in order to optimise the angiographic results in both branches and correct angiographically invisible stent deformation. This final manoeuvre can be performed through a 6 French guiding catheter (especially the recently developed large lumen guiding catheters (0.068–0.071 inch) with various monorail balloon catheters (Viva or Maverick 2 by Boston Scientific, Maestro or Mercury by Jomed, Expleo by Biotronik, Stormer by Medtronic, or Arashi by Terumo). All other balloons are compatible with 7 French guides. However, balloon quality remains crucial for crossing stent struts. During side branch dilatation through a main branch stent strut, it is important to avoid complete strut crossing of the balloon before inflation, because balloon removal could prove impossible when the balloon has been inflated. Several other rules must be followed to perform kissing balloon inflation. Selection of balloon diameter must be made according to the distal diameter of each branch (ratio 1.1:1). Balloons used must be shorter than the stent in order to avoid inflation outside the stent. In unstented side branches, balloons should be very short in order to reduce geographic miss. Inflation pressure should be guided by the disappearance of the balloon waist and by the need for optimising the diameter of semi-compliant balloons.

WILL DRUG ELUTING STENTS MAKE ALL THESE TECHNIQUES OBSOLETE?

The few data currently available regarding treatment of bifurcation lesions with drug eluting stents involve the sirolimus coated stent. The purpose of the multicentre study conducted by Colombo was to study the ability of the Cypher stent to prevent restenosis after bifurcation lesion stenting, and to randomly compare stenting of the main branch vessel only (group 1) to systematic stenting of the two branches (group 2). Eighty six patients from five centres have been enrolled in this study.

Analysis of the results has been affected by several difficulties. Crossover from group 1 to group 2 was 51.2%. Patients in whom double stenting was performed were treated with several different techniques: type A or modified type A treatment and type B treatment. Angiographic follow up was incomplete (85.5% in the double stenting group and 94.4% in the single stenting group). Therefore, we have assessed these data according to a per protocol analysis. At six month follow up there was a non-significant trend towards higher late loss in the main branch and the side branch, as well as a trend towards a higher restenosis rate in the side branch in the double stenting group (28% *v* 19%). Only one instance of restenosis was reported in the main branch stent (double stenting group). The conclusions of this study were that the sirolimus coated stent reduces the restenosis and reintervention rates after bifurcation lesion treatment, that there is no clear advantage in systematically stenting the side branch, and that stenting the side branch first may lead to a higher restenosis rate of the side branch.

ARE 'DEDICATED' STENTS THE ANSWER?

Several types of dedicated stents have been designed since the mid 1990s: large strut stents, bevelled stents for optimal ostium coverage in the side branch, bifurcated stents, and also several stent delivery systems providing permanent access to the side branch or allowing reliable stenting of the side branch ostium with the main branch stent.

These stents will not be used in routine practice unless they can prove as efficient as the already validated tubular stents in terms of angiographic success rate, positioning, procedure duration and x ray exposure, rate of acute complications, and mid term MACE and TVR rates. The concept of these stents can be a problem in itself given the inherent multiplicity of stent diameters and lengths.

The case reports or short series involving large strut stents have failed to show their benefit in routine practice (NIR-Side, Jomed, AST SLK-view).^{19 20 w74–78} Some of these stents are combined with delivery systems providing permanent access to the side branch, which may potentially increase the success rate and reduce procedural duration and x ray exposure. A number of bifurcated stents have reached the clinical investigation stage,^{9 w26 w78 w79} and the use of two of them has been described in case reports (Bard XT Carina and AVE bifurcation stents).

The DBS stent (Cordis) has been the only device to undergo evaluation through a multicentre study of 34 patients conducted in France.^{w80} This stent was evaluated in 19 LAD/diagonal bifurcations, seven protected distal left main arteries, four circumflex/marginal bifurcations, and four distal right coronary arteries through 8 French guiding catheter following kissing predilatation. Procedural success was achieved in 94% of cases, and six month TLR was 19% with a 33% restenosis rate.

More recently several manufacturers (Guidant, AST, Invatec) have developed stents combined with delivery systems reproducing the concept of stenting the main branch and the side branch ostium with a single stent. Stent progression in the main branch is blocked by a wire positioned in the side branch through one of the stent struts. The main branch stent can then be deployed while preserving access to the side branch with a bifurcated balloon, a balloon with side holes, or a small sheath.

Balloon deployment in the side branch permits stent implantation in the ostium. These new devices are currently being assessed in several studies. The next step will undoubtedly be the use of dedicated drug eluting stents.

CONCLUSION

With or without sirolimus eluting stents, the complexity of bifurcation lesion treatment lies in the side branch. Side branch access is facilitated by the jailed wire technique. In false bifurcation lesions there is no rationale for using two stents systematically and the strategy of "provisional T stenting" seems to be the most simple and is validated. In true bifurcation lesions, because the side branch lesion is usually short, the same strategy can be applied in the majority of cases. Potential reasons for primary or secondary failure when stenting the side branch are: the presence of a gap between the two stents (more often observed with type A than with modified T, crush, or type B treatment); plaque shifting from the main branch when stenting over the ostium of the side branch stent (type A treatment); plaque shifting from the main branch when stenting in the proximal side branch stent through the first strut (modified T and crush techniques); crushing of the proximal segment of the side branch stent without or even after kissing balloon inflation which may result in malapposition and inefficiency of the drug eluting stent (modified T stenting, crush technique); and significant injury to the side branch ostium caused by an excessive balloon/artery ratio or by the ostium location within the main branch wall.^{w81}

Several techniques accurately applied in coronary bifurcation lesions with non-specific tubular stents, and especially the provisional T stenting strategy, currently permit the achievement of angiographic results similar to those obtained in standard lesions.

Stents enabling all operators to treat safely and quickly the side branch ostium simultaneously with the main branch, while preserving permanent access to the side branch during the procedure and for potential future interventions, including bifurcated stents in the setting of left main lesions, are currently being investigated. The use of these new devices, which are better adapted to the artery anatomy, will probably enhance the interaction between adequate mechanical scaffolding and accurate delivery and dosage of the new anti-restenosis drugs.

ACKNOWLEDGMENTS

The authors would like to thank Dr Hildick-Smith for reviewing the manuscript and Mrs Catherine Dupic for her assistance in the preparation of the manuscript.

.....

Authors' affiliations

Y Louvard, T Lefèvre, M-C Morice, Institut Cardiovasculaire Paris Sud, Massy, France

REFERENCES

- 1 **Carrie D**, Karouny E, Chouairi S, *et al*. "T"-shaped stent placement: a technique for the treatment of dissected bifurcation lesions. *Cathet Cardiovasc Diagn* 1996;**37**:311-3.
- 2 **Colombo A**, Stankovic G, Orlic D, *et al*. Modified "T" stenting technique with "crushing" for bifurcation lesions: immediate results and 30-day outcome. *Cathet Cardiovasc Interv* 2003;**60**:145-51.
- 3 **Khoja A**, Ozbek C, Bay W, *et al*. Trouser-like stenting: a new technique for bifurcation lesions. *Cathet Cardiovasc Diagn* 1997;**41**:192-6.
- 4 **Kobayashi Y**, Colombo A, Akiyama T, *et al*. Modified "T" stenting: a technique for kissing stents in bifurcational coronary lesion. *Cathet Cardiovasc Diagn* 1998;**43**:323-6.
- 5 **Lefevre T**, Louvard Y, Morice MC, *et al*. Stenting of bifurcation lesions: a rational approach. *J Interv Cardiol* 2001;**14**:573-85.
- 6 **Lefevre T**, Louvard Y, Morice MC, *et al*. Stenting of bifurcation lesions: classification, treatments, and results. *Catheter Cardiovasc Interv* 2000;**49**:274-83.
- ▶ **This article presents two new classifications of bifurcation lesions and treatments. In vitro tests on various techniques and stents are reported as well as the outcome of a series of 366 consecutive patients treated with different techniques. The article underlines the benefit of tubular stents and final kissing inflation.**
- 7 **Ormiston JA**, Webster MW, Ruygrok PN, *et al*. Stent deformation following simulated side-branch dilatation: a comparison of five stent designs. *Catheter Cardiovasc Interv* 1999;**47**:258-64.
- 8 **Yamashita T**, Nishida T, Adamian MG, *et al*. Bifurcation lesions: two stents versus one stent—immediate and follow-up results. *J Am Coll Cardiol* 2000;**35**:1145-51.
- ▶ **This non-randomised study compares the treatment of bifurcation lesions with a single stent in both branches versus a single stent in the main branch only. The authors conclude that stenting of both branches is not beneficial in terms of restenosis and reintervention reduction and is even associated with an increase in the acute complication rate in spite of a superior immediate angiographic outcome.**
- 9 **Servinka P**, Foley DP, Sabate M, *et al*. Coronary bifurcation stenting using dedicated bifurcation stents. *Catheter Cardiovasc Interv* 2000;**49**:105-11.
- 10 **Ahmed JM**, Mintz GS, Weissman NJ, *et al*. Mechanism of lumen enlargement during intracoronary stent implantation: an intravascular ultrasound study. *Circulation* 2000;**102**:7-10.
- ▶ **This article describes the axial plaque redistribution phenomenon observed with stenting, which had been previously reported in the setting of balloon angioplasty treatment. This article shows clearly why stenoses located next to a bifurcation become bifurcation lesions during the procedure and especially after stent placement.**
- 11 **Bhargava B**, Waksman R, Lansky AJ, *et al*. Clinical outcomes of compromised side branch [stent jail] after coronary stenting with the NIR stent. *Catheter Cardiovasc Interv* 2001;**54**:295-300.
- 12 **Pan M**, Suarez de Lezo J, Medina A, *et al*. Simple and complex stent strategies for bifurcated coronary arterial stenosis involving the side branch origin. *Am J Cardiol* 1999;**83**:1320-5.
- 13 **Al Suwaidi J**, Berger PB, Rihal CS, *et al*. Immediate and long-term outcome of intracoronary stent implantation for true bifurcation lesions. *J Am Coll Cardiol* 2000;**35**:929-36.
- ▶ **In a non-randomised study involving 131 patients, the outcome of main branch stenting is compared with stenting of both branches. One year follow up shows no superiority of the two stent group over the single stent group. However, the results of the two stent group shows a notable benefit of T stenting compared to "culotte" stenting. It is interesting to note that the event-free survival rate is similar between the two groups without "culotte".**
- 14 **Gobeil F**, Lefevre T, Guyon P, *et al*. Stenting of bifurcation lesions using the Bestent: a prospective dual-center study. *Catheter Cardiovasc Interv* 2002;**55**:427-33.
- ▶ **This is a two centre French series of bifurcation lesion treatment using the first generation Bestent with provisional T stenting technique in 88% and final kissing balloon inflation in 78%. Six month clinical follow up showed a 9.4% TVR rate and 14.6% MACE rate.**
- 15 **Carlier SG**, Colombo A, de Scheerder I, *et al*. Stenting of bifurcational coronary lesions: results of the multicentric European culottes registry. *Eur Heart J* 2001;**22**(abstract suppl):348.
- 16 **Pan M**, Suarez de Lezo J, Medina A, *et al*. Stepwise strategy for the stent treatment of bifurcated coronary lesions. *Catheter Cardiovasc Interv* 2002;**55**:50-7.
- 17 **Brueck M**, Scheinert D, Flachskampf FA, *et al*. Sequential vs. kissing balloon angioplasty for stenting of bifurcation coronary lesions. *Catheter Cardiovasc Interv* 2002;**55**:461-6.
- 18 **Karvouni E**, Di Mario C, Nishida T, *et al*. Directional atherectomy prior to stenting in bifurcation lesions: a matched comparison study with stenting alone. *Catheter Cardiovasc Interv* 2001;**53**:12-20.
- 19 **Lowe HC**, Kumar R, Roy PR. New balloon expandable stent for bifurcation lesions. *Cathet Cardiovasc Diagn* 1997;**42**:235-6.
- 20 **Toutouzas K**, Stankovic G, Takagi T, *et al*. A new dedicated stent and delivery system for the treatment of bifurcation lesions: preliminary experience *Catheter Cardiovasc Interv* 2003;**58**:34-42.

Web-only References

1. Zack PM, Ischinger T. Experience with a technique for coronary angioplasty of bifurcational lesions. *Cathet Cardiovasc Diagn* 1984;**10**:433–43.
2. Pinkerton CA, Slack JD, Van Tassel JW, *et al.* Angioplasty for dilatation of complex coronary artery bifurcation stenosis. *Am J Cardiol* 1985;**55**:1626–8.
3. George BS, Myler RK, Stertz SH, *et al.* Balloon angioplasty of bifurcation lesions: the kissing balloon technique. *Cathet Cardiovasc Diagn* 1986;**12**:124–38.
4. Colombo A, Gaglione A, Nakamura S, *et al.* “Kissing” stents for bifurcation coronary lesion. *Cathet Cardiovasc Diagn* 1993;**30**:327–30.
5. Nakamura S, Hall P, Maiello L, *et al.* Techniques for Palmaz-Schatz stent deployment in lesions with a large side branch. *Cathet Cardiovasc Diagn* 1995;**34**:353–61.
6. Laham RJ, Carrozza JP, Baim DS. Treatment of unprotected left main stenosis with Palmaz-Schatz stenting. *Cathet Cardiovasc Diagn* 1996;**37**:77–80.
7. Tierstein PS. Kissing Palmaz-Schatz stents for coronary bifurcation stenoses. *Cathet Cardiovasc Diagn* 1996;**37**:307–10.
8. Baim DS. Is bifurcation stenting the answer? *Cathet Cardiovasc Diagn* 1996;**37**:314–16.
9. Fort S, Lazzam C, Schwartz L. Coronary ‘Y’ stenting: a technique for angioplasty of bifurcation stenoses. *Can J Cardiol* 1996;**12**:678–82.
10. Schampaert E, Fort S, Adelman AG, *et al.* The V-stent: a novel technique for coronary bifurcation stenting. *Cathet Cardiovasc Diagn* 1996;**39**:320–6.
11. Carison TA, Guarneri EM, Stevens KM, *et al.* “T-stenting”: the answer to bifurcation lesions? *Circulation* 1996;**94**:I-86-I-87.
12. Koller, *et al.* *The New Manual of Interventional Cardiology*. Physicians Press, 1996:233–43.
13. Di Mario C, Colombo A. Trousers-stents. How to choose the right size and shape. *Cathet Cardiovasc Diagn* 1997;**41**:197–9.
14. Carrie D, Elbaz M, Dambrin G, *et al.* Coronary stenting of bifurcation lesions using “T” or “reverse Y” configuration with Wiktor stent. *Am J Cardiol* 1998;**82**:1418–21, A8.
15. Chevalier B, Glatt B, Royer T, *et al.* Placement of coronary stents in bifurcation lesions by the “culotte” technique. *Am J Cardiol* 1998 Oct 15;**82**:943–9.
16. Aroney N. A new technique to guarantee access to the sidebranch during bifurcational coronary stenting. *J Invas Cardiol* 2000;**12**:25–28.
17. Alberti A, Missiroli B, Nannini C. “Skirt” technique for coronary artery bifurcation stenting. *J Invasive Cardiol* 2000;**12**:633–6.
18. Perin MA, Martinez EE, Ambrose JA, *et al.* A new method for stenting bifurcation lesions with preservation of side branch access. *European Heart J* 2000;**21**(abst suppl):640.
19. Kobayashi Y, Colombo A, Adamian M, *et al.* The skirt technique: A stenting technique to treat a lesion immediately proximal to the bifurcation [pseudobifurcation]. *Catheter Cardiovasc Interv* 2000;**51**:347–51.
20. Reimers B, Colombo A, Tobis J. Bifurcation lesions in Techniques in Coronary Artery Stenting. *Martin Dunitz* 2000:171–204
21. Spedicato L, Bonin M, Bernardi G, *et al.* “Side balloon stenting”: a novel technique for bifurcation lesions. *J Invasive Cardiol* 2001;**13**:684–8.
22. Pomerantz RM, Ling FS. Distortion of Palmaz-Schatz stent geometry following side-branch balloon dilation through the stent in a rabbit model. *Cathet Cardiovasc Diagn* 1997;**40**:422–6.

23. Kinoshita T, Kobayashi Y, De Gregorio J, *et al.* Difference in security of stent jail between Palmaz-Schatz, NIR, and Multi-Link stents: the effect of balloon inflation through stent struts. *Catheter Cardiovasc Interv* 1999;**48**:230–4.
24. Stankovic G, Martini G, Ferraro M, *et al.* An In-Vitro Assessment of Stent Geometry for Bifurcation Lesions After Kissing Balloon Inflation. *Am J Cardiol* 2001;**88**(suppl 5A):60G.
25. Brunel P, Leurent B, Banus Y, *et al.* Stent Mesh Access and Deformation in the Treatment of Coronary Bifurcation Lesions: An In Vitro-In Vivo Study. *Am J Cardiol* 2002;**90**(suppl 6A):78H.
26. Carlier SG, van der Giessen WJ, Foley DP, *et al.* Stenting with a true bifurcated stent: acute and mid-term follow-up results. *Catheter Cardiovasc Interv* 1999;**47**:361–96.
27. Mintz GS, Pichard AD, Kent KM, *et al.* Axial plaque redistribution as a mechanism of percutaneous transluminal coronary angioplasty. *Am J Cardiol* 1996;**77**:427–30.
28. Fishman DL, Savage MP, Leon MB, *et al.* Fate of lesion related side branches after coronary artery stenting. *J Am Coll Cardiol* 1993;**22**:1641–6.
29. Iniguez A, Macaya C, Alfonso F, *et al.* Early angiographic changes of side branches arising from a Palmaz-Schatz stented coronary segment: results and clinical implications. *J Am Coll Cardiol* 1994;**23**:911–5.
30. Pan M, Medina A, Suarez de Lezo J, *et al.* Follow-up patency of side branches covered by intracoronary Palmaz-Schatz stent. *Am Heart J* 1995;**129**:436–40.
31. Ishiki R, Hara K, Ikari Y, *et al.* Patency of intermediate size side branches after Palmaz-Schatz stent implantation. *Jpn Heart J* 1997;**38**:191–7.
32. Hayashi S, Tohyama S, Shindo T, *et al.* Risk of side branch occlusion after coronary Palmaz-Schatz stenting. *J Cardiol* 1997;**29**:261–6.
33. Cho GY, Lee CW, Hong MK, *et al.* Effects of stent design on side branch occlusion after coronary stent placement. *Catheter Cardiovasc Interv* 2001;**52**:18–23.
34. Poerner TC, Kraleov S, Voelker W, *et al.* Natural history of small and medium-sized side branches after coronary stent implantation. *Am Heart J* 2002;**143**:627–35.
35. Ehara S, Shimada K, Kobayashi Y, *et al.* Short- and long-term outcomes of compromised side branches after Multi-Link stent implantation. *Heart Vessels* 2002;**16**:86–90.
36. Koning R, Huret B, Caussin C, *et al.* Coronary Stenting in Bifurcated Lesions: Clinical and Angiographic Results of a French Multicenter Study. *Am J Cardiol* 2002;**90**(suppl 6A):43H.
37. Koller P, Safian RD. *Bifurcation Stenosis in Manual of Interventional Cardiology*. Physician's Press, 1996:229–41.
38. Topol EJ. *Textbook of Interventional Cardiology*, 3rd edition. Philadelphia: W.B. Saunders, 1999.
39. Lefevre T, Louvard Y, Morice MC, *et al.* Stenting of Bifurcation Lesions: Seven-Month Follow-up of a Prospective Study. *Am J Cardiol* 1998;**84**(suppl 6A):14S.
40. Maillard L, Guerin Y, Drieu L, *et al.* A Multicenter Registry of Elective Y Reconstruction of Complex Bifurcation Lesions with Bard XT Stents. *Am J Cardiol* 1998;**84**(suppl 6A):50S.
41. Chevalier B, Guyon P, Glatt B, *et al.* LAD-Diagonal Bifurcation Lesion: A Comparison Between Complete Stenting Versus Main-Branch Single Stenting. *Am J Cardiol* 1998;**84**(suppl 6A):14S.
42. De Scheerder G, Dens J, Desmet W, *et al.* Treatment of Bifurcation Lesions Using a New Tubular Stent. *Am J Cardiol* 1998;**84**(suppl 6A):50S.
43. Bacquet D, Caussin C, Saldana A, *et al.* Bifurcation Lesions in Small Side Branch Vessel: Immediate Results and Six Month Follow-up of Two Different Strategies. *Am J Cardiol* 1999;**84**(suppl 6A):79P.
44. Sheiban I, Albiero R, Marsico F, *et al.* Immediate and long-term results of “T” stenting for bifurcation coronary lesions. *Am J Cardiol* 2000;**85**:1141–4, A9.

45. Lefèvre T, Guyon P, Brunel P, *et al.* Stenting of Bifurcation Lesions Using the BX Velocity Stent: A Multicenter French Study. *Am J Cardiol* 2001;**88**(suppl 5A):21G.
46. Anzuini A, Briguori C, Rosanio S, *et al.* Immediate and long-term clinical and angiographic results from Wiktor stent treatment for true bifurcation narrowings. *Am J Cardiol* 2001;**88**:1246–50.
47. Khan MM, Mahadevan VS, Moohan VP, *et al.* Use of Rtrade mark stent in the percutaneous coronary intervention of coronary bifurcation lesions. *Int J Cardiovasc Intervent* 2001;**4**:173–80.
48. Rux S, Rückert SE, Sonntag S, *et al.* International Registry on Bifurcation Stenting [BISCOR]: Concept and Preliminary Results. *Am J Cardiol* 2002;**90**(suppl 6A):42H.
49. Al Suwaidi J, Yeh W, Cohen HA, *et al.* Immediate and one-year outcome in patients with coronary bifurcation lesions in the modern era [NHLBI dynamic registry. *Am J Cardiol* 2001;**87**:1139–44.
50. Wilensky RL, Johnston J, Selzer F, *et al.* Percutaneous coronary intervention of complex lesions is still associated with increased in-hospital and 1-year adverse event rates. *European Heart Journal* 2002;**4**(Abstr. Suppl):389.
51. Nakamura S, Saito S, Miyauchi T, *et al.* Stenting of Coronary Bifurcation Lesions: Y-Stenting, T-Stenting, Single Stenting, Immediate and Long-Term Results: Multicenter Registry in Japan. *Am J Cardiol* 2002;**90**(suppl 6A):13H.
52. Lefevre T, Louvard Y, Morice MC, *et al.* Evaluation of different approaches to stenting true bifurcation lesions. *European Heart Journal* 2002;**4**(Abstr. Suppl):508.
53. Robinson NM, Balcon R, Layton CA, *et al.* Intravascular ultrasound assessment of culotte stent deployment for the treatment of stenoses at major coronary bifurcations. *Int J Cardiovasc Intervent* 2001;**4**:21–7.
54. Morocutti G, Vendrametto F, Spedicato L, *et al.* Bail-out rotational atherectomy to ablate stent struts after treatment of a LAD bifurcation lesion with the Trousers technique. *Catheter Cardiovasc Interv* 2000;**50**:346–8.
55. De Scheerder I, Dens J, Desmet W, *et al.* Treatment of Bifurcation Lesions Using a New Tubular Stent. *Am J Cardiol* 1998;**84**:50S.
56. Sheiban I, Marsico F, Pagnotta P, *et al.* Modified “T”-Stenting Technique for Kissing Stents in Bifurcational Coronary Lesions: Clinical Feasibility and Immediate Angiographic Results. *Am J Cardiol* 1998;**84**:50S.
57. Metzger PDC, Santos RM, Bulle TM. Prospective T-Stenting of Bifurcation Lesions Using a Novel Approach with Simultaneous Stent Positioning Results in High Procedural Success with Improved Clinical Outcomes. *Am J Cardiol* 2001;**88**:61G.
58. Lefevre T, Louvard Y, Morice MC, *et al.* Evaluation of a simple strategy for stenting bifurcation lesions. *European Heart Journal* 2001;**22**(Abstr. Suppl):347
59. Lefevre T, Louvard Y, Morice MC, *et al.* Treatment of “false bifurcation lesions” with coronary stenting. *European Heart Journal* 2002;**4**(Abstr. Suppl):387.
60. Lefevre T, Louvard Y, Morice MC, *et al.* Stenting of ‘True’ Bifurcation Lesions: Predictive Factors of Target Vessel Revascularization at Seven-Month Follow-up. *Am J Cardiol* 1999;**84**(suppl 6A):23P.
61. Kondo H, Hayase M, Kojima A, *et al.* Mechanism of Kissing-Balloon Dilatation After Stenting for Bifurcation Lesions: An Intravascular Ultrasound Study. *Am J Cardiol* 2001;**88**(suppl 5A):95G.
62. Gambhir DS, Singh S, Sinha SC, *et al.* Treatment of true bifurcation stenosis by elective stent implantation in parent vessel and non-stent dilatation of side branch: immediate and follow-up results. *Indian Heart J* 2000;**52**:289–96.

63. Chieffo A, Stankovic G, Briguori C, *et al.* Acute and Late Outcome After Directional Atherectomy plus Stenting Versus Stenting Alone in True Bifurcation Lesion. *Am J Cardiol* 2002;**90**(suppl 6A):44H.
64. Park SJ, Park SW, Lee CW, *et al.* Stenting for Unprotected Left Main Coronary Stenosis: Acute and Long-Term Results of the First 145 Cases. *Am J Cardiol* 2001;**88**(suppl 5A):6G.
65. Ehara M, Ito S, Ojio S, *et al.* Reliability of Percutaneous Coronary Intervention for Unprotected Left Main Coronary Lesions: Challenge to Obtain Satisfactory Outcomes. *Am J Cardiol* 2002;**90**(suppl 6A):41H.
66. Sharma SK, Kini A, Mitre CA, *et al.* Should follow-up angiography be routine in asymptomatic patients after stenting of unprotected left main coronary stenosis? *European Heart Journal* 2002;**4**(Abstr. Suppl):71.
67. Mulvihill N, Boccalatte M, Farah B, *et al.* Anatomical location of lesion predicts restenosis in unprotected left main coronary artery stenting. *European Heart Journal* 2002;**4**(Abstr. Suppl):309.
68. Park SJ, Lee CW, Kim YH, *et al.* Technical feasibility, safety, and clinical outcome of stenting of unprotected left main coronary artery bifurcation narrowing. *Am J Cardiol* 2002;**90**(4):374–8.
69. Sharma GL, Loubeyre C, Lefèvre T, *et al.* Direct Stenting for Bifurcation Lesions in Acute Myocardial Infarction: Preliminary Results of a Pilot Study. *Am J Cardiol* 2001;**88**(suppl 5A):67G.
70. Zhou Y, Kassab GS, Molloy S. On the design of the coronary arterial tree: a generalization of Murray's law. *Phys Med Biol* 1999;**44**:2929–45.
71. Mendiz OA, Valdiviesom LR, Telayna JM, *et al.* Hospital and Follow-up Evolution of Stent Angioplasty of Bifurcational Coronary Lesions: A Single-Center Experience. *Am J Cardiol* 2002;**90**(suppl 6A):44H.
72. Chevalier B, Lefevre T, Brunel P, *et al.* Influence of Side Branch Protection on the Results of Bifurcation Stenting: Insights from the BX Velocity Multicenter Registry. *Am J Cardiol* 2001;**88**(suppl 5A):21G 53.
73. Terkamp C, Gaede A, Werner PC, *et al.* Combining stenting with the double wire technique effectively prevents side branch occlusion. *Z Kardiol* 2002;**91**:899–904.
74. Hardas SP, Barron GJ, Meredith IT, *et al.* Bifurcation coronary angioplasty using a new side branch accessible stent. *Cathet Cardiovasc Diagn* 1998;**45**:92–5
75. Meerkin D, Almagor Y. Provisional bifurcation stenting. *Int J Cardiovasc Intervent* 2001;**4**:87–90.
76. Luna J, Condado JA, Davidson CJ, *et al.* Clinical Experience with a Novel Stent and Delivery System for Bifurcation Lesions. *Am J Cardiol* 2001;**88**(suppl 5A):63G.
77. Kim YH, Lee JH, Lee CW, *et al.* Initial Clinical Experience with the New AST SLK-View Stent for Bifurcation Coronary Lesions. *Am J Cardiol* 2002;**90**(suppl 6A):13H.
78. Sabate M, Lighthart J, Deshpande N, *et al.* 'Navius' kissing stents for coronary bifurcation stenosis, recreating a new metallic carina: an IVUS-assessed case report. *Int J Cardiovasc Intervent* 1998;**1**:109–12.
79. Colombo A, Airolidi F, Sheiban I, *et al.* Successful treatment of a bifurcation lesion with the Carina Bard stent: A case report. *Catheter Cardiovasc Interv* 1999;**48**:89–92.
80. Dibie A, Chevalier B, Fajadet J, *et al.* First "In Man" Study with a Coronary Stent Specifically Designed for True Bifurcated Lesions: The DBS Stent. *Am J Cardiol* 2002;**90**(suppl 6A):13H.
81. Guyon P, Teiger E, Chevalier B, *et al.* Rapamycin-Coated Stent Effectiveness in High Arterial Injury Damage: A Pig Model Experimentation. *Am J Cardiol* 2002;**90**(suppl 6A):73H, 179.