

Multidetector CT coronary angiography: have we found the holy grail of non-invasive coronary imaging?

P M Donnelly, J D S Higginson, P D Hanley

Heart 2005;91:1385–1388. doi: 10.1136/hrt.2004.058164

Is technology about to deliver on the long awaited goal of effective non-invasive methods for visualising and assessing coronary arteries?

The investigation and treatment of coronary disease continues to impose a significant burden on health service resources. Stress testing may help select patients who require coronary imaging, but invasive coronary angiography remains the gold standard for the investigation of suspected coronary disease. However, it can detect only advanced relatively stable atheroma causing obstruction of the coronary lumen. It is invasive, with a small associated morbidity and mortality, resource intensive, and inconvenient for patients. Some 40% of studies require no further intervention after exposing patients to the unnecessary procedure risks. Consequently there has been a search for alternative non-invasive methods of visualising and assessing coronary arteries, giving information about the total plaque burden and the presence or absence of significant coronary stenoses. Developments in cardiac computed tomography (CT) as a new diagnostic tool may allow us to achieve these highly desired goals.

TECHNICAL CONSIDERATIONS

Successful CT coronary artery imaging demands a high temporal and spatial resolution. The former is required to virtually freeze cardiac motion and the relative movement of the coronary arteries in the diastolic phase of the cardiac cycle. Assuming a heart rate of 60 beats/min the total diastolic period would not exceed 330 ms. A high spatial resolution is necessary because coronary arteries are small and tortuous, usually no more than 4 mm at origin and less than 1 mm distally. These prerequisites demand technology with a high specification which has only recently become available.

HISTORICAL BACKGROUND

Cardiac CT developments followed those in electron beam computed tomography (EBCT). EBCT uses a prospective gating method to image at one point only in the cardiac cycle. Its high temporal resolution and ECG synchronised gating made it feasible to image the beating heart.¹ However, the poor spatial resolution, high cost, and inaccessibility has limited its use to a few centres.

Following the introduction of multidetector computed tomography (MDCT) in 1998/99, early reports with four detector channels were encouraging.² Comparison of CT coronary angiography with conventional angiography demonstrated that sensitivities of 75–85% and specificities of 76–90% were achievable. However, as many as one third of all coronary artery segments were excluded from these analyses because of artefacts. These uninterpretable segments were mainly caused by the technical limitations of insufficient temporal and spatial resolution. Difficulty with prolonged breath hold and increased heart rates also contributed to non-diagnostic scans. One study demonstrated that increased heart rates could reduce the sensitivity for stenosis detection by as much as 50%.³ Administration of β blockers before CT coronary angiography is now routine, achieving reduction in heart rate, diastolic prolongation, and reduced heart rate variability.

16 MDCT

A new generation of scanner with 16 detector channels (16 MDCT) is now available with a 0.38–0.42 s gantry rotation time, and a detector width of 0.5–0.75 mm. This means improved temporal and spatial resolution, achieving near isotropic imaging and faster scan times. Improved reconstruction algorithms and reduced breath hold requirements also contribute to better coronary image quality.

Initial reports of the usefulness of 16 MDCT in the detection of coronary stenoses suggest sensitivities of 70–95% and specificities of 86–98% (excluding non-assessable segments).^{4–9} The number of patients included in these studies ranged from 33–128 and up to 16% of segments were excluded from analysis mostly because of “bloom” artefact from coronary calcium. This is similar to our own experience of 200 patients comparing MDCT with conventional angiography.

PROTOCOL FOR CONTRAST ENHANCED MDCT

A preliminary scan without contrast injection may be performed to determine the total calcium burden (calcium score) of the coronary tree. Some investigators⁶ suggest that Agatston calcium scores above 1000 in 16 MDCT scanning are an indication for not proceeding with a contrast

Abbreviations: CT, computed tomography; EBCT, electron beam computed tomography; MDCT, multidetector computed tomography; PET, positron emission tomography; SPECT, single photon emission computed tomography

See end of article for authors' affiliations

Correspondence to:
Dr J David S Higginson,
Cardiology Department,
Ulster Hospital, Belfast
BT16 1RH, UK; david.
higginson@ucht.n-i.nhs.uk

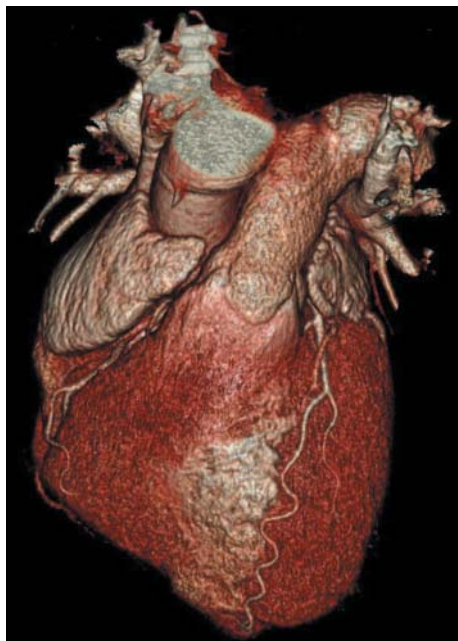


Figure 1 Three dimensional volume rendered reconstruction.

enhanced scan. However, in our institution useful imaging of coronary arteries not affected by calcium artefact may still be obtained in this subgroup. Using a table feed of 5.7–6.8 mm/s (determined by heart rate and the pitch of scan), tube current 400–500 mAs, and tube voltage of 120–140 kv (determined by patient size), non-ionic contrast media containing 300 mgI/ml is injected via an antecubital vein. The scan is triggered automatically when the concentration of contrast in the ascending aorta reaches 150 Hu. The entire heart volume from aortic root to diaphragm is scanned within a single breath hold (20 s). Total examination time (door to door) is 15 minutes.

IMAGE RECONSTRUCTION

Raw data reconstruction requires a further 15 minutes before coronary segmental analysis is performed. Contrast enhanced MDCT allows the acquisition of several hundred images from adjacent transaxial submillimetre overlapping slices. These are reconstructed using a retrospective ECG gating technique that facilitates data selection at a specific phase of least coronary motion within the cardiac cycle—for example, 80% of R–R interval. Image evaluation is performed at a dedicated workstation. Post-processing allows display of coronary images in various formats. “3D volume rendered images” of the heart are impressive (fig 1) and demonstrate the course of the coronary arteries, including anomalous coronary arteries and bypass grafts, but are of limited value in the detection of coronary stenoses. Evaluation of coronary stenoses is best from axial images (fig 2). “Multiplanar reconstructions” are made by navigation through a dataset of axial images for each coronary artery. Assessment of coronary arteries is based on two dimensional reconstructions of the vessel in at least two orthogonal planes (fig 3). “Curved multiplanar reconstructions” allow the tortuous course of a coronary artery to be displayed in a single image (fig 4). While multiplanar reconstructions are useful for short stenoses, longer coronary artery segments may be displayed in “maximum intensity projections” of greater thickness, but there is overlap from adjacent structures. Each coronary artery is analysed in a standard per segment model (American Heart Association coronary artery segments).

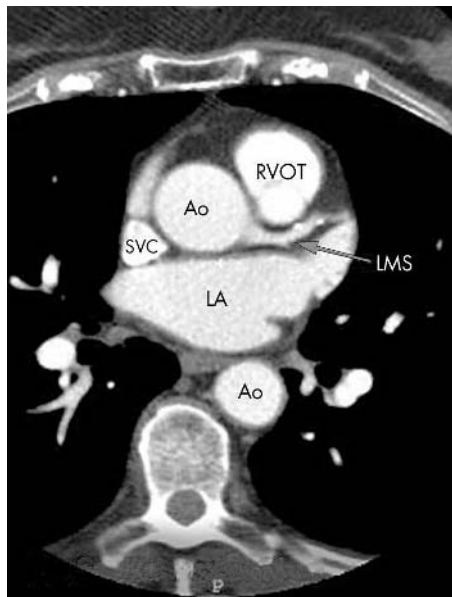


Figure 2 Transaxial slice.

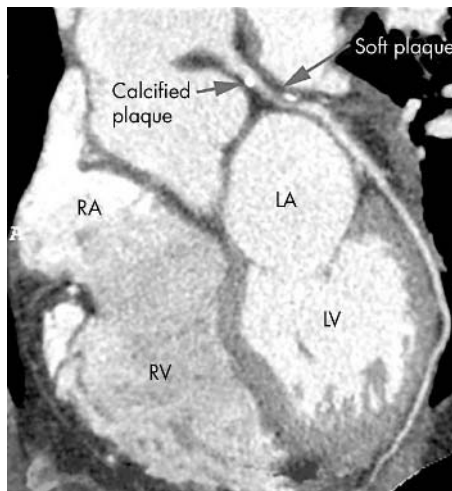


Figure 3 Multiplanar reconstruction of the left circumflex coronary artery. LA, left atrium, LV, left ventricle; RA, right atrium; RV, right ventricle.

CORONARY CALCIUM

Coronary calcium is a reliable marker of atherosclerotic plaque burden¹⁰ and an independent predictor of cardiovascular events. MDCT can readily produce a “calcium score”, but while calcium is helpful in defining risk, its high attenuation values prohibit accurate interpretation of the coronary artery lumen. This dilemma can only be resolved with further improvements in spatial resolution and is a significant barrier to acceptance of CT coronary angiography as the investigation of choice, except perhaps in low and intermediate risk groups.

One approach suggested to overcome this difficulty is to perform a non-enhanced sub-second coronary calcium score before CT coronary angiogram. Patients with a high calcium score—for example, > 1000—and therefore at greatest risk of significant underlying obstructive disease would not undergo a CT angiogram and instead be referred for standard catheter angiography.

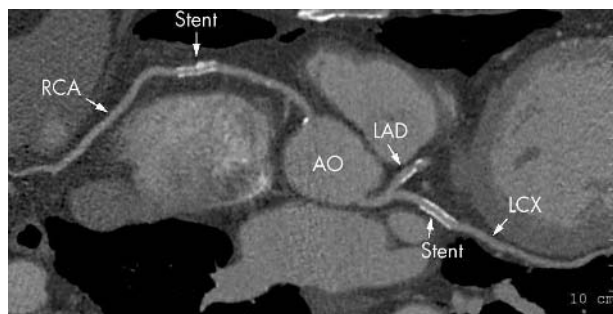


Figure 4 Curved multiplanar reconstruction. AO, aorta; LAD, left anterior descending coronary artery; LCX, left circumflex coronary artery; RCA, right coronary artery.

RADIATION EXPOSURE

Another significant limitation of cardiac CT is the radiation exposure. At present our own research group using 16 MDCT have found effective radiation dose to range from 6–13 mSv.¹¹ This is in excess of a conventional coronary angiogram (3–5 mSv with no left ventriculogram). It would be difficult to justify this double exposure in all patients, many of whom require subsequent coronary catheterisation. Manufacturers are currently assessing ways of reducing radiation exposure. One such method is tube dose modulation (ECG pulsing) using a high tube current and voltage only during the period of data acquisition.

FUTURE ROLE

MDCT will become increasingly available in district general hospitals as CT scanners are upgraded. This accessibility, the rapid scan times, and lack of patient hospitalisation make it an exciting prospect for diagnostic cardiology, especially when there is no “on site” catheter laboratory. It is establishing itself as a robust imaging modality that accurately identifies plaque burden, coronary artery anomalies,¹² coronary and pulmonary venous anatomy, and the patency of coronary artery bypass grafts¹³ (fig 5). The patency of coronary stents may be demonstrated in some patients (fig 4) without the artefact of 4 MDCT scanners but spatial resolution remains an issue.¹⁴ Early work in select patient groups assessing coronary artery stenoses, plaque morphology,¹⁵ and cardiac function¹⁶ is promising.

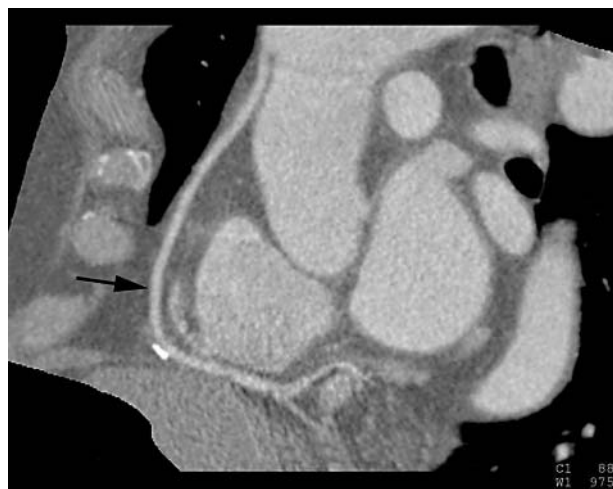


Figure 5 Multiplanar reconstruction of saphenous vein graft to right coronary artery.

Have we then found the “holy grail” of non-invasive coronary imaging?

The ability to visualise coronary arteries directly, assess cardiac function, and detect subclinical disease from a 20 second scan make MDCT more attractive than conventional stress testing. However, the significant radiation exposure makes it unattractive to screen the low risk population. Similarly, there is no justification for imaging high risk patients who clearly require coronary angiography and percutaneous intervention, without additional radiation exposure. It is unlikely that the financially constrained UK health system will adopt routine MDCT in the accident and emergency department to triage chest pain patients for “rule out” of pulmonary embolism, aortic dissection, and coronary disease.

The present niche of MDCT should be as an adjunct to coronary catheterisation in the assessment of patients and a useful gatekeeper ensuring appropriate triage of patients for catheterisation. This is especially true in the intermediate risk group and where there is atypical chest pain, inconclusive stress testing, or before urgent non-cardiac surgery.

This year has seen the introduction of 40 and 64 MDCT scanners with shorter scan times and improved temporal resolution that will further improve image quality. The development of hybrid CT/PET,¹⁷ CT/SPECT scanners, and flat panel technology providing morphological and metabolic/functional information in a single scan will secure a central role for cardiac CT in routine clinical practice. The elusive “holy grail” may at last be within grasp.

Authors' affiliations

P M Donnelly, J D S Higginson, Cardiology Department, Ulster Hospital, Belfast, UK

P D Hanley, Radiology Department, Ulster Hospital

REFERENCES

- Achenbach S, Moshage W, Ropers D, *et al.* Value of EBCT for the non-invasive detection of high grade coronary artery stenoses and occlusions. *N Engl J Med* 1998;**339**:1964–71.
- Achenbach S, Giesler T, Ropers D, *et al.* Detection of coronary artery stenoses by contrast-enhanced retrospectively electrocardiographically-gated, multislice spiral computed tomography. *Circulation* 2001;**103**:2535–8.
- Nieman K, Rensing BJ, van Geuns RJ, *et al.* Non-invasive coronary angiography with multislice spiral computed tomography: impact of heart rate. *Heart* 2002;**88**:470–4.
- Nieman K, Cademartiri F, Lemos PA, *et al.* Reliable non-invasive coronary angiography with fast sub millimetre multislice spiral CT. *Circulation* 2002;**106**:2051–4.
- Ropers D, Baum U, Pohle K, *et al.* Detection of coronary artery stenoses with thin-slice multi-detector row spiral computed tomography and multiplanar reconstruction. *Circulation* 2003;**107**:664–6.
- Kuettner A, Trabold T, Schroeder S, *et al.* Non-invasive detection of coronary lesions using 16-detector multislice spiral computed tomography technology. *J Am Coll Cardiol* 2004;**44**:1230–7.
- Martuscelli E, Romagnoli A, D'Eliseo A, *et al.* Accuracy of thin-slice computed tomography in the detection of coronary stenoses. *Eur Heart J* 2004;**25**:1043–8.
- Hoffman U, Moselewski F, Cury R, *et al.* Predictive value of 16-slice multidetector spiral computed tomography to detect significant obstructive coronary artery disease in patients at high risk of coronary artery disease. *Circulation* 2004;**110**:2638–43.
- Mollet NR, Cademartiri F, Nieman K, *et al.* Multislice spiral computed tomography in patients with stable angina pectoris. *J Am Coll Cardiol* 2004;**43**:2265–70.
- Sangiorgi G, Rumberger JA, Severson A, *et al.* Arterial calcification and not luminal stenosis is highly correlated with atherosclerotic plaque burden in humans. *J Am Coll Cardiol* 1998;**31**:619–23.
- Donnelly PM, Higginson JDS, Hanley P, *et al.* Radiation dose in 16 multi-slice CT imaging of the coronary arteries. *Irish J Med Sci* 2004;**173**:49–50.
- Ropers D, Moshage W, Daniel WG, *et al.* Visualisation of coronary artery anomalies and their anatomic course by contrast enhanced electron beam tomography and three dimensional reconstruction. *Am J Cardiol* 2001;**87**:193–7.
- Schlösser T, Konorza T, Hunold P, *et al.* Non-Invasive visualisation of coronary artery bypass grafts using 16-detector row computed tomography. *J Am Coll Cardiol* 2004;**44**:1224–9.

- 14 **Nieman K**, Cademartiri F, Raaijmakers R, *et al.* Non-invasive angiographic evaluation of coronary stents with multi-slice spiral computed tomography. *Herz* 2003;**28**:136–42.
- 15 **Leber A**, Knez A, Becker A, *et al.* Accuracy of multi-detector spiral computed tomography in identifying and differentiating the composition of coronary atherosclerotic plaques. A comparative study with intracoronary ultrasound. *J Am Coll Cardiol* 2004;**43**:1241–7.
- 16 **Juergens KU**, Grude M, Maintz D, *et al.* Multi-detector row CT of left ventricular function with dedicated analysis software versus MR imaging: initial experience. *Radiology* 2004;**230**:403–10.
- 17 **Namdar M**, Kaufmann P, Hany T, *et al.* Combined CT angiogram and PET perfusion imaging for assessment of CAD in a novel PET/CT: a pilot feasibility study. *European Radiology* 2003;**13**:165.

IMAGES IN CARDIOLOGY.....

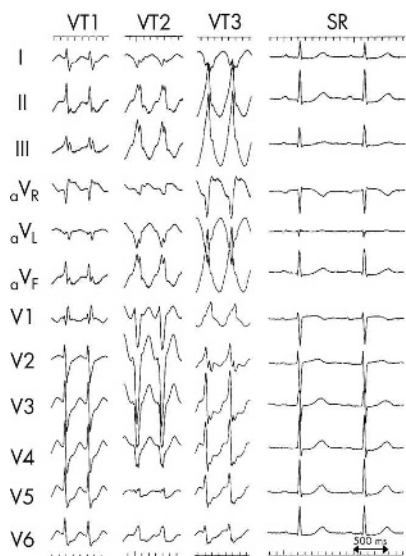
doi: 10.1136/hrt.2005.064089

Biventricular involvement in cardiac sarcoidosis

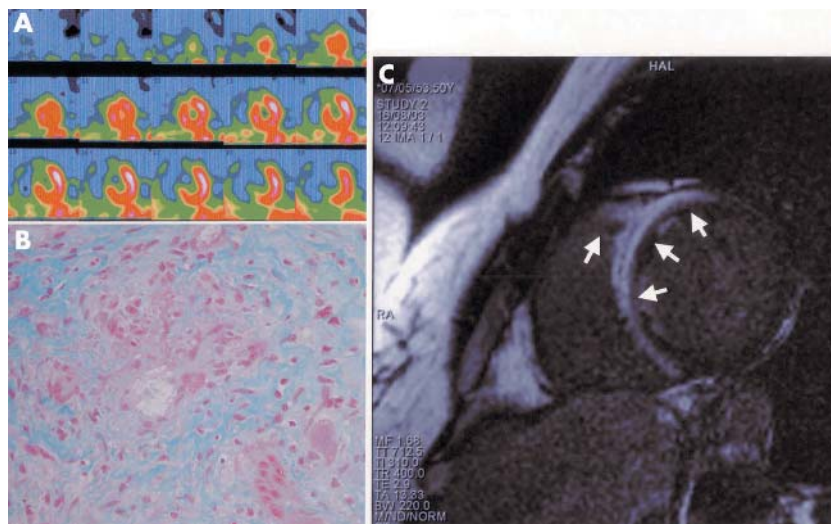
A 50 year old woman was admitted to our department to undergo an assessment of recurrent wide QRS tachycardia. An electrophysiologic study was performed. Ventricular tachycardia (VT) of three different morphologies, with left and right bundle branch block configurations, were induced with double extrastimuli from the right ventricle (left panel), thus suggesting that arrhythmogenic substrates existed in both the right and left ventricles. Endocardial mapping study showed that the site of earliest activation was found around the lower right ventricular outflow tract in VT 2. A thallium-scintigram showed a low uptake of agent from the anterior wall to the basal septum wall (panel A). Gadolinium enhanced magnetic resonance imaging (MRI) (T1) showed myocardial hyperenhancement in not only the left ventricular anteroseptum but also in the right ventricle (panel C). Non-caseating epithelioid granuloma with multinuclear giant cells and intracytoplasmic inclusions were detected in a right ventricular endomyocardial biopsy (panel

B). We diagnosed cardiac sarcoidosis and administered prednisolone acetate and amiodarone. Recent reports have demonstrated cardiac sarcoidosis to affect not only the left ventricle but also the right ventricle. Although thallium-201 myocardial scintigrams have been proposed as a non-invasive diagnostic tool for detecting cardiac sarcoidosis, detecting abnormalities in the right ventricle using thallium-201 scintigraphy tends to be difficult. In the present patient, gadolinium enhanced MRI showed myocardial hyperenhancement in the culprit lesion of the VT in the right ventricle, as demonstrated by the electrophysiological study, thus suggesting that gadolinium enhanced MRI is a useful tool for detecting cardiac sarcoidosis involving both left and right ventricular infiltration.

Y Nakada
T Date
S Mochizuki
 datet@jikei.ac.jp



ECG at baseline (SR) and during the tachycardia (VT 1–3), revealing a first degree atrioventricular (AV) block with sinus rhythm and ventricular tachycardias of three different morphologies with left and right bundle branch block configurations, respectively. VT, ventricular tachycardia; SR, sinus rhythm.



Panel A: rest myocardial thallium-201 scan (short axis) showing a clear anteroseptal defect. Panel B: biopsy specimen of endocardial tissue revealing many non-caseating granulomas with asteroid giant cells. Panel C: magnetic resonance imaging examination with a short axis view (gadolinium-DTPA delayed enhanced T1 weighted image) showing myocardial hyperenhancement in the anteroseptal wall of the left ventricle and part of the right ventricle wall.