

IMAGES IN CARDIOLOGY

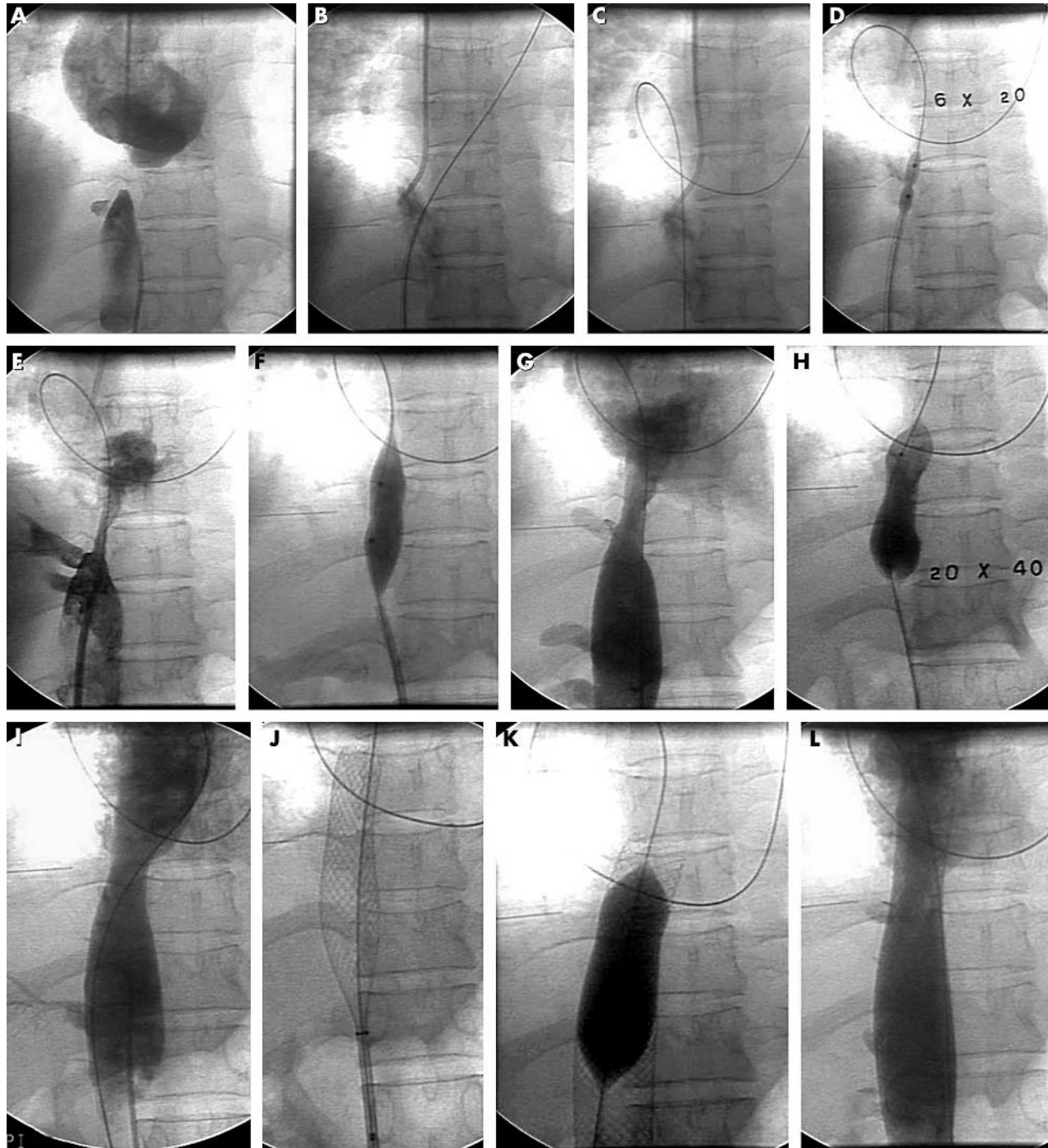
Heart 2005;91:e38 (<http://www.heartjnl.com/cgi/content/full/91/5/e38>). doi: 10.1136/hrt.2004.046094

Novel use of Brocken brough needle in relieving membranous obstruction of the inferior vena cava

A 35 year old female patient presented with secondary amenorrhoea, chronic abdominal pain, intermittent oedema in the feet, prominent veins in the chest and abdomen to the medical OPD. The patient's USG Doppler of lower limbs and abdomen revealed inferior vena cava (IVC) obstruction at the suprahepatic level—the patient did not have ascites. The patient was referred to the department of cardiology for an IVC gram, which revealed membranous obstruction of IVC at the hepatic veins (panel A).

Balloon dilatation of the IVC was performed. The femoral vein and right jugular vein were cannulated, and the membrane was punctured using an 18 G Brockenbrough septal puncture needle within 8 F Mullins dilator in anteroposterior view (AP) (panel B).

A 0.025 inch wire was placed in the right atrium via this needle. A multipurpose catheter was pushed over this wire. The wire was later replaced by a regular 0.038×260 cm wire (panel C), which was positioned in the PA. Graduated



inflations were given across the membrane using 4×20, 6×20, 14×20, and 20×40 mm balloons (panels D to I), and 24×70 mm Wallstent was deployed across the membrane (panel J). This stent was post dilated using a 20×40 mm balloon (panel K). An excellent result was obtained (panel L) and the patient's prominent veins over the body disappeared within 2 days. During follow up the patient had no

abdominal pain and surprisingly she had started menstruating regularly following conception.

N O Bansal
S S Deshpande
drshantanud@yahoo.com