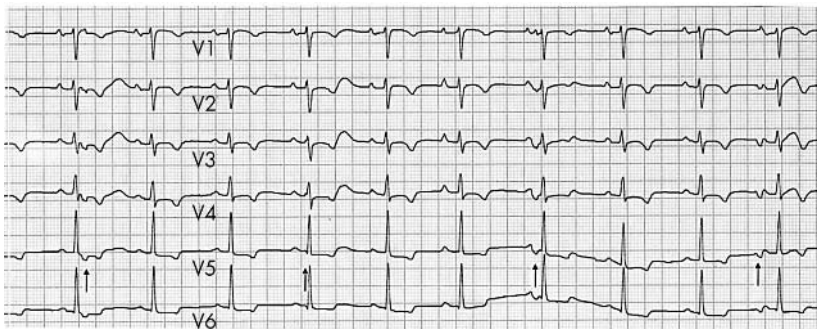


IMAGES IN CARDIOLOGY.....

Heart 2005;91:e39 (<http://www.heartjnl.com/cgi/content/full/91/5/e39>). doi: 10.1136/hrt.2004.053199

Electrocardiographic and echocardiographic features of a disconnected right ventricle

A 35 year old man with arrhythmogenic right ventricular dysplasia received an implantable cardioverter-defibrillator (ICD) for ventricular fibrillation (VF). In the next 2 years he experienced several "storms" of VF requiring numerous shocks, despite β blockade and amiodarone. As VF was precipitated by ventricular ectopy, radio-frequency ablation was considered but unfortunately not performed as monitoring revealed long periods of arrhythmia quiescence, even with cessation of anti-arrhythmic therapy and drug provocation. Surgical right ventricular disconnection was therefore performed, electrically isolating the right ventricle and thus preventing the arrhythmogenic focus from stimulating the rest of the myocardium. The patient recovered well from the operation and prior to discharge received a cardiac re-synchronisation ICD, with the defibrillation lead positioned in the right ventricular outflow tract, a second pacing lead in the disconnected segment of the right ventricular free wall as well as an atrial lead. The leads were connected to a Medtronic Insync III Marquis 7279 generator, with the device programmed with a short atrioventricular delay, and the right ventricular free wall to be triggered to pace in response to sensed signal from the right ventricular outflow tract. A rhythm strip ECG with ICD pacing temporarily programmed off, 6 months after the disconnection procedure (see panel), shows sinus rhythm,



(A) ECG with arrows showing right ventricular depolarisation at a rate of 21/min, the pacing system has been switched off. The supplemental material on the *Heart* website shows: (B) the echocardiogram showing sporadic contraction of an otherwise akinetic disconnected right ventricular free wall due to an isolated right ventricular escape rhythm generated when the pacing system is switched off; and (C) synchronous right and left ventricular contraction with the pacing system switched on.

normal atrioventricular conduction, and QRS complexes with additional dissociated QRS complexes of different morphology, generated as an escape rhythm from the disconnected right ventricular free wall. An echocardiographic recording (supplemental material available on the *Heart* website: <http://www.heartjnl.com/supplemental>) taken at the same time, demonstrates an akinetic right ventricular free wall, which occasionally contracts in association with the sporadic QRS complexes. The supplemental material shows the free wall contracting synchronously with left ventricular contraction (as demonstrated by aortic valve opening and closing), when the



To view supplemental material visit the *Heart* website—<http://www.heartjnl.com/supplemental>

J T Affolter
P Broadhurst
J P Bourke

paul.broadhurst@arh.grampian.scot.nhs.uk